



**PATIENT PRESENTING CLINICAL SIGNS**

Izzy Tollestrup

**SPECIES**

Canine

**BREED**

Westie

**SEX**

Female Spayed

Izzy presents for an internal medicine consult regarding worsening breathing difficulties and radiographic changes in her lungs. Izzy is doing well at home and is eating, drinking, and going to the bathroom normally. She is not experiencing any coughing, sneezing, vomiting, or diarrhea. Her people have stopped walking her or allowing excessive exercise since this began in November. At home, her respiration rate has been measured at up to 50 breaths per minute while sleeping. She also has Addison's disease, but this has been well controlled since diagnosis 9 years ago. Courses of baytril, furosemide, and theophylline and higher dose of prednisone (5mg at a dose) have been tried. No improvement has been seen with any of these treatments. She was dewormed as well with no improvement. End of Nov/Dec 22, she was noted to be breathing faster when at the vet's office but not when at home. This is progressed over time, so that she has been breathing faster and harder at rest. She also has been showing more and more significant exercise intolerance. She is currently taking: Percorten injections once every 4 weeks (last done 2 weeks ago) Prednisone 1mg once daily in the evening Travel history - OR, WA (camping). Other medical history - surgery to remove an acorn from the GIT and the Addison's disease. Abnormal PE/Chem/CBC/UA Results: moderate dyspnea, tachypnea, exercise intolerance, audible crackles bilaterally. labwork ok biggest concern is for pulmonary fibrosis

**AGE**

10 Years

**COMPUTED TOMOGRAPHIC STUDY OF THE THORAX**

A pre- and post- contrast CT study of the thorax are provided for review. Two series, pulmonary window, one pre and one post-contrast.

**COMPUTED TOMOGRAPHIC FINDINGS**

A severe diffuse interstitial to alveolar pattern with ground glass appearance is seen. In addition, multifocal subpleural and parenchymal bands are noted as well as a few nodules with ground glass appearance.

The main pulmonary bronchi are thinly mineralized and cylindrical in shape. The primary and secondary bronchi fail to taper at the lung lobes periphery.

**INTERPRETED BY**

Tilde Rodrigues Froes, DMV, MSc., Dr. Med Vet., Dipl. CBraRVet

**HOSPITAL NAME**

Southern Oregon Veterinary Specialty Center

The lung lobes are reduced in volume expansion.

The cardiac silhouette and pulmonary vasculature are normal.

The sternal, mediastinal, and cranial mediastinal lymph nodes are unremarkable.

The tracheobronchial lymph nodes are normal.

**REFERRING VET**

Kim Winters

The pleural space and diaphragm are normal.

The collimated abdomen is normal.

The thoracic musculoskeletal structures are unremarkable.

**INVOICE**

57031

No other abnormalities are identified.

**COMPUTED TOMOGRAPHIC DIAGNOSIS**

- Severe chronic interstitial to alveolar pulmonary disease and subpleural thickening, indicates nonspecific mixed inflammation, main differential diagnosis includes Pulmonary Fibrosis.

**DATE**

3-1-23



**PATIENT** • Concurrent bronchiectasis.

Izzy Tollestrup

**INTERPRETATION OF THE FINDINGS & FURTHER RECOMMENDATIONS**

**SPECIES**

Canine

The tomographic exam shows severe chronic pulmonary disease. The main differential diagnosis is correlated to West Highland White Terrier Pulmonary Fibrosis. Other less likely differential diagnosis includes pulmonary lymphoma and other infiltrative pulmonary metastatic disease (unknown origin).

**BREED**

Westie

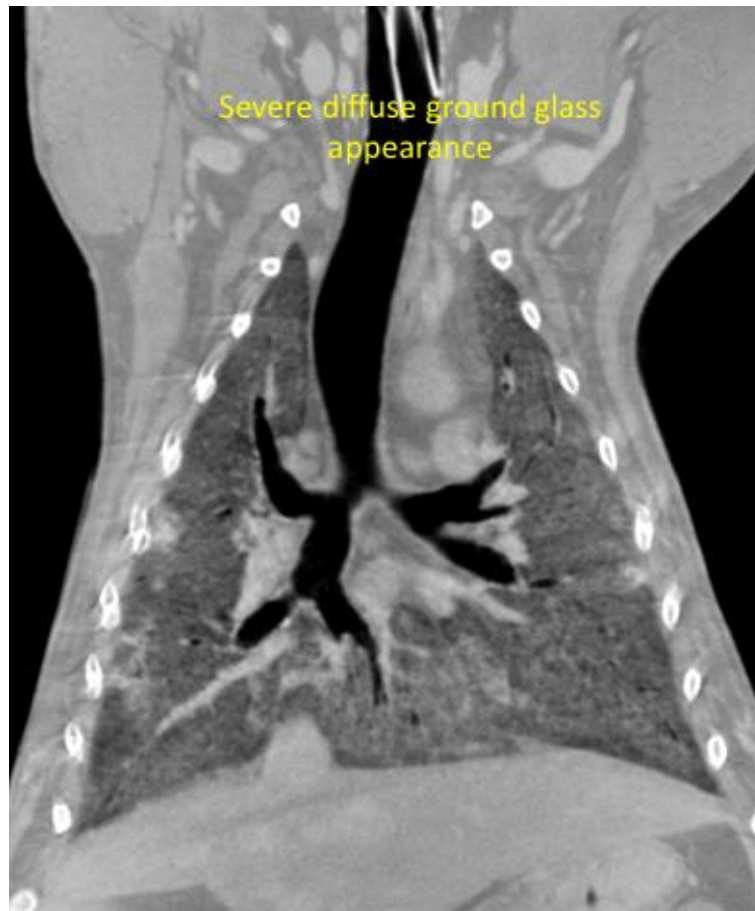The pulmonary fibrosis explains the clinical signs of the patient. Continuing treatment focus in managing the symptoms and improve quality of life is suggested.

**SEX**

Female Spayed

**AGE**

10 Years



**INTERPRETED BY**

Tilde Rodrigues Froes,  
DMV, MSc., Dr. Med  
Vet., Dipl. CBraRVet

**HOSPITAL NAME**

Southern Oregon  
Veterinary Specialty  
Center

**REFERRING VET**

Kim Winters

**INVOICE**

57031

**DATE**

3-1-23



**PATIENT**

Izzy Tollestrup

**SPECIES**

Canine

**BREED**

Westie

**SEX**

Female Spayed

**AGE**

10 Years

**INTERPRETED BY**

Tilde Rodrigues Froes,  
DMV, MSc., Dr. Med  
Vet., Dipl. CBraRVet

**HOSPITAL NAME**

Southern Oregon  
Veterinary Specialty  
Center

**REFERRING VET**

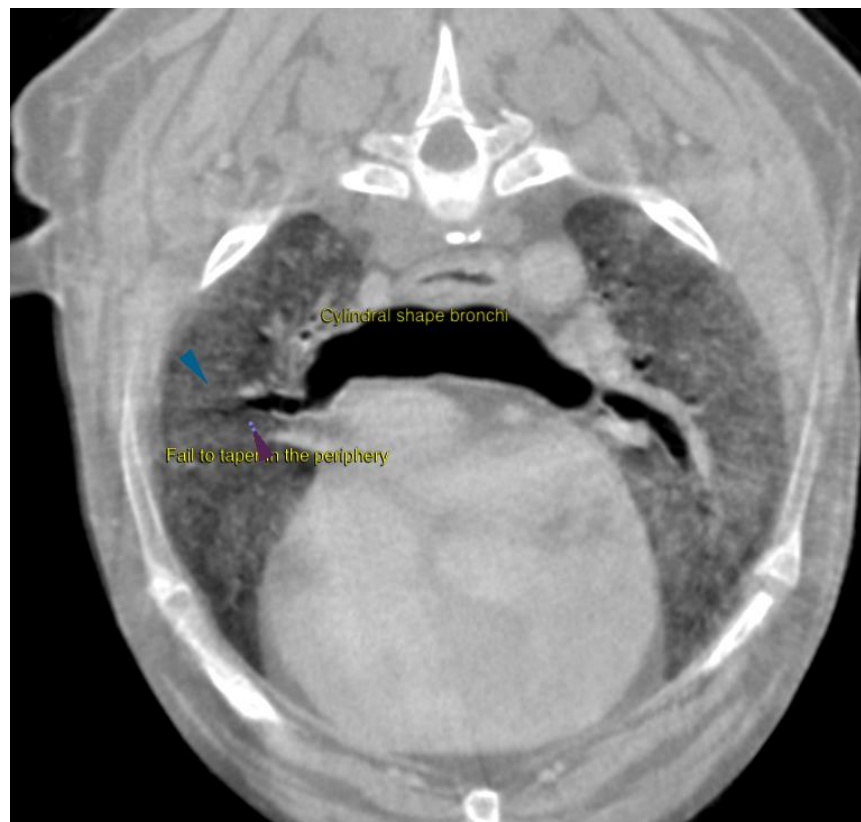
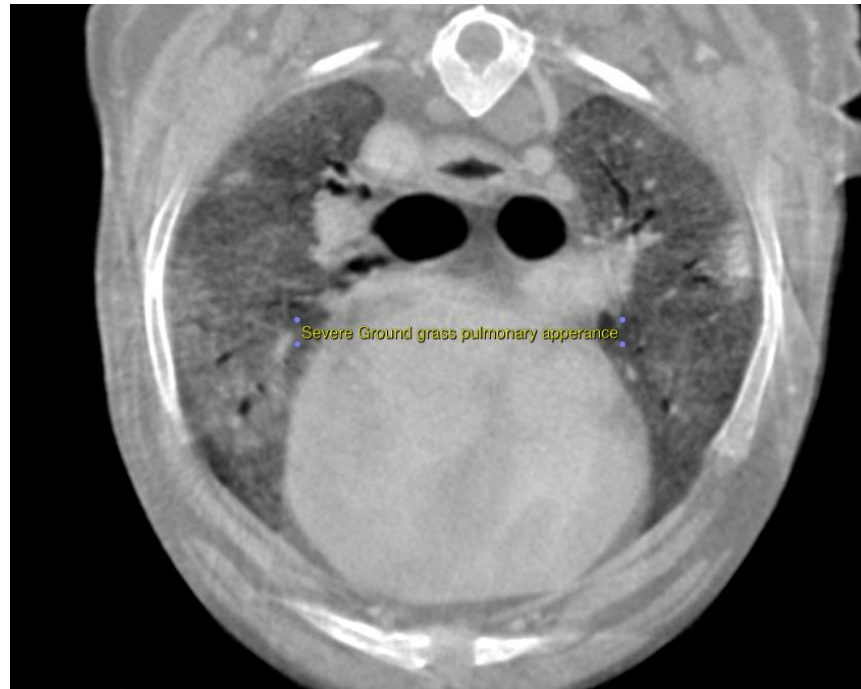Kim Winters

**INVOICE**

57031

**DATE**

3-1-23





**PATIENT**

Izzy Tollestrup

**SPECIES**

Canine

**BREED**

Westie

**SEX**

Female Spayed

**AGE**

10 Years

**INTERPRETED BY**

Tilde Rodrigues Froes,  
DMV, MSc., Dr. Med  
Vet., Dipl. CBraRVet

**HOSPITAL NAME**

Southern Oregon  
Veterinary Specialty  
Center

**REFERRING VET**

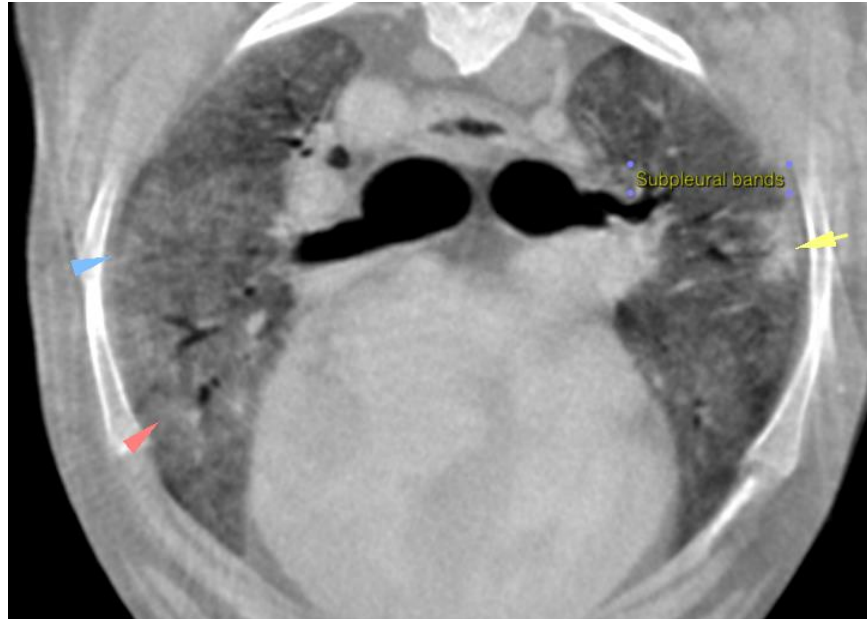
Kim Winters

**INVOICE**

57031

**DATE**

3-1-23



The information and recommendations provided are based on the images presented by the referring veterinarian. No evaluation can be communicated regarding pathology that was not visible in the image/video clips provided.

Thank you for this referral. If the clinical or image interpretation does not parallel your findings or if I can be of any further assistance please contact me.

**Tilde Rodrigues Froes**, DMV, MSc., Dr. Med.Vet., Dipl.CBraRVet  
info@sonopath.com