



PATIENT

Macey Spence

PRESENTING CLINICAL SIGNS

*diffuse peribronchial cuffing bilat lung fields *Chronic cough of 1yr duration. *Has been treated with Cough Tabs, Temaril-P, and Prednisone with no significant effect *Cough not worsening over time *Coughs both with excitement and when calm, but not when exercising

SPECIES

Canine

RADIOGRAPHIC STUDY OF THORAX

Orthogonal views of the thorax are provided for review totaling 2 images as well as 2 images for comparison of previous exam dated 8/16/2022.

BREED

Collie Mix

RADIOGRAPHIC FINDINGS

The cervical and thoracic trachea are normal.

Similar to previous exam, a mild diffuse bronchial pattern is seen.

SEX

FS

The cardiac silhouette and pulmonary vasculature are normal.

The mediastinum and pleural space are normal.

AGE

8 Years, 8 Months

The diaphragm and collimated abdomen are normal.

The skeletal structures are unremarkable.

No other abnormalities are identified.

INTERPRETED BY

RADIOGRAPHIC DIAGNOSIS

Tilde Rodrigues Froes, DMV, MSc., Dr. Med Vet., Dipl. CBraRVet

- Similar to previous exam, mild diffuse bronchial lung pattern. Differential diagnosis includes lower airway disease such as allergic versus infectious bronchitis (e.g., bacterial, viral, less likely parasitic).
- Otherwise, normal thorax.

HOSPITAL NAME

Reid Veterinary Hospital

INTERPRETATION OF THE FINDINGS & FURTHER RECOMMENDATIONS

The patient's reported cough is suspected to be secondary to mild chronic lower airway disease, as reported and on treatment. No evidence of bronchopneumonia or a pulmonary mass were noted.

REFERRING VET

Dr. Diane Heider

The suggestive further steps are continuing conservative and medical therapy for bronchitis. If patient does not improve, consider bronchoalveolar lavage for obtaining samples for cytology, culture, and sensitivity. Usually the radiographic findings of the lung lag behind the clinical course of acute respiratory diseases, consider this factor.

INVOICE

56620

DATE

2-7-23



PATIENT

Macey Spence

SPECIES

Canine

BREED

Collie Mix

SEX

FS

AGE

8 Years, 8 Months

INTERPRETED BY

Tilde Rodrigues Froes,
DMV, MSc., Dr. Med
Vet., Dipl. CBraRVet

HOSPITAL NAME

Reid Veterinary
Hospital

REFERRING VET

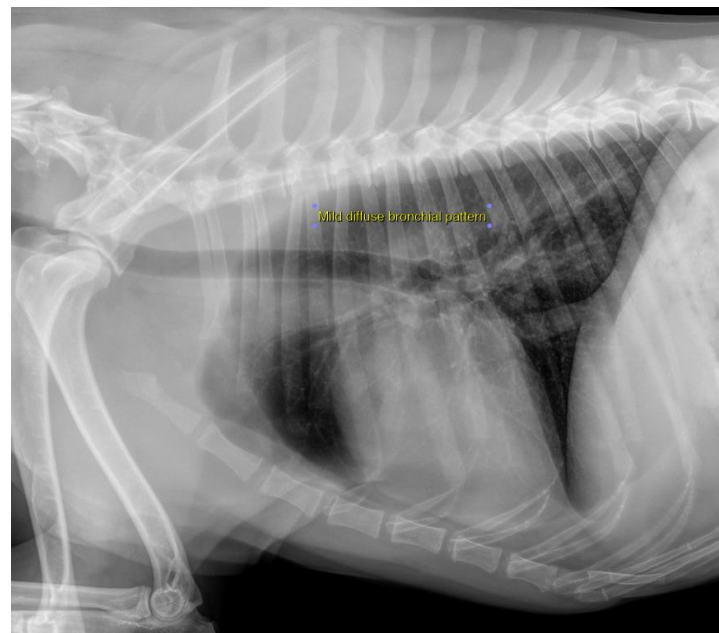
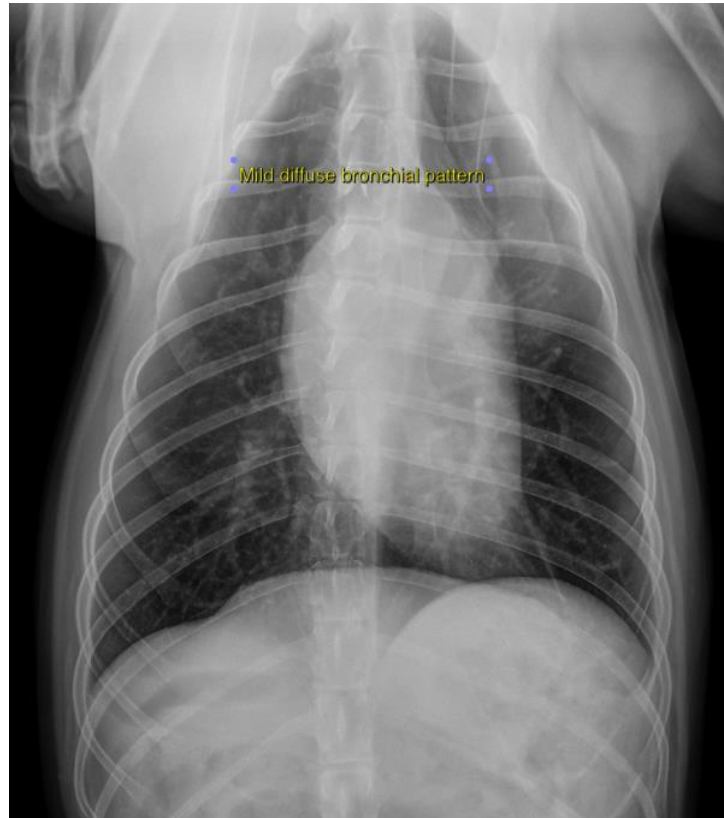Dr. Diane Heider

INVOICE

56620

DATE

2-7-23





PATIENT

Macey Spence

The information and recommendations provided are based on the images presented by the referring veterinarian. No evaluation can be communicated regarding pathology that was not visible in the image/video clips provided.

SPECIES

Canine

Thank you for this referral. If the clinical or image interpretation does not parallel your findings or if I can be of any further assistance please contact me.

BREED

Collie Mix

Tilde Rodrigues Froes, DMV, MSc., Dr. Med.Vet., Dipl.CBraRVet
info@sonopath.com

SEX

FS

AGE

8 Years, 8 Months

INTERPRETED BY

Tilde Rodrigues Froes,
DMV, MSc., Dr. Med
Vet., Dipl. CBraRVet

HOSPITAL NAME

Reid Veterinary
Hospital

REFERRING VET

Dr. Diane Heider

INVOICE

56620

DATE

2-7-23