



PATIENT PRESENTING CLINICAL SIGNS

Crash Todd Chronic Sneezing

SPECIES COMPUTED TOMOGRAPHIC STUDY OF THE HEAD

Feline A head CT without contrast is provided for review.

BREED COMPUTED TOMOGRAPHIC FINDINGS

DSH Mild hypoattenuating fluid material accumulation that is confluent to the nasal turbinates with minor loss of turbinate architecture and asymmetry is noted within the rostral aspect of the nasal cavity and extending slightly caudally along the axial aspect of the nasal cavity. The soft tissue fluid attenuating material is also more evident ventrally.

SEX No evidence of a mass effect or bone lytic lesion.

MN The frontal sinuses are asymmetrical and likely an individual variation.

Bilaterally, the bullae are unremarkable. The external ear apparatus is normal.

AGE Minor hypoattenuating fluid material is noted in the choana. The pharynx and larynx are normal.

8 Years The retrobulbar spaces normal.

Cribriform plate is normal.

INTERPRETED BY The temporomandibular joints are bilaterally congruent.

Tilde Rodrigues Froes, DMV, MSc., Dr. Med Vet., Dipl. CBraRVet The maxillary and mandibular teeth are normal.

The brain is normal, no mass effect.

HOSPITAL NAME No evidence of enlarged mandibular and medial retropharyngeal lymph nodes.

Animal Medical Center of Mt. Pleasant No other abnormalities are identified.

COMPUTED TOMOGRAPHIC DIAGNOSIS

- Mild destructive rhinitis and mild nasal fluid accumulation.
- No evidence of mass effect.

REFERRING VET INTERPRETATION OF THE FINDINGS & FURTHER RECOMMENDATIONS

Elaine Beck, DVM Differential diagnosis for mild destructive rhinitis includes viral, lymphocytic plasmocytic, and bacterial. Early infectious fungal disease cannot be ruled out but is less likely.

INVOICE

56980

DATE

2-28-23



PATIENT

Crash Todd

SPECIES

Feline

BREED

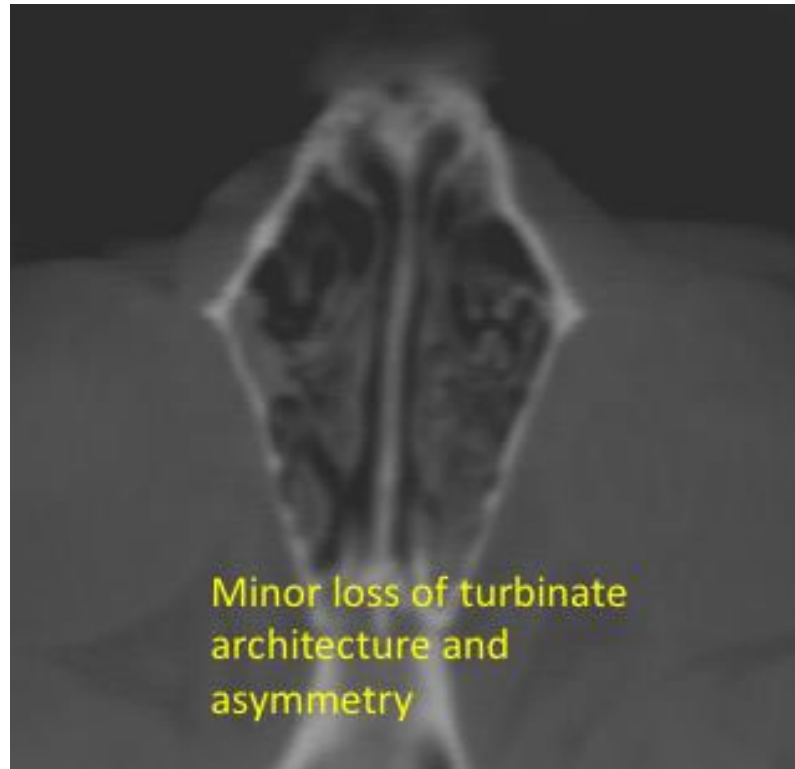
DSH

SEX

MN

AGE

8 Years



INTERPRETED BY

Tilde Rodrigues Froes,
DMV, MSc., Dr. Med
Vet., Dipl. CBraRVet

HOSPITAL NAME

Animal Medical
Center of Mt.
Pleasant

REFERRING VET

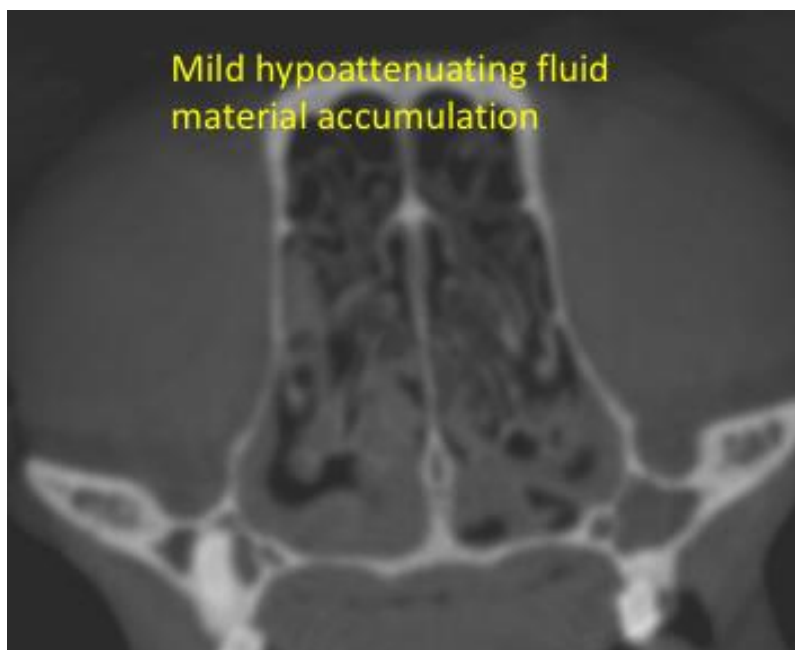
Elaine Beck, DVM

INVOICE

56980

DATE

2-28-23





PATIENT

Crash Todd

The information and recommendations provided are based on the images presented by the referring veterinarian. No evaluation can be communicated regarding pathology that was not visible in the image/video clips provided.

SPECIES

Feline

Thank you for this referral. If the clinical or image interpretation does not parallel your findings or if I can be of any further assistance please contact me.

BREED

DSH

Tilde Rodrigues Froes, DMV, MSc., Dr. Med.Vet., Dipl.CBraRVet
info@sonopath.com

SEX

MN

AGE

8 Years

INTERPRETED BY

Tilde Rodrigues Froes,
DMV, MSc., Dr. Med
Vet., Dipl. CBraRVet

HOSPITAL NAME

Animal Medical
Center of Mt.
Pleasant

REFERRING VET

Elaine Beck, DVM

INVOICE

56980

DATE

2-28-23