



PATIENT

Benny McLemore

SPECIES

Canine

BREED

French Bulldog

SEX

Male

AGE

1 Year, 5 Months

INTERPRETED BY

Tilde Rodrigues Froes,
DMV, MSc., Dr. Med
Vet., Dipl. CBraRVet

HOSPITAL NAME

Neel Veterinary
Hospital

REFERRING VET

D

INVOICE

56983

DATE

2-28-23

PRESENTING CLINICAL SIGNS

PEt has been having issues opening his mouth. RDVM thought that there might be something lodged in the esophagus. The scope showed some bruising and alot of fluid in the stomach. Pet will not allow you to open the mouth.

COMPUTED TOMOGRAPHIC STUDY OF THE HEAD, CERVICAL SOFT TISSUE AND CRANIAL THORACIC STRUCTURES

A pre- and post-contrast CT study of the head, cervical soft tissue and cranial thoracic structures are provided for review.

COMPUTED TOMOGRAPHIC FINDINGS

The left tonsillar region is enlarged, and an ill-defined soft tissue attenuating, heterogeneously and enhancing mass effect is seen. The mass effect measures approximately 1.1cm x 1.9cm x 2.2cm. Mild fat-stranding is seen in the adjacent cervical soft tissue structures. No mineral or hyperattenuating foreign material is seen. No evidence of fistula.

The right tonsillar region is normal.

The soft palate is mildly elongated.

The retropharyngeal lymph nodes are mildly asymmetrical, the left is mildly thickened in comparison to the right.

The mandibular lymph nodes are normal.

The salivary and parotid glands are normal in size, shape, and contour.

Mild hypoattenuating fluid material is seen in the ventral nasal cavity.

Dome-shaped calvarium and rudimentary frontal sinuses are seen.

The bone structures of the head and face are normal.

The mandibular and maxillary osseous structures are normal. However, are shorter because of breed characteristics, and teeth present crowding and misalignment. There is mild horizontal and vertical bone loss along the teeth.

The temporomandibular joints are bilaterally congruent.

The cervical and cranial thoracic esophagus are moderately dilatated with gas. No radiopaque foreign material is seen in the collimated esophagus.

The remainder of the collimated thorax is normal.



PATIENT **COMPUTED TOMOGRAPHIC DIAGNOSIS**

Benny McLemore

- Left side enlarged tonsil and mass effect. Differential diagnosis includes tonsillitis, less likely tonsillitis correlated to a previous foreign material trauma, however, no evidence of mineral or hyperattenuating foreign material. A less likely differential diagnosis includes tonsillar neoplasm.
- Mild left sided retropharyngeal lymphadenitis.
- Elongated soft palate, correlated to brachycephalic syndrome.
- Mild nasal fluid accumulation, mild non-destructive rhinitis.
- Dome-shaped calvarium and rudimentary frontal sinuses correlated to brachycephalic characteristics.
- Malocclusion and crowding teeth correlated to the brachycephalic characteristics as well as mild periodontal disease.
- Cervical and cranial thoracic esophageal dilatation by intraluminal gas. Differential diagnosis includes anesthesia, previous aerophagy, and/or esophagitis. The caudal esophagus is not collimated on the field.

SPECIES

Canine

BREED

French Bulldog

SEX

Male

AGE

1 Year, 5 Months

INTERPRETATION OF THE FINDINGS & FURTHER RECOMMENDATIONS

The left sided tonsillitis could be the cause of the pain and difficulty of opening the mouth. A small and/or radiotransparent foreign material correlated to the inflammation cannot be excluded. The causes of tonsillitis include a bacterial infection, viral infectious (canine adenovirus or less likely distemper), and environmental irritants. Tonsillar neoplasm, for example, tonsillar carcinoma is a more unlikely differential diagnosis, especially because of the age of the patient. A cervical ultrasound could be a reasonable next approach, or repeat of the endoscopy exam, and/or alternatively, an MRI.

INTERPRETED BY

Tilde Rodrigues Froes,
DMV, MSc., Dr. Med
Vet., Dipl. CBraRVet

HOSPITAL NAME

Neel Veterinary
Hospital

REFERRING VET

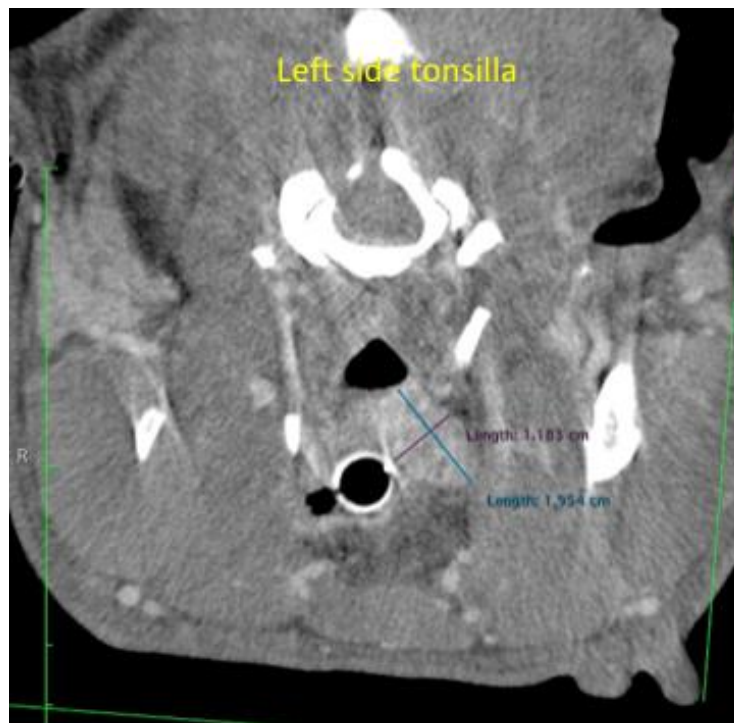
D

INVOICE

56983

DATE

2-28-23





PATIENT

Benny McLemore

SPECIES

Canine

BREED

French Bulldog

SEX

Male

AGE

1 Year, 5 Months

INTERPRETED BY

Tilde Rodrigues Froes,
DMV, MSc., Dr. Med
Vet., Dipl. CBraRVet

HOSPITAL NAME

Neel Veterinary
Hospital

REFERRING VET

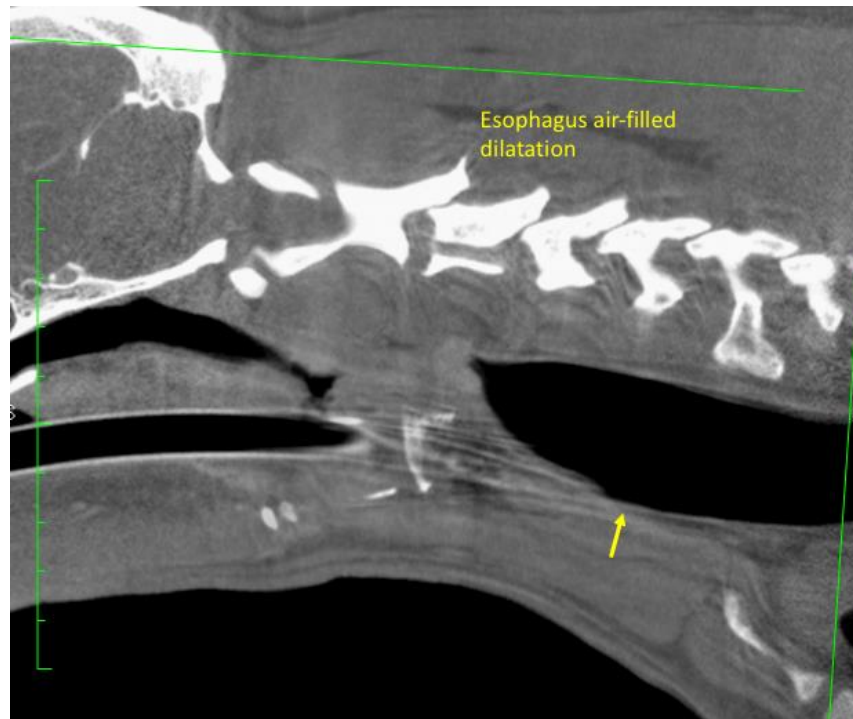
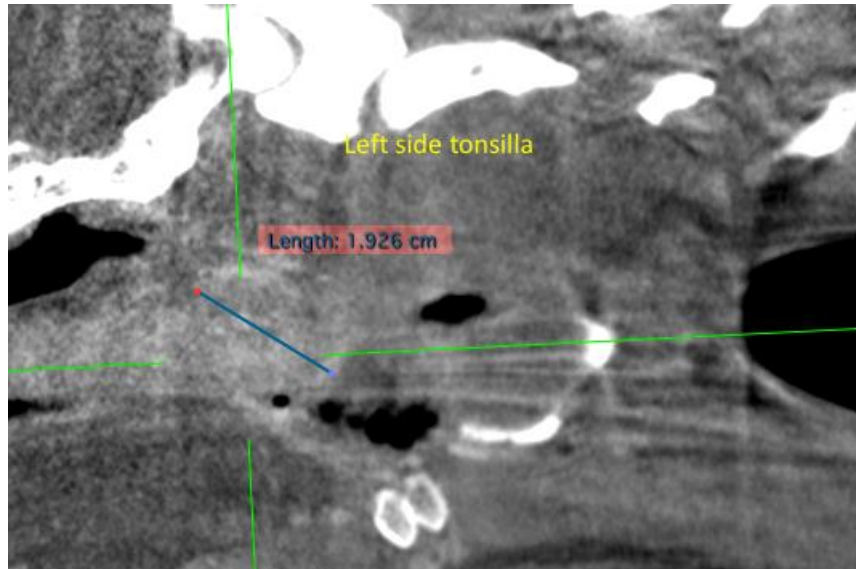
D

INVOICE

56983

DATE

2-28-23





PATIENT

Benny McLemore

The information and recommendations provided are based on the images presented by the referring veterinarian. No evaluation can be communicated regarding pathology that was not visible in the image/video clips provided.

SPECIES

Canine

Thank you for this referral. If the clinical or image interpretation does not parallel your findings or if I can be of any further assistance please contact me.

BREED

French Bulldog

Tilde Rodrigues Froes, DMV, MSc., Dr. Med.Vet., Dipl.CBraRVet
info@sonopath.com

SEX

Male

AGE

1 Year, 5 Months

INTERPRETED BY

Tilde Rodrigues Froes,
DMV, MSc., Dr. Med
Vet., Dipl. CBraRVet

HOSPITAL NAME

Neel Veterinary
Hospital

REFERRING VET

D

INVOICE

56983

DATE

2-28-23