



PATIENT

Sophie Gilsinger

SPECIES

Canine

BREED

Chi-mix

SEX

Female Spayed

AGE

13

WEIGHT

15.2

INTERPRETED BY

Tilde Rodrigues Froes,
DMV, MSc., Dr. Med
Vet., Dipl. CBraRVet

IMAGING PERFORMED BY

Cari P.

HOSPITAL NAME

Bell Parkway
Veterinary Hospital

REFERRING VET

Dr. Engelshall

INVOICE

73955

DATE

2-25-26

PRESENTING CLINICAL SIGNS

- Presented with episodes of unable to right herself, stiffness and acting painful on 1/27/2026, 2/4/26, and 2/19/26. On PE pt had decreased cervical range of motion and is tense/guarded on cervical spinal palpation, otherwise orthopedic exam was normal. Historically elevated LEs: 12/20/25- ALT 182 (H), ALP 298 (H) and 2/4/26- ALT 282 (H), ALP 329 (H), GGT 15 (H), otherwise bloodwork normal. Valley fever test 1/13/26 negative. On Prednisolone and Gabapentin. Radiographs and review 2/25/26: Conclusions: 1. Unremarkable vertebral column. This does not exclude the possibility of myelopathy from disc disease, myelitis, ischemic myelopathy, neoplasia, other. Soft tissue injury is also possible but not seen. No overt evidence of orthopedic disease is seen.
- - CT to evaluate spine and rule out causes for painful episodes.
- - Historical grade 2 heart murmur, collapsing trachea and chronic cough.
- - History of eating rocks, recently vomited a few up. Episodes of foaming at the mouth, owner concerned about gastric reflux.

COMPUTED TOMOGRAPHIC STUDY OF THE SPINE

A pre- and post- contrast CT study of the entire spine is provided for review totaling 2 series. One pre-contrast bone algorithm. One post-contrast series soft tissue algorithm.

COMPUTED TOMOGRAPHIC FINDINGS

CERVICAL, THORACIC AND LUMBAR SPINE

The vertebral column demonstrates a normal vertebral formula (C1–C7, T1–T13, L1–L7, sacrum).

Vertebral alignment is within normal anatomical limits.

At the level of L4–L5, a tiny mineral hyperattenuating focus is located along the ventral aspect of the vertebral canal. There is no evidence of spinal cord compression at this level.

Few foci of dural mineralization (dural calcifications), incidental. The remaining vertebral canal, including the epidural fat, is unremarkable.

T4–T5 and T5–T6 demonstrate tiny incomplete bridging spondylosis deformans.

The remaining vertebral bodies are normal in size, shape, and attenuation. No aggressive osseous lesions are identified.

The adjacent paraspinous musculature is symmetrical and within normal limits.

Incidental Findings (Collimated Structures)

A small hyperattenuating mineral foreign material is visible within the stomach.

The remaining visualized thoracic and abdominal structures are unremarkable.



PATIENT

Sophie Gilsinger

SPECIES

Canine

BREED

Chi-mix

SEX

Female Spayed

AGE

13

WEIGHT

15.2

INTERPRETED BY

Tilde Rodrigues Froes,
DMV, MSc., Dr. Med
Vet., Dipl. CBraRVet

IMAGING PERFORMED BY

Cari P.

HOSPITAL NAME

Bell Parkway
Veterinary Hospital

REFERRING VET

Dr. Engelshall

INVOICE

73955

DATE

2-25-26

A tiny subcutaneous soft tissue nodule is observed in the dorsal region at the level of T9, measuring approximately 4.7 mm.

COMPUTED TOMOGRAPHIC DIAGNOSIS

- Tiny, mineralized focus at L4–L5 along the ventral vertebral canal without evidence of spinal cord compression. Differential diagnoses include dural calcifications or discrete discal herniation.
- Mild multifocal spondylosis deformans (T4–T6), incidental
- Tiny dorsal subcutaneous soft tissue nodule at level of T9. Possible granuloma or tiny soft tissue neoplasia.

INTERPRETATION OF THE FINDINGS & FURTHER RECOMMENDATIONS

The CT examination does not demonstrate significant spinal cord compression or aggressive vertebral disease that would clearly explain the reported painful episodes.

A tiny, mineralized focus is present at L4–L5 without evidence of cord compression. The identified dural mineralizations are incidental age-related findings and are not typically associated with clinical neurological dysfunction.

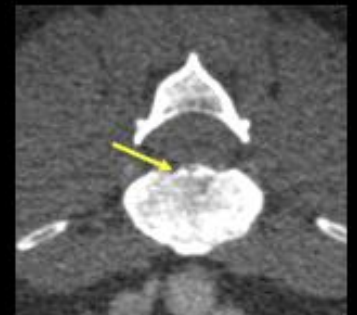
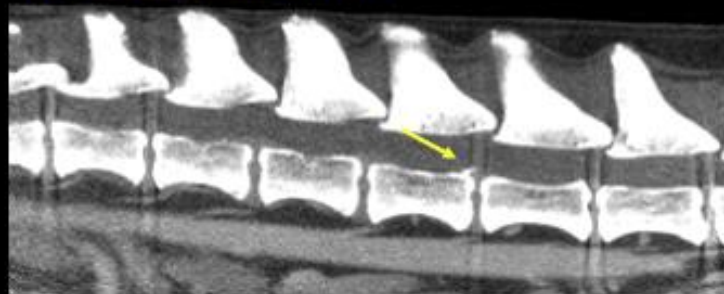
It is important to note that computed tomography has limited sensitivity for detecting non-mineralized disc extrusion, inflammatory myelopathy, ischemic myelopathy, or intramedullary spinal cord disease. If clinical signs persist or progress, magnetic resonance imaging (MRI) is recommended for further evaluation of the spinal cord and intervertebral discs.

The small mineral foreign material within the stomach is likely incidental.

TECHNICAL COMMENTS

Lateral markers were inverted on the submitted images.

Tiny, mineralized focus at L4–L5 along the ventral vertebral canal without evidence of spinal cord compression





PATIENT

Sophie Gilsinger

SPECIES

Canine

BREED

Chi-mix

SEX

Female Spayed

AGE

13

WEIGHT

15.2

INTERPRETED BY

Tilde Rodrigues Froes,
DMV, MSc., Dr. Med
Vet., Dipl. CBraRVet

IMAGING PERFORMED BY

Cari P.

HOSPITAL NAME

Bell Parkway
Veterinary Hospital

REFERRING VET

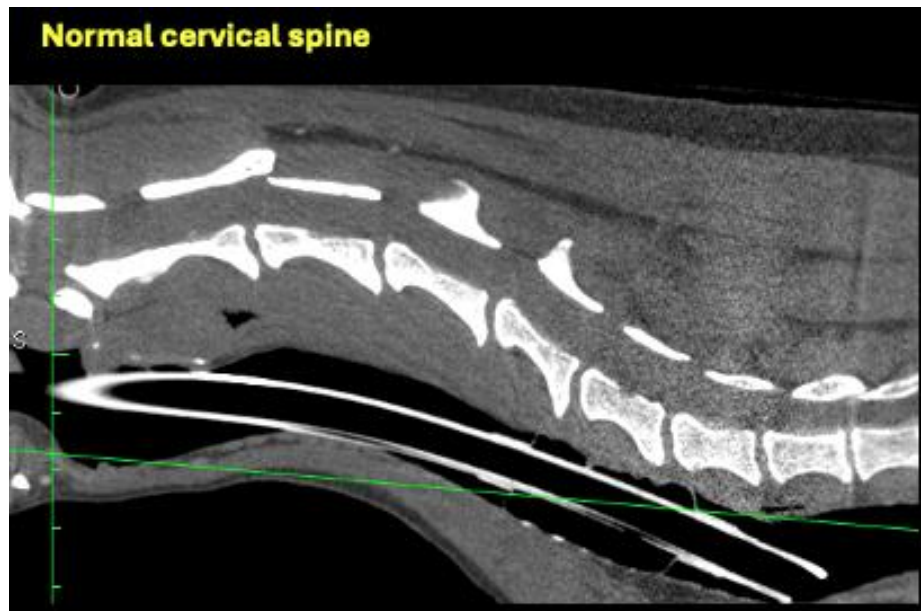
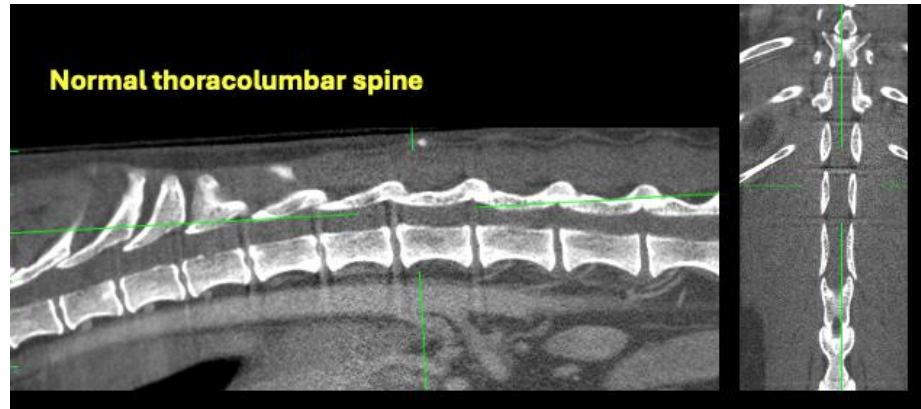
Dr. Engelshall

INVOICE

73955

DATE

2-25-26





PATIENT

Sophie Gilsinger

SPECIES

Canine

BREED

Chi-mix

SEX

Female Spayed

AGE

13

WEIGHT

15.2

INTERPRETED BY

Tilde Rodrigues Froes,
DMV, MSc., Dr. Med
Vet., Dipl. CBraRVet

IMAGING PERFORMED BY

Cari P.

HOSPITAL NAME

Bell Parkway
Veterinary Hospital

REFERRING VET

Dr. Engelshall

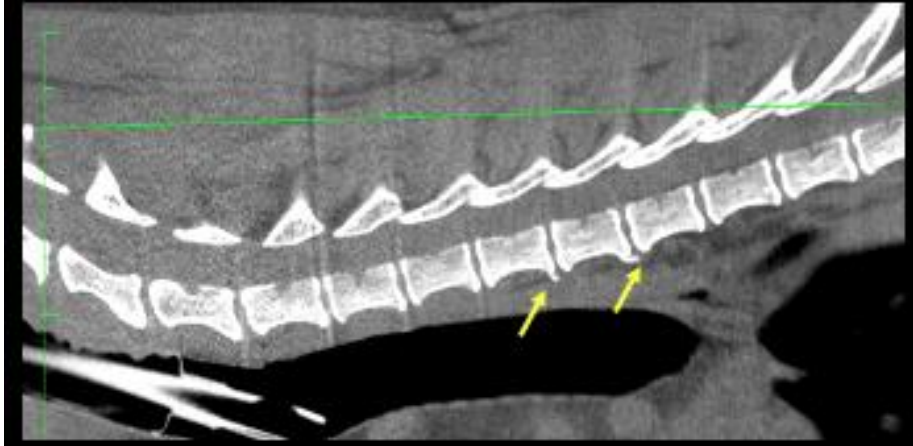
INVOICE

73955

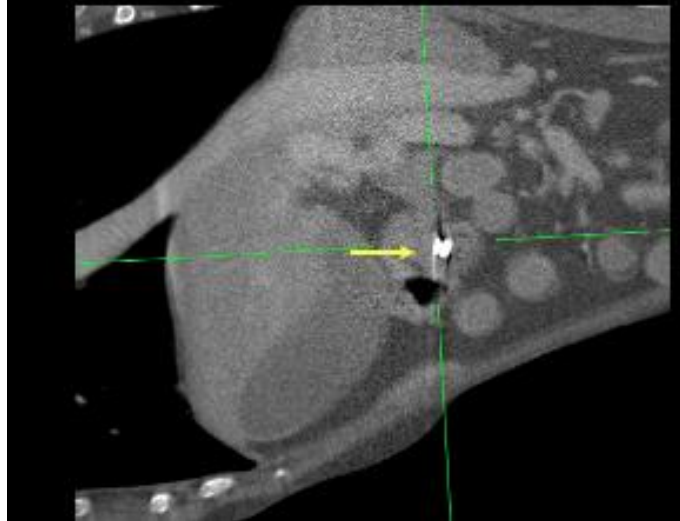
DATE

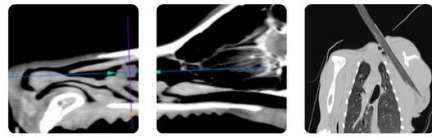
2-25-26

Incidental T4-5 and T5-6 tiny spondylosis



Small mineral foreign material within the stomach, incidental





PATIENT

Sophie Gilsinger

SPECIES

Canine

BREED

Chi-mix

SEX

Female Spayed

AGE

13

WEIGHT

15.2

INTERPRETED BY

Tilde Rodrigues Froes,
DMV, MSc., Dr. Med
Vet., Dipl. CBraRVet

IMAGING PERFORMED BY

Cari P.

HOSPITAL NAME

Bell Parkway
Veterinary Hospital

REFERRING VET

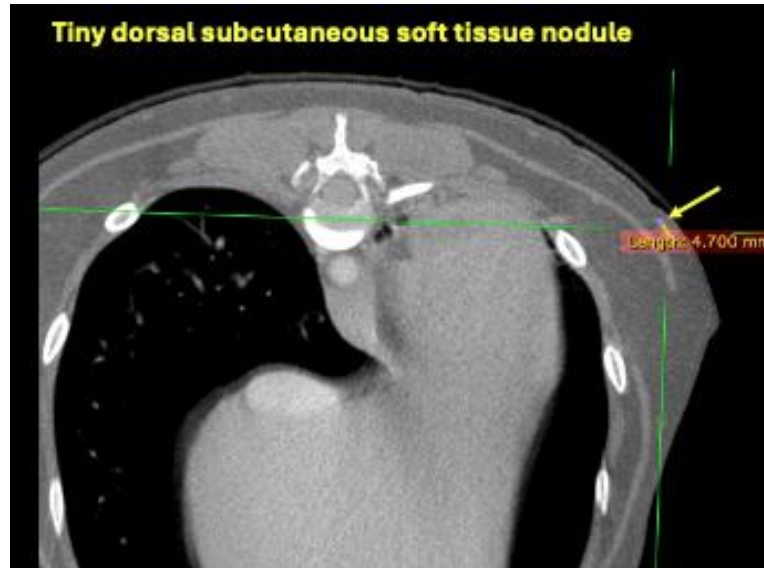
Dr. Engelshall

INVOICE

73955

DATE

2-25-26



The information and recommendations provided are based on the images presented by the referring veterinarian. No evaluation can be communicated regarding pathology that was not visible in the image/video clips provided.

Thank you for this referral. If the clinical or image interpretation does not parallel your findings or if I can be of any further assistance, please contact me.

Tilde Rodrigues Froes, DMV, MSc., Dr. Med.Vet., Dipl.CBraRVet
info@sonopath.com