

PATIENT

Shelli Gubser

SPECIES

Canine

BREED

Schnoodle

SEX

FS

AGE

10Y

WEIGHT

26.5

INTERPRETED BY

Tilde Rodrigues Froes,
DMV, MSc., Dr. Med
Vet., Dipl. CBraRVet

IMAGING PERFORMED BY

Andrea Johnson

HOSPITAL NAME

Scottsdale Veterinary
Clinic

REFERRING VET

Dr. Hertz

INVOICE

73956

DATE

2-25-26

PRESENTING CLINICAL SIGNS

- A subcutaneous growth was noted on the right pelvic limb
- Est. 4-5 inch, soft, ill-defined, semi moveable subcutaneous growth encompassing right thigh, found during exam. Hasn't given the patient any trouble not painful either.

COMPUTED TOMOGRAPHIC STUDY OF THE HINDLIMBS

A pre-contrast and post-contrast CT study of the hindlimbs are provided for review, totaling two series, soft tissue and bone algorithm.

COMPUTED TOMOGRAPHIC FINDINGS

HINDLIMBS

There is a large, elongated, homogeneous fat-attenuating mass located intermuscularly within the right proximal pelvic limb. The mass is well delineated and contained by the adjacent musculature, with smooth and regular margins. It is predominantly situated between the semitendinosus, semimembranosus, and biceps femoris muscles.

The lesion measures approximately 9.4 × 6.1 × 7.1 cm.

There is a compressive effect on the adjacent vascular structures; however, no intraluminal filling defects are identified.

The popliteal lymph node is normal in size and attenuation.

The pelvic bones are within normal limits.

The coxofemoral joints are congruent.

COMPUTED TOMOGRAPHIC DIAGNOSIS

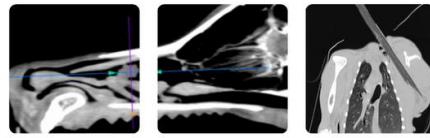
- Large, well-defined, homogeneous fat-attenuating intermuscular mass within the right proximal pelvic limb. Primary differential diagnoses include intermuscular lipoma, less likely infiltrative lipoma (based on well-defined margins and lack of aggressive features)
- No evidence of regional lymphadenopathy or vascular invasion.

INTERPRETATION OF THE FINDINGS & FURTHER RECOMMENDATIONS

The tomographic findings are most consistent with a large intermuscular lipoma affecting the right proximal pelvic limb. The homogeneous fat attenuation, smooth margins, and absence of contrast enhancement or invasive behavior support a benign adipose tissue neoplasm.

Although there is mild compression of adjacent vascular structures, there is no evidence of vascular invasion or thrombosis.

Consider a fine-needle aspiration for confirmation.



PATIENT

Shelli Gubser

SPECIES

Canine

BREED

Schnoodle

SEX

FS

AGE

10Y

WEIGHT

26.5

INTERPRETED BY

Tilde Rodrigues Froes,
DMV, MSc., Dr. Med
Vet., Dipl. CBraRVet

IMAGING PERFORMED BY

Andrea Johnson

HOSPITAL NAME

Scottsdale Veterinary
Clinic

REFERRING VET

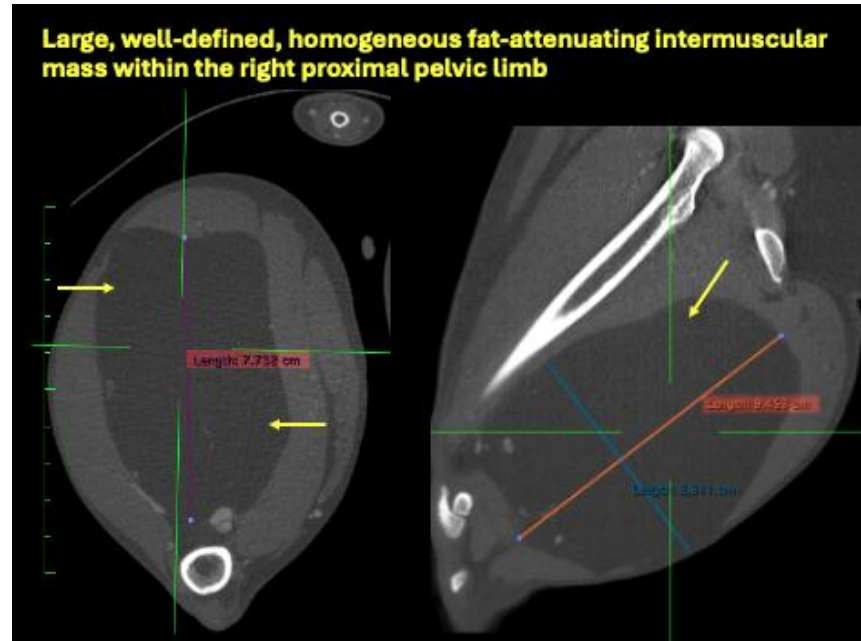
Dr. Hertz

INVOICE

73956

DATE

2-25-26



The information and recommendations provided are based on the images presented by the referring veterinarian. No evaluation can be communicated regarding pathology that was not visible in the image/video clips provided.

Thank you for this referral. If the clinical or image interpretation does not parallel your findings or if I can be of any further assistance, please contact me.

Tilde Rodrigues Froes, DMV, MSc., Dr. Med.Vet., Dipl.CBraRVet
info@sonopath.com