



PATIENT

Monkey D. Luffy
Alioto

SPECIES

Feline

BREED

Domestic Shorthair

SEX

Male Neutered

AGE

1Y, 24D

WEIGHT

7.56lbs

INTERPRETED BY

Tilde Rodrigues Froes,
DMV, MSc., Dr. Med
Vet., Dipl. CBraRVet

IMAGING PERFORMED BY

Joseph D'Abbraccio,
DVM

HOSPITAL NAME

Catskill Veterinary
Services, PLLC

REFERRING VET

Joseph D'Abbraccio,
DVM

INVOICE

73936

DATE

2-25-26

PRESENTING CLINICAL SIGNS

- Reason for Visit: Suspected esophageal foreign body and megaesophagus.
- History: Owner reported concern for possible esophageal foreign body, with symptoms beginning on Thursday including discomfort, abnormal posture with head down, and palpable abnormality above the thoracic inlet. Monkey has a history of megaesophagus diagnosed five months prior, confirmed by barium study. Owner noted history of ingesting foreign material, including hair ties, with regurgitation of solids; currently being syringe fed watered-down mousse, which he licks up himself, and is fed in an elevated position. Owner stated no vomiting or diarrhea observed. Monkey is up to date on preventatives; previously used Revolution and currently NexGard Combo during outdoor activity. Monkey is FIV and FeLV negative per owner's report. Monkey lives with five other cats, does not like other cats or ferrets but is tolerant of dogs, and is described as a 'shoulder cat' who may attempt to climb people.
- Chest CT done for metastasis check and any abnormalities.

Abnormal PE/Chem/CBC/UA Results: PE: WNL CBC: RDW 29.5; Neutrophils 0.29; Monocytes 1.15; Eosinophils 0.08; Platelets 115; Chem: WNL

COMPUTED TOMOGRAPHIC STUDY OF THE THORAX

A pre- and post-contrast CT study of thorax are provided for review totaling 2 series. One pre-contrast series of the thorax, bone algorithm. One post-contrast series of the thorax, soft tissue algorithm.

COMPUTED TOMOGRAPHIC FINDINGS

THORAX

There is moderate dilatation of the cervical esophagus. A discrete fold is noted at the level of C5. Distal to this level, the esophagus demonstrates marked dilatation. At this portion the esophagus is filled with intraluminal gas.

There is marked dilation of the precardiac thoracic esophagus. At the level of the heart base, there is a focal luminal narrowing. Caudal to this region, the esophagus remains mildly dilated.

The precardiac esophagus is distended by gas and a large volume of heterogeneous, mixed-attenuation intraluminal material, which appears relatively well-circumscribed and ovoid in configuration.

The aortic arch is mildly displaced toward the right hemithorax and is not centrally positioned. The left subclavian artery appears to arise more distally than expected and follows a retroesophageal course.

There is persistence of the left cranial vena cava (CrVC), with associated apparent dilation of the vertebral venous system at approximately the level of T6.

The cranial mediastinal lymph nodes are mildly enlarged. The sternal and tracheobronchial lymph nodes are within normal limits.

The thoracic trachea is mildly displaced. The main bronchi are within normal limits.

The pulmonary parenchyma demonstrates normal attenuation. No pulmonary micronodules, nodules, or mass lesions are identified.



PATIENT

Monkey D. Luffy
Alioto

SPECIES

Feline

BREED

Domestic Shorthair

SEX

Male Neutered

AGE

1Y, 24D

WEIGHT

7.56lbs

INTERPRETED BY

Tilde Rodrigues Froes,
DMV, MSc., Dr. Med
Vet., Dipl. CBraRVet

IMAGING PERFORMED BY

Joseph D'Abbraccio,
DVM

HOSPITAL NAME

Catskill Veterinary
Services, PLLC

REFERRING VET

Joseph D'Abbraccio,
DVM

INVOICE

73936

DATE

2-25-26

The bronchial tree shows normal branching and tapering. Bronchial walls are thin and smooth, with a normal bronchus-to-artery ratio.

The cardiac silhouette is within normal limits for size and shape.

The pleural space, diaphragm, and thoracic wall are unremarkable.

T6 exhibits characteristics of a hemivertebra, with mild focal thoracic scoliosis at this level.

There is apparent absence of one cervical vertebral body (vertebral count C1 – C6 identified).

The transverse process of L1 demonstrates a supernumerary rib-like structure.

COMPUTED TOMOGRAPHIC DIAGNOSIS

- Marked cranial thoracic megaesophagus, with focal narrowing at the level of the heart base. The configuration of the abnormal dilatation and associated vascular findings are highly suggestive of a vascular ring anomaly, most suspected with a persistent right aortic arch and aberrant left subclavian artery.
- Variable air dilatation of the cervical esophagus is observed. A discrete fold is noted at the level of C5. Differential diagnoses include an esophageal membrane (web), esophageal stricture, or a thin intraluminal fluid-gas interface.
- Large volume of heterogeneous intraluminal esophageal content, compatible with retained ingesta and/or suspected esophageal bezoar foreign material.
- Persistent left cranial vena cava, with secondary dilation of the vertebral venous plexus (incidental congenital vascular variation).
- Mild cranial mediastinal lymphadenomegaly, likely reactive.
- Multiple congenital skeletal variations, including T6 hemivertebra with mild focal thoracic scoliosis, supernumerary rib, and possible cervical vertebral anomaly.
- No evidence of pulmonary disease (e.g., aspiration pneumonia)

INTERPRETATION OF THE FINDINGS & FURTHER RECOMMENDATIONS

The tomographic findings demonstrate severe cranial megaesophagus with a focal constriction at the level of the heart base, in association with abnormal positioning of the aortic arch and retroesophageal course of the left subclavian artery. These findings are highly suspected with a vascular ring anomaly, most likely a persistent right aortic arch, resulting in extraluminal esophageal compression.

The large volume of heterogeneous intraluminal material within the precardiac esophagus may represent retained food material and/or bezoar foreign material.

Interpretation of the variable cervical esophageal finding is challenging. A membranous structure may be mimicked by intraluminal fluid, particularly in this patient with multiple concurrent esophageal abnormalities. Additionally, in a sedated patient, variable gas and fluid distension may further alter esophageal appearance.

For more accurate assessment of esophageal motility and functional progression, contrast esophagography and/or esophagoscopy is recommended.

Given the patient's young age and chronic regurgitation history, surgical consultation for correction of the suspected vascular ring anomaly is suggested.



PATIENT

Monkey D. Luffy
Alioto

SPECIES

Feline

BREED

Domestic Shorthair

SEX

Male Neutered

AGE

1Y, 24D

WEIGHT

7.56lbs

INTERPRETED BY

Tilde Rodrigues Froes,
DMV, MSc., Dr. Med
Vet., Dipl. CBraRVet

IMAGING PERFORMED BY

Joseph D'Abbraccio,
DVM

HOSPITAL NAME

Catskill Veterinary
Services, PLLC

REFERRING VET

Joseph D'Abbraccio,
DVM

INVOICE

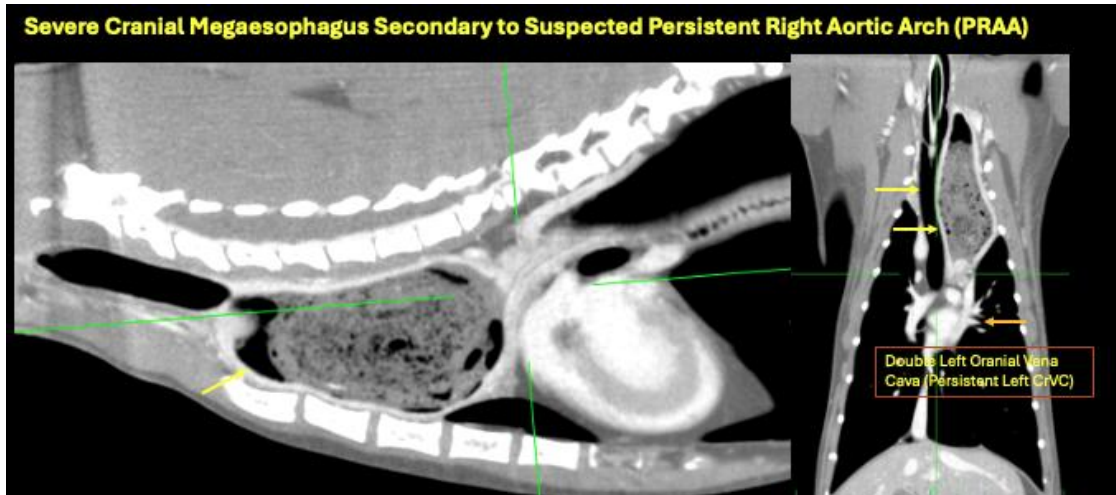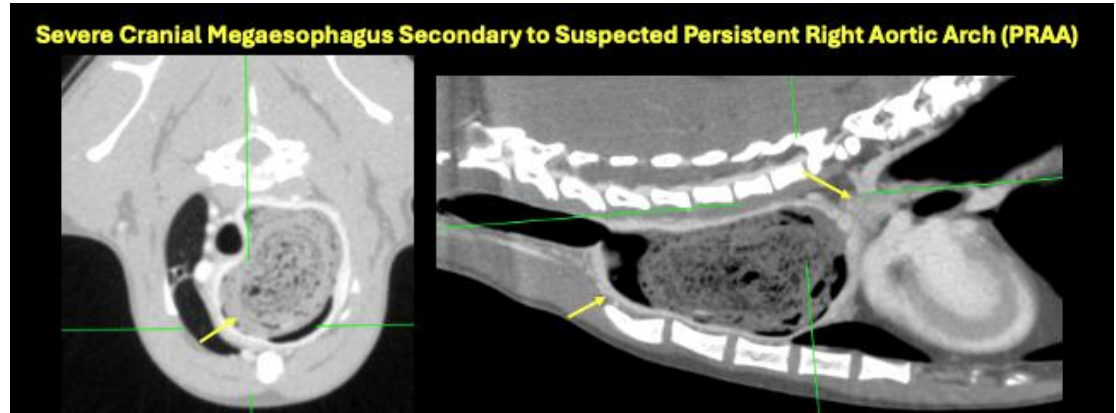
73936

DATE

2-25-26

Supportive management of megaesophagus should continue. The absence of pulmonary infiltrates is favorable, as there is currently no CT evidence of aspiration pneumonia.

The persistent left cranial vena cava and the identified vertebral venous and skeletal anomalies are interpreted as incidental congenital variations; however, their presence should be acknowledged prior to any surgical or interventional planning.





PATIENT

Monkey D. Luffy
Alioto

SPECIES

Feline

BREED

Domestic Shorthair

SEX

Male Neutered

AGE

1Y, 24D

WEIGHT

7.56lbs

INTERPRETED BY

Tilde Rodrigues Froes,
DMV, MSc., Dr. Med
Vet., Dipl. CBraRVet

IMAGING PERFORMED BY

Joseph D'Abbraccio,
DVM

HOSPITAL NAME

Catskill Veterinary
Services, PLLC

REFERRING VET

Joseph D'Abbraccio,
DVM

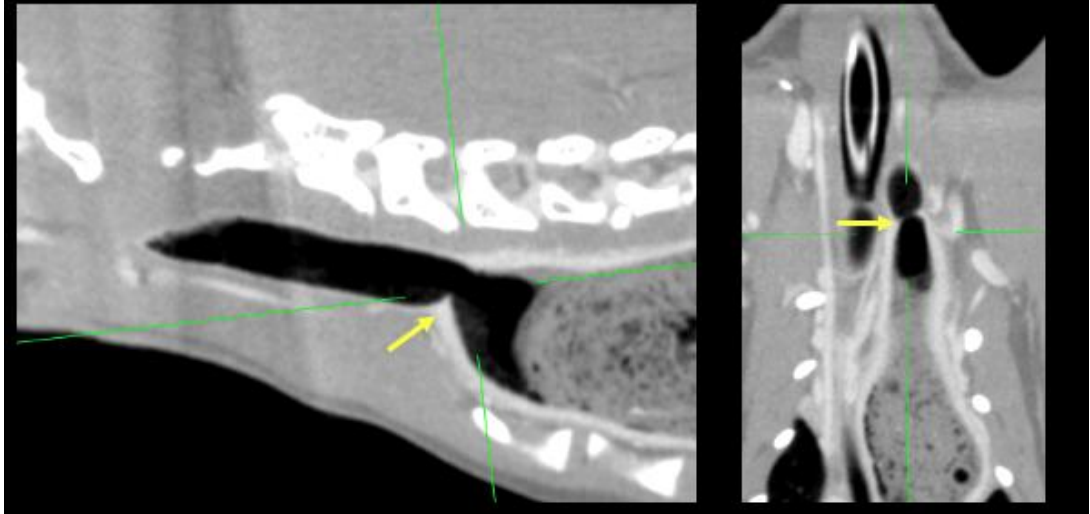
INVOICE

73936

DATE

2-25-26

A discrete fold is noted at the level of C5. DDX: include an esophageal membrane (web), esophageal stricture, or a thin intraluminal fluid interface.



The information and recommendations provided are based on the images presented by the referring veterinarian. No evaluation can be communicated regarding pathology that was not visible in the image/video clips provided.

Thank you for this referral. If the clinical or image interpretation does not parallel your findings or if I can be of any further assistance, please contact me.

Tilde Rodrigues Froes, DMV, MSc., Dr. Med.Vet., Dipl.CBraRVet
info@sonopath.com