



PATIENT

Suziq Mcpherson

SPECIES

Canine

BREED

Lab

SEX

FE

AGE

5M

WEIGHT

20

INTERPRETED BY

Tilde Rodrigues Froes,
DMV, MSc., Dr. Med
Vet., Dipl. CBraRVet

IMAGING PERFORMED BY

Eamon

HOSPITAL NAME

Belconnen Veterinary
Centre

REFERRING VET

Eamon

INVOICE

73915

DATE

2-23-26

PRESENTING CLINICAL SIGNS

- jumped out of car (stationary) 6feb
- left fore lameness unresolved since

Abnormal PE/Chem/CBC/UA Results: pending

COMPUTED TOMOGRAPHIC STUDY OF THE THORACIC LIMBS

Pre- and post-contrast CT series of the thoracic limbs (shoulder and elbow joints) are provided for review, totaling eight series. Transverse images were acquired using bone and soft tissue algorithms, pre- and post-contrast.

COMPUTED TOMOGRAPHIC FINDINGS

LEFT THORACIC LIMB - SHOULDER & ELBOW JOINTS

The scapulohumeral joint is within normal limits, with no evidence of joint effusion or articular surface irregularity.

The humeroulnar and humeroradial joints are congruent. The medial coronoid process and anconeal process are intact, with no evidence of fragmentation or fissure.

The scapula, humerus, radius, and ulna are normal in size, shape, and attenuation.

The antebrachial and carpal joints are unremarkable.

No traumatic osseous lesions, periosteal reaction, or asymmetric soft tissue swelling are identified.

RIGHT THORACIC LIMB - SHOULDER & ELBOW JOINTS

The scapulohumeral joint is within normal limits, with no evidence of joint effusion or articular surface irregularity.

The humeroulnar and humeroradial joints are congruent. The medial coronoid process and anconeal process are intact, with no evidence of fragmentation or fissure.

The scapula, humerus, radius, and ulna are normal in size, shape, and attenuation.

The antebrachial and carpal joints are unremarkable.

No traumatic osseous lesions, periosteal reaction, or asymmetric soft tissue swelling are identified.

Within the cranial thorax (collimated field), a visible soft tissue structure consistent with a persistent thymus is identified, considered incidental and age appropriate.

COMPUTED TOMOGRAPHIC DIAGNOSIS

- The bilateral elbow and shoulder joints are within normal limits.

INTERPRETATION OF THE FINDINGS & FURTHER RECOMMENDATIONS



PATIENT

Suziq Mcpheerson

There is no tomographic evidence of traumatic osseous injury or articular abnormality to explain the persistent left forelimb lameness.

SPECIES

Canine

Given the patient's age and clinical presentation, differential diagnoses for persistent lameness in the absence of CT-detectable osseous changes include soft tissue injury (e.g., ligamentous sprain, musculotendinous injury without identifiable swelling).

BREED

Lab

SEX

FE

AGE

5M

WEIGHT

20

INTERPRETED BY

Tilde Rodrigues Froes,
DMV, MSc., Dr. Med
Vet., Dipl. CBraRVet

IMAGING PERFORMED BY

Eamon

HOSPITAL NAME

Belconnen Veterinary
Centre

REFERRING VET

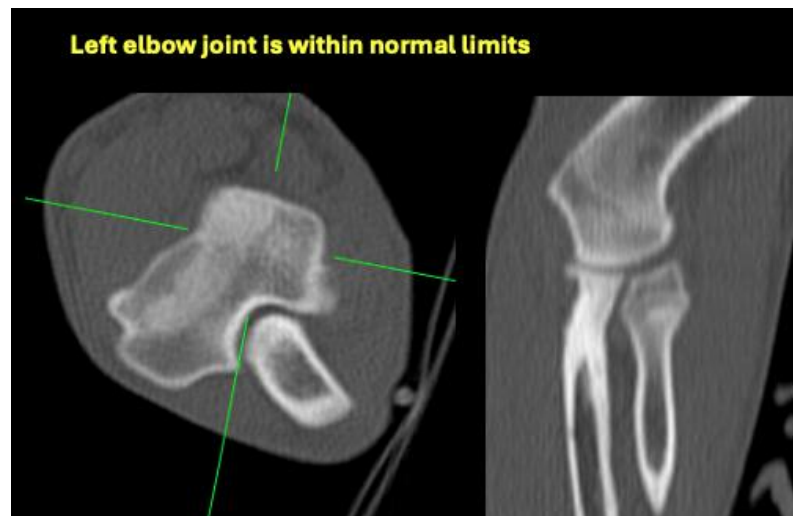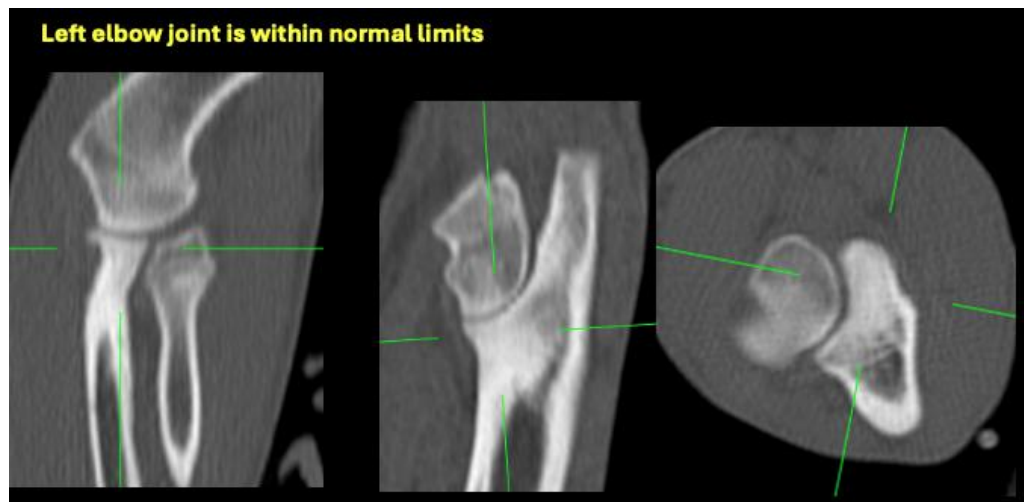Eamon

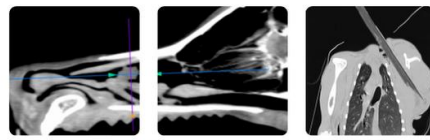
INVOICE

73915

DATE

2-23-26





PATIENT

Suziq Mcpherson

SPECIES

Canine

BREED

Lab

SEX

FE

AGE

5M

WEIGHT

20

INTERPRETED BY

Tilde Rodrigues Froes,
DMV, MSc., Dr. Med
Vet., Dipl. CBraRVet

IMAGING PERFORMED BY

Eamon

HOSPITAL NAME

Belconnen Veterinary
Centre

REFERRING VET

Eamon

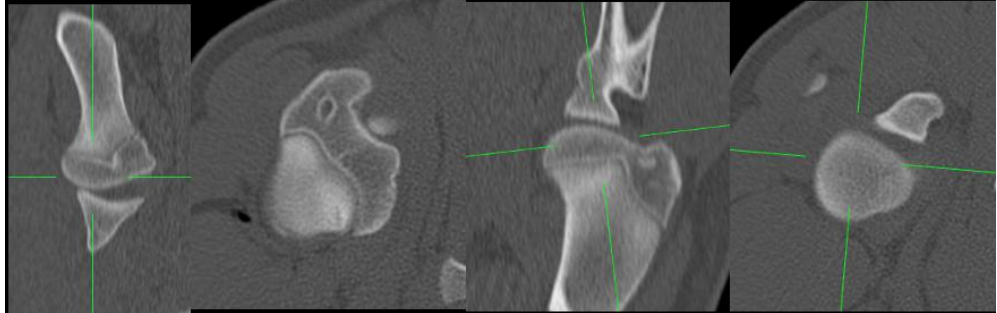
INVOICE

73915

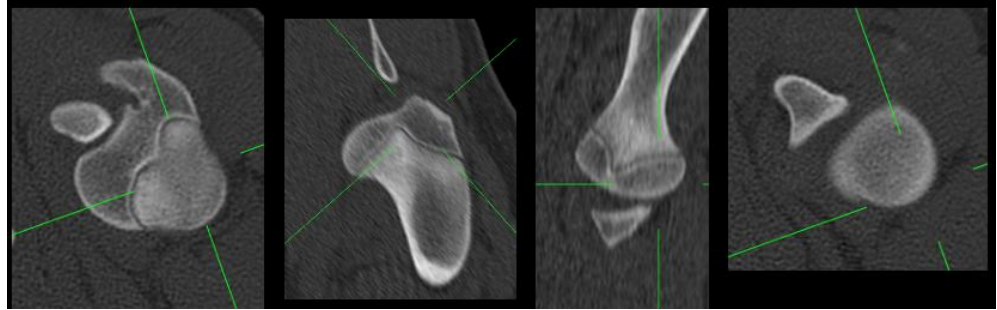DATE

2-23-26

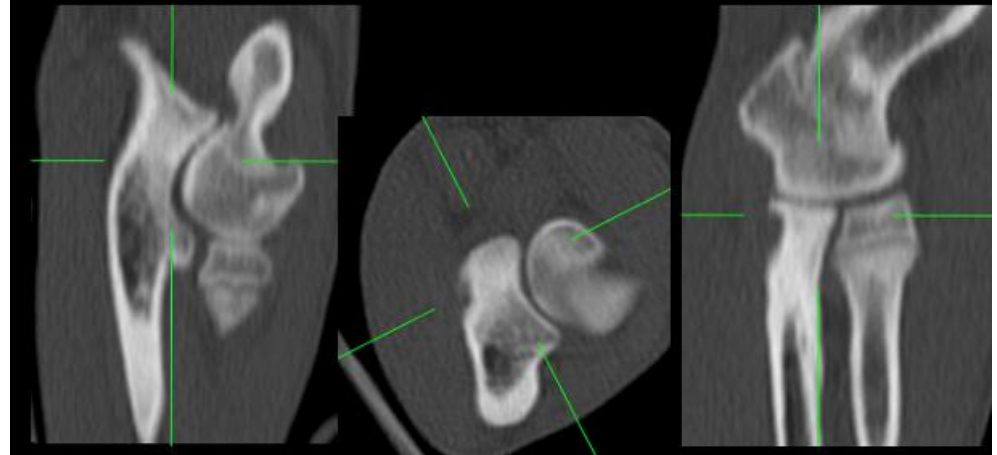
Left shoulder joint is within normal limits



Right shoulder joint is within normal limits



Right elbow joint is within normal limits



The information and recommendations provided are based on the images presented by the referring veterinarian. No evaluation can be communicated regarding pathology that was not visible in the image/video clips provided.

Thank you for this referral. If the clinical or image interpretation does not parallel your findings or if I can be of any further assistance, please contact me.

Tilde Rodrigues Froes, DMV, MSc., Dr. Med.Vet., Dipl.CBraRVet
info@sonopath.com