



PATIENT PRESENTING CLINICAL SIGNS

Piper Petri Pet presented today for a dental cleaning

SPECIES COMPUTED TOMOGRAPHIC STUDY OF THE HEAD

Canine A pre-contrast CT study of the head is provided for review. One pre-contrast series of head.

BREED COMPUTED TOMOGRAPHIC FINDINGS

Beagle There is a focal irregular moderately demarcated geographic lysis associated with the triadan 109, 209, and 310.

There is a focal irregular mildly demarcated geographic lysis associated with the triadan 110.

There is a minor focal geographic lysis associated with the triadan 210.

SEX

FS

A crown fracture of the triadan 205 is seen with retained small root.

All other teeth are present and unremarkable.

The temporomandibular joints are congruent and normal.

AGE

5 Years

The nasal cavity, pharynx, and larynx are normal.

The retrobulbar spaces normal.

Cribriform plate is preserved.

The frontal sinuses are normal.

The collimated brain is normal, no mass effect.

No other abnormalities are identified.

INTERPRETED BY

Tilde Rodrigues Froes, DMV, MSc., Dr. Med Vet., Dipl. CBraRVet

HOSPITAL NAME

Cranberry Holistic Pet Care

COMPUTED TOMOGRAPHIC DIAGNOSIS

- Tooth root abscesses in triadans 109 and 209.
- Severe periodontal disease in triadans 110 and 310.
- Mild focal periodontal disease in the triadan 210.
- Fracture in the triadan 205 with small, retained root.

REFERRING VET

Cynthia Maro

INTERPRETATION OF THE FINDINGS & FURTHER RECOMMENDATIONS

The tomographic findings of the dental arcade show multifocal periodontal disease in particular teeth. Recommending extraction of the triadans 109, 209, as well as 110, and 310. Correlate with oral/dental exam.

INVOICE

56920

DATE

2-23-23



PATIENT

Piper Petri

SPECIES

Canine

BREED

Beagle

SEX

FS

AGE

5 Years

INTERPRETED BY

Tilde Rodrigues Froes,
DMV, MSc., Dr. Med
Vet., Dipl. CBraRVet

HOSPITAL NAME

Cranberry Holistic
Pet Care

REFERRING VET

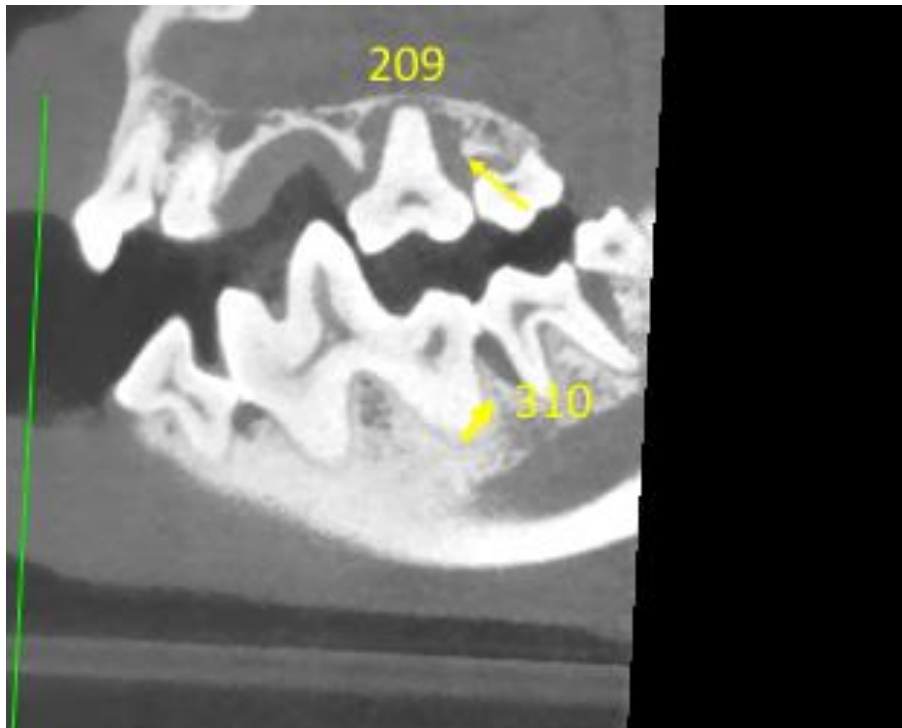
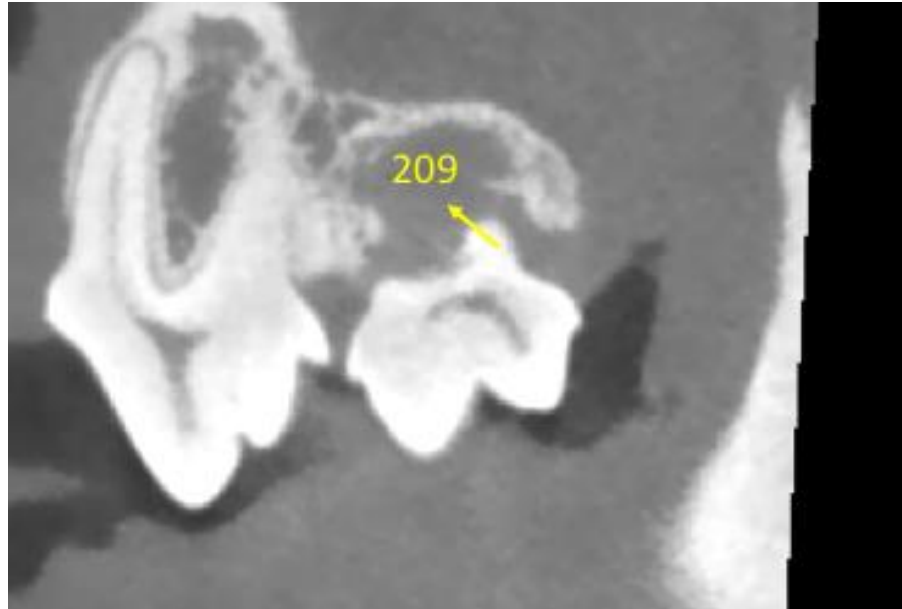Cynthia Maro

INVOICE

56920

DATE

2-23-23





PATIENT

Piper Petri

SPECIES

Canine

BREED

Beagle

SEX

FS

AGE

5 Years

INTERPRETED BY

Tilde Rodrigues Froes,
DMV, MSc., Dr. Med
Vet., Dipl. CBraRVet

HOSPITAL NAME

Cranberry Holistic
Pet Care

REFERRING VET


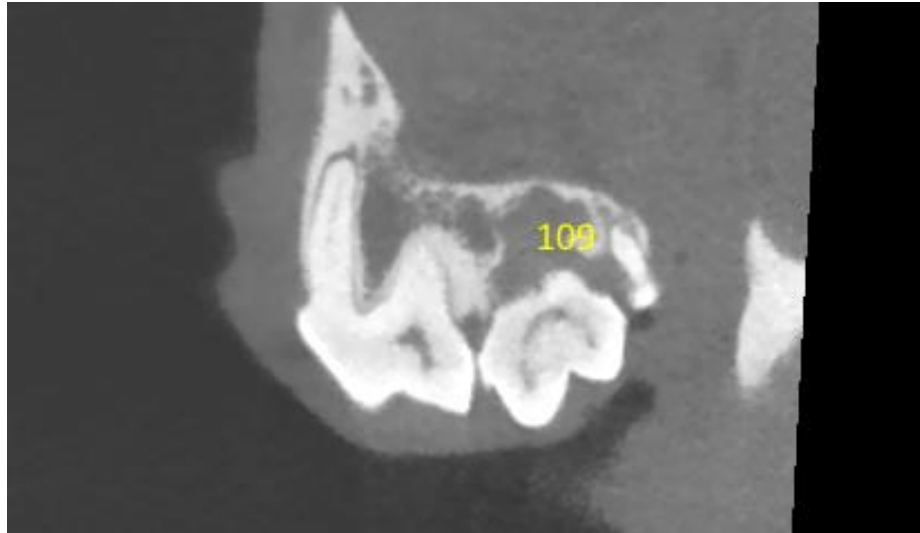
Cynthia Maro

INVOICE

56920

DATE

2-23-23



The information and recommendations provided are based on the images presented by the referring veterinarian. No evaluation can be communicated regarding pathology that was not visible in the image/video clips provided.

Thank you for this referral. If the clinical or image interpretation does not parallel your findings or if I can be of any further assistance please contact me.

Tilde Rodrigues Froes, DMV, MSc., Dr. Med.Vet., Dipl.CBraRVet
info@sonopath.com