



PATIENT

Riley Chawkins

SPECIES

Canine

BREED

Dutch Shepard

SEX

MN

AGE

15 Years

INTERPRETED BY

Tilde Rodrigues Froes,
DMV, MSc., Dr. Med
Vet., Dipl. CBraRVet

HOSPITAL NAME

Northshore
Veterinary Hospital

REFERRING VET

Brita Kiffney

INVOICE

56894

DATE

2-22-23

PRESENTING CLINICAL SIGNS

self referral by owner to our clinic for an abdominal ultrasound. Her previous veterinarian sampled a mass on the left side of thoracic inlet (6 x 8 cm) that came back suspicious of thyroid carcinoma.

Abnormal PE/Chem/CBC/UA Results: moderate elevations of ALP/ ALT from previous records 6 x 8 cm sq firm mass left thoracic inlet lack of pelvic limb proprioception mm wasting along spine and pelvic limbs

RADIOGRAPHIC STUDY OF THE THORAX

Radiographs of the thorax and collimated abdomen, in two imaging planes are provided for review totaling four images.

RADIOGRAPHIC FINDINGS

The mediastinum is unremarkable, no evidence of mass effect or widening.

The pulmonary parenchyma is normal. No evidence of opaque soft tissue nodules.

The cardiac silhouette and pulmonary vasculature are normal.

The thoracic trachea is normal.

The pleural space is normal.

The complete hepatic silhouette is visible only on the right lateral view and is normal in size, shape, and opacity.

Multifocal thoracic and thoracolumbar spondylosis deformans is noted.

Mild periarticular ossification is seen at the caudal aspect of both shoulders.

RADIOGRAPHIC DIAGNOSIS

- Normal thorax.
- No evidence of pulmonary metastatic disease.
- Multifocal thoracic and thoracolumbar spondylosis deformans.
- Incidental mild bilateral shoulder osteoarthritis.

INTERPRETATION OF THE FINDINGS & FURTHER RECOMMENDATIONS

The thoracic radiographs show low sensibility for analysis of the mediastinum. For better investigation, repeating the non-cardiac thoracic ultrasound and/or computed tomography is suggested. A cervical ultrasound is suggested for further evaluation if any increase in volume is detected. Abdominal ultrasound is suggested for further evaluation of the liver.



PATIENT

Riley Chawkins

SPECIES

Canine

BREED

Dutch Shepard

SEX

MN

AGE

15 Years

INTERPRETED BY

Tilde Rodrigues Froes,
DMV, MSc., Dr. Med
Vet., Dipl. CBraRVet

HOSPITAL NAME

Northshore
Veterinary Hospital

REFERRING VET

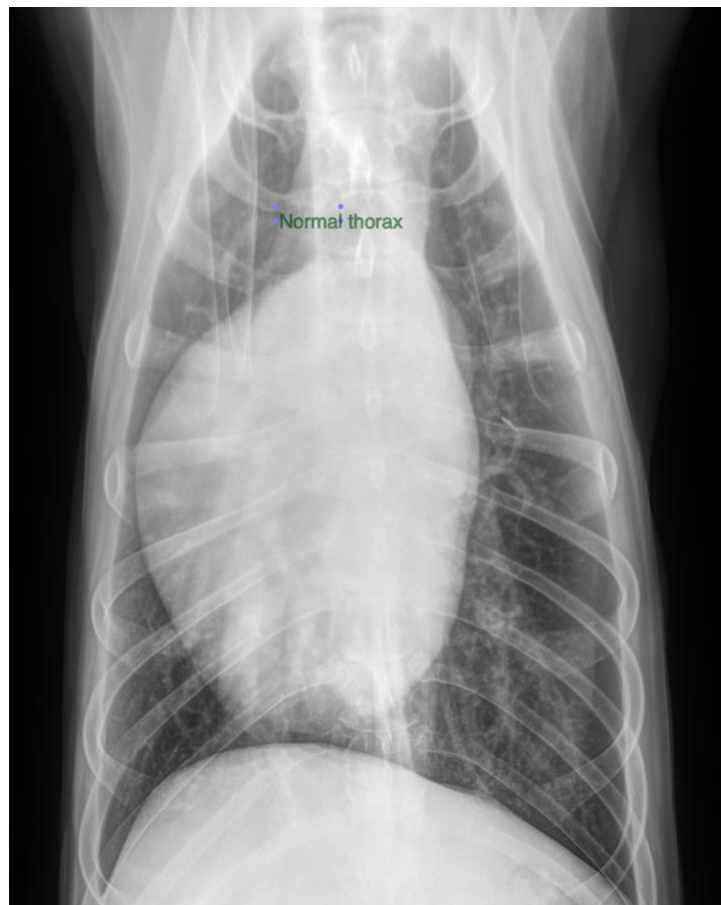
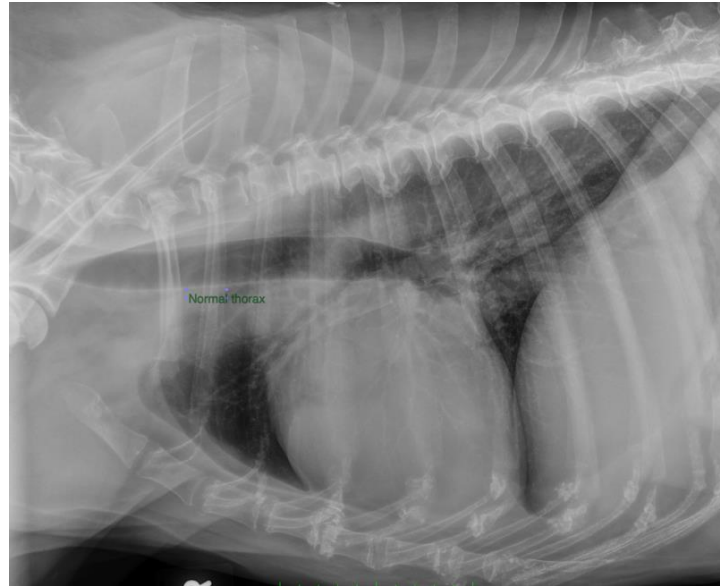
Brita Kiffney

INVOICE

56894

DATE

2-22-23





PATIENT

Riley Chawkins

SPECIES

Canine

BREED

Dutch Shepard

SEX

MN

AGE

15 Years

INTERPRETED BY

Tilde Rodrigues Froes,
DMV, MSc., Dr. Med
Vet., Dipl. CBraRVet

HOSPITAL NAME

Northshore
Veterinary Hospital

REFERRING VET

Brita Kiffney

INVOICE

56894

DATE

2-22-23

The information and recommendations provided are based on the images presented by the referring veterinarian. No evaluation can be communicated regarding pathology that was not visible in the image/video clips provided.

Thank you for this referral. If the clinical or image interpretation does not parallel your findings or if I can be of any further assistance please contact me.

Tilde Rodrigues Froes, DMV, MSc., Dr. Med.Vet., Dipl.CBraRVet
info@sonopath.com