



PATIENT PRESENTING CLINICAL SIGNS

Lima Oryshchyshyn limping on/off on left hind ~ 1 year. O thinks happened last year when p slipped on ice. Abnormal PE/Chem/CBC/UA Results: toe touching - limping lh, drawer sign not appreciated, no luxation or crepitus on exam.

SPECIES RADIOGRAPHIC STUDY OF PELVIC LIMBS & PELVIS

Canine Orthogonal views of the pelvic limbs are provided for review totaling six images. Two views of the coxofemoral joints and lumbosacral region. One craniocaudal view of the stifle joints. One view of the right stifle joint, one view of the left stifle joint.

BREED RADIOGRAPHIC FINDINGS

Lab **Left Pelvic Limb**

SEX There is articular swelling of the left stifle joint and increased volume extending caudally, medially, and cranially from normal margins, and is compressing the caudal 40% of the infrapatellar fat pad.

Female Spayed

AGE The proximal tibia is cranially translocated in relation to the distal femur.

3 Years Moderate periarticular ossification is seen at the margins of the left patella, femoral trochlear ridges, tibial condyles, femoral condyles, and sesamoids of the gastrocnemius.

The tarsocrural, tarsal, and tarsometatarsal joints are normal.

INTERPRETED BY Mild decrease in the left pelvic limb muscle mass in comparison the contralateral.

Tilde Rodrigues Froes, DMV, MSc., Dr. Med Vet., Dipl. CBraRVet

Right Pelvic Limb

The right stifle joint and fat-pad opacity are normal.

HOSPITAL NAME The tarsocrural, tarsal and tarsometatarsal joints are normal.

The Pet Hospital of Stratford

Pelvis

The coxofemoral joints and pelvis are normal.

REFERRING VET Minor L7-S1 spondylosis deformans is noted.

Dr Robert Bashkin The collimated lumbar spine is normal.

RADIOGRAPHIC DIAGNOSIS

- INVOICE**
- Left stifle joint synovial swelling, moderate secondary osteoarthritis, and subluxation are consistent with partial tear or complete rupture of the cranial cruciate ligament. Differential diagnosis includes concurrent inflammatory joint effusion.
 - Mild left pelvic limb muscle atrophy secondary to disuse.
 - L7-S1 Spondylosis deformans.
 - Normal coxofemoral joints

56893

DATE

2-22-23



PATIENT • Normal right stifle joint.

Lima Oryshchyshyn

INTERPRETATION OF THE FINDINGS & FURTHER RECOMMENDATIONS

The radiographic findings of the left stifle joint are correlated to the clinical findings of limping. Surgical consultation is suggested.

SPECIES

Canine

BREED

Lab

SEX

Female Spayed

AGE

3 Years

INTERPRETED BY

Tilde Rodrigues Froes,
DMV, MSc., Dr. Med
Vet., Dipl. CBraRVet

HOSPITAL NAME

The Pet Hospital of
Stratford

REFERRING VET

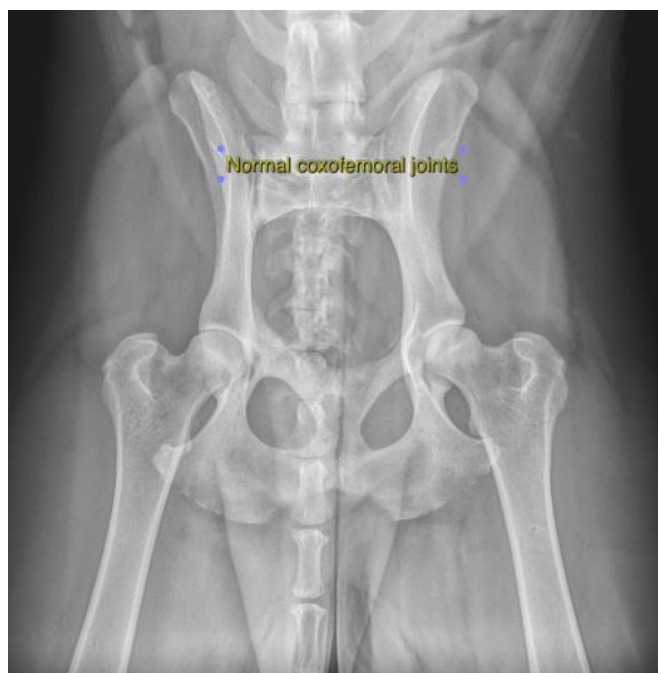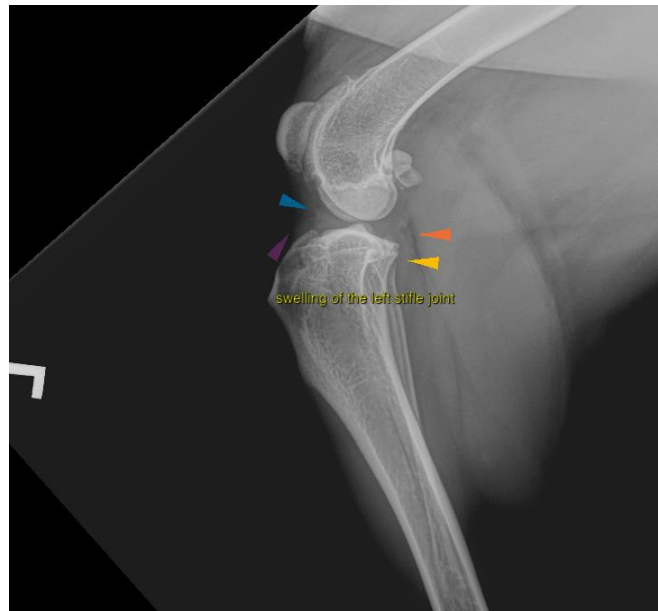
Dr Robert Bashkin

INVOICE

56893

DATE

2-22-23





PATIENT

Lima Oryshchyshyn

SPECIES

Canine

BREED

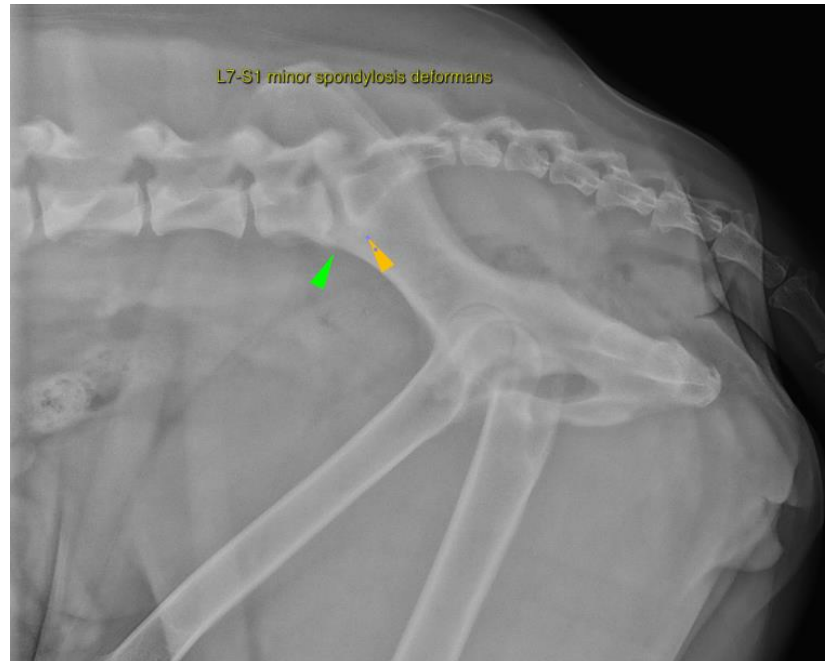
Lab

SEX

Female Spayed

AGE

3 Years



INTERPRETED BY

Tilde Rodrigues Froes,
DMV, MSc., Dr. Med
Vet., Dipl. CBraRVet

The information and recommendations provided are based on the images presented by the referring veterinarian. No evaluation can be communicated regarding pathology that was not visible in the image/video clips provided.

Thank you for this referral. If the clinical or image interpretation does not parallel your findings or if I can be of any further assistance please contact me.

HOSPITAL NAME

The Pet Hospital of
Stratford

Tilde Rodrigues Froes, DMV, MSc., Dr. Med.Vet., Dipl.CBraRVet
info@sonopath.com

REFERRING VET

Dr Robert Bashkin

INVOICE

56893

DATE

2-22-23