



PATIENT **PRESENTING CLINICAL SIGNS**

Anouk Bryson Panting excessively for 2 weeks
 Abnormal PE/Chem/CBC/UA Results: PE- unremarkable except severe matting all over the body, No wheezing/crackles over the lung fields, no heart murmur BW- moderately elevated ALT (due to chronic phenobarbital use)

SPECIES

Canine

RADIOGRAPHIC STUDY OF THE THORAX

Radiographs of the thorax in three imaging planes are provided for review. One right lateral, one left lateral, and one ventral dorsal view.

BREED

Siberian Husky

RADIOGRAPHIC FINDINGS

The trachea is normal.

SEX

The cardiac silhouette, pulmonary vasculature, and parenchyma are normal.

Female Spayed

The pleural space and mediastinum are normal.

AGE

11 Years

There is dorsal deviation of the fourth sternbrae and subluxation of the 4th-5th intersternbral synchondroses.

A lenticular homogenously fat opaque subcutaneous mass within the right thoracic body wall, measuring 8.7cm x 2.2cm, is seen.

INTERPRETED BY

The remainder thoracic wall and ribs are normal.

The collimated cranial abdomen is normal.

Tilde Rodrigues Froes,
 DMV, MSc., Dr. Med
 Vet., Dipl. CBraRVet

RADIOGRAPHIC DIAGNOSIS

- Normal thorax.
- Mild dorsal deviation of the sternum and subluxation of the 4th -5th sternbrae, differential diagnosis includes previous trauma or congenital malformation.
- Right thoracic body wall lipoma.

HOSPITAL NAME

St. Catherine's Animal
 Hospital

INTERPRETATION OF THE FINDINGS & FURTHER RECOMMENDATIONS

Normal radiographic pulmonary parenchyma, pulmonary vasculature, and cardiovascular system.

REFERRING VET

Dr. Jui Gokhale

The collimated abdomen is normal; however, the hepatic border is not collimated on the field. Considerer an abdominal ultrasound for further evaluation of the hepatic parenchyma because of the increased ALT values, if persistent.

INVOICE

56861

DATE

2-21-23



PATIENT

Anouk Bryson

SPECIES

Canine

BREED

Siberian Husky

SEX

Female Spayed

AGE

11 Years

INTERPRETED BY

Tilde Rodrigues Froes,
DMV, MSc., Dr. Med
Vet., Dipl. CBraRVet

HOSPITAL NAME

St. Catherine's Animal
Hospital

REFERRING VET

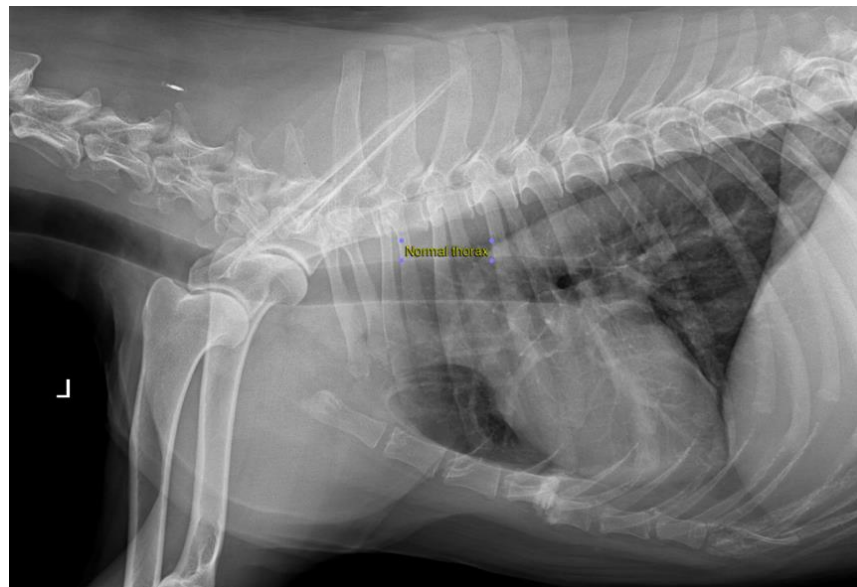
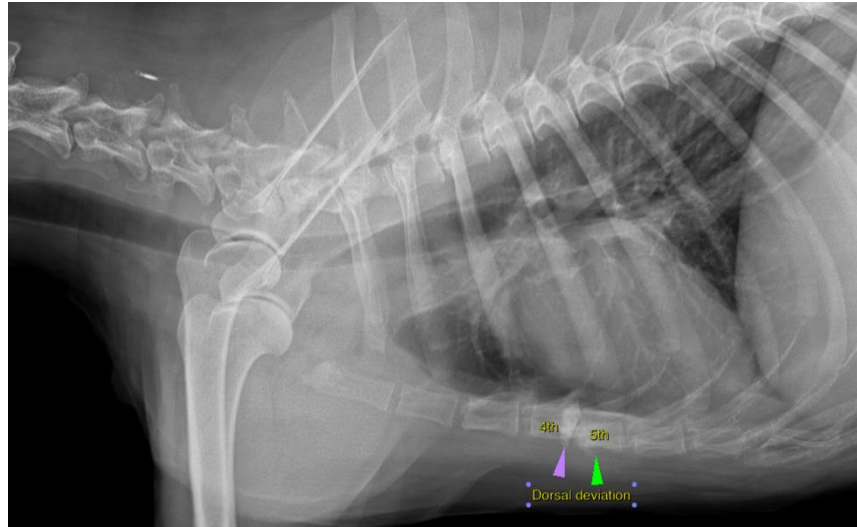
Dr. Jui Gokhale

INVOICE

56861

DATE

2-21-23





PATIENT

Anouk Bryson

SPECIES

Canine

BREED

Siberian Husky

SEX

Female Spayed

AGE

11 Years

INTERPRETED BY

Tilde Rodrigues Froes,
DMV, MSc., Dr. Med
Vet., Dipl. CBraRVet

HOSPITAL NAME

St. Catherine's Animal
Hospital

REFERRING VET

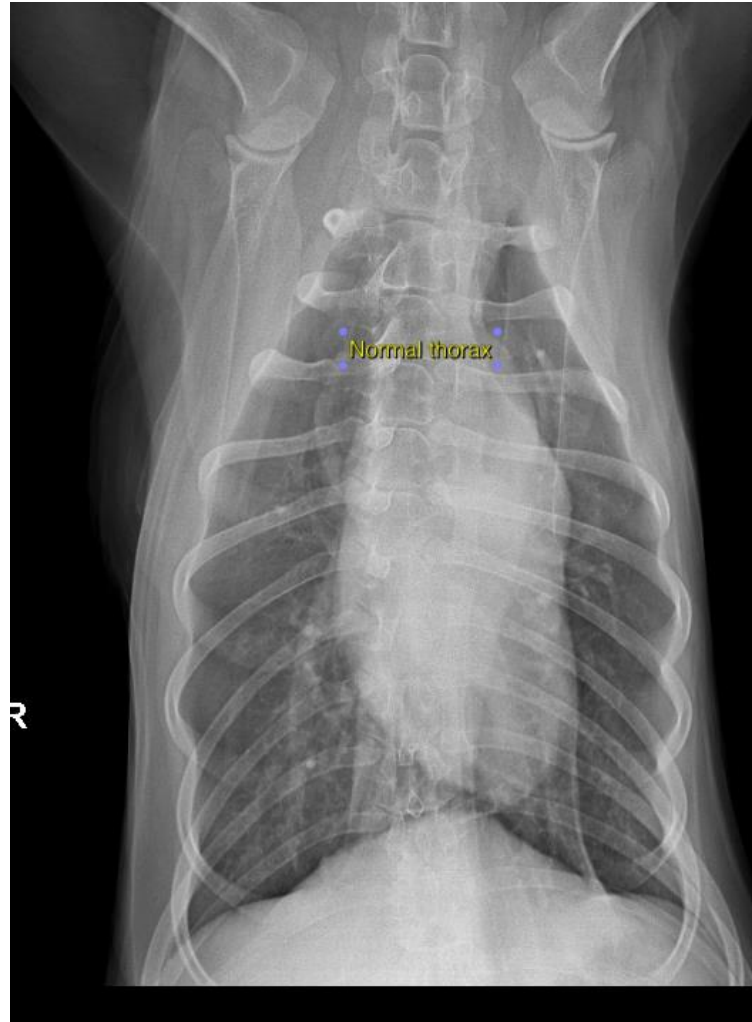
Dr. Jui Gokhale

INVOICE

56861

DATE

2-21-23



The information and recommendations provided are based on the images presented by the referring veterinarian. No evaluation can be communicated regarding pathology that was not visible in the image/video clips provided.

Thank you for this referral. If the clinical or image interpretation does not parallel your findings or if I can be of any further assistance please contact me.

Tilde Rodrigues Froes, DMV, MSc., Dr. Med.Vet., Dipl.CBraRVet
info@sonopath.com