



**PATIENT PRESENTING CLINICAL SIGNS**

Zeak Schuldts Surgical planning for oral osteosarcoma

**SPECIES**

Canine

**COMPUTED TOMOGRAPHIC STUDY OF THE HEAD AND CERVICAL SOFT TISSUE**

A pre- and post-contrast CT study of the head and cervical soft tissue are provided for review. One pre-contrast series of head, one post-contrast series of the head, and one post-contrast series of the thorax.

**BREED**

Weimaraner

**COMPUTED TOMOGRAPHIC FINDINGS**

Centered on the right side of the mandibular body and ramus is a mixed osteolytic and osteoproliferative lesion with moderate extension of length and indistinct zone transition. Due to the extension of the lesion, the masseteric fossa is also involved. However, a small portion of the mandible near the notch is preserved. The temporomandibular joint is intact. The distance of the lesion through the temporomandibular joint is approximately 2.6cm.

**SEX**

Neutered Male

In the body of the mandible, the lesion measures approximately 5.5cm x 2.3cm x 2.4cm, and in the ramus, the lesion measures at least 2.3cm x 1.6cm. Due to the bone lesion in the mandibular body, the 2nd and 3rd mandibular molar teeth (410, 411) are absent; however, the adjacent 1st molar teeth (409) is present and contiguous to the described zone transition bone lesion.

**AGE**

12 Years, 11 Months

Other face and cranial bones are preserved.

The 308 mandibular tooth is absent. All other teeth are presents.

**INTERPRETED BY**

Tilde Rodrigues Froes, DMV, MSc., Dr. Med Vet., Dipl. CBraRVet

The temporomandibular joints are bilaterally incongruent.

The right retropharyngeal lymph node is severely enlarged, rounded in shape, and heterogeneous, with multiple pinpoint calcifications, centrally streaky, and measures approximately 3.0cm x 2.5cm in diameter. The right mandibular lymph nodes are also enlarged. The largest measures approximately 2.8cm x 1.6cm and they are very asymmetrical in comparison to the contralateral.

**HOSPITAL NAME**

Mobile Pet Imaging

The nasal cavities are normal.

The tympanic cavities and osseous bulla are normal.

**REFERRING VET**

Meaux

The retrobulbar spaces are normal.

The brain is normal, no mass effect is seen.

**INVOICE**

56544

The calvarium is dome-shaped and the frontal sinuses are normal.

No other abnormalities are identified.

**COMPUTED TOMOGRAPHIC DIAGNOSIS**

**DATE**

2-2-23

- Monostotic aggressive mixed osteolytic and proliferative lesion of the right mandibular ramus and body consistent with neoplasia such as primary tumor of bone, osteosarcoma.
- Absent triadan 410 and 411, correlated to the mandibular bone lesion.



- PATIENT** Zeak Schuldts
- Absent triadan 308.
  - Right retropharyngeal lymphadenopathy is consistent with metastatic disease
  - Right mandibular enlarged lymphadenopathy, metastatic or reactive.

**INTERPRETATION OF THE FINDINGS & FURTHER RECOMMENDATIONS**

**SPECIES** Canine  
The right sided mandibular (ramus and body) monostotic lesion is extensive. The resectability is difficult because of the surgical safety margins unless the temporomandibular joint resection is considered together.

**BREED** Weimaraner  
Metastatic lesion is seen at the right retropharyngeal lymph node and possible mandibular lymph nodes.

**SEX** Neutered Male  
Three view thoracic radiographs may be useful in evaluating for evidence of pulmonary metastatic disease.

**AGE**

12 Years, 11 Months

**INTERPRETED BY**

Tilde Rodrigues Froes,  
DMV, MSc., Dr. Med  
Vet., Dipl. CBraRVet

**HOSPITAL NAME**

Mobile Pet Imaging

**REFERRING VET**

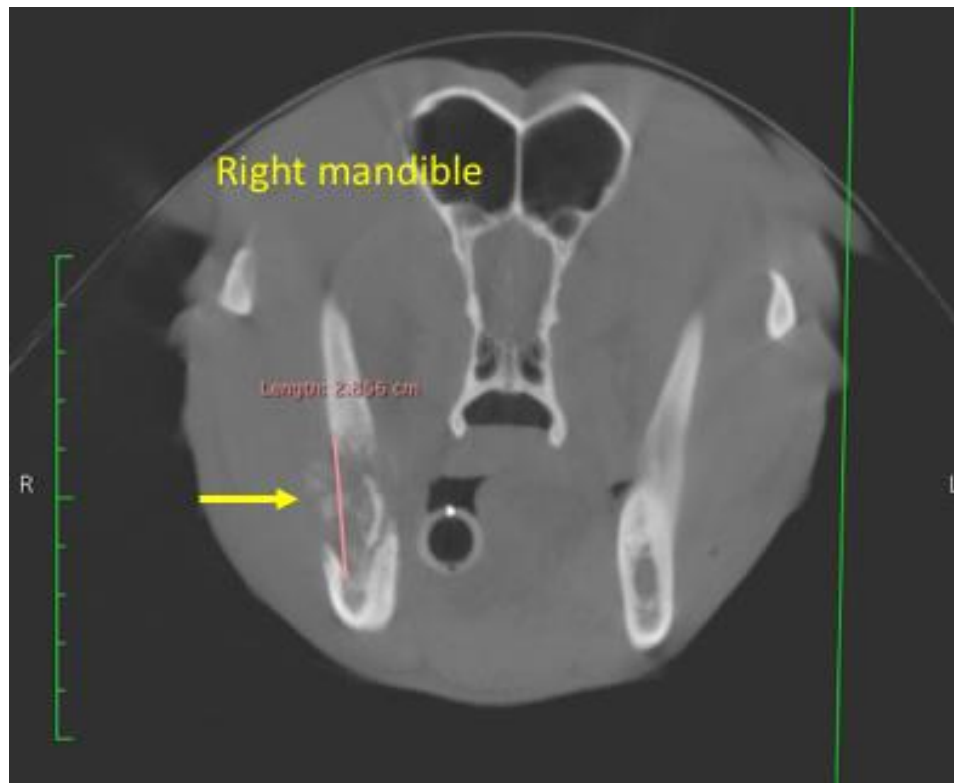
Meaux

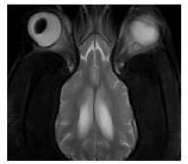
**INVOICE**

56544

**DATE**

2-2-23





**PATIENT**

Zeak Schuldts

**SPECIES**

Canine

**BREED**

Weimaraner

**SEX**

Neutered Male

**AGE**

12 Years, 11 Months

**INTERPRETED BY**

Tilde Rodrigues Froes,  
DMV, MSc., Dr. Med  
Vet., Dipl. CBraRVet

**HOSPITAL NAME**

Mobile Pet Imaging

**REFERRING VET**

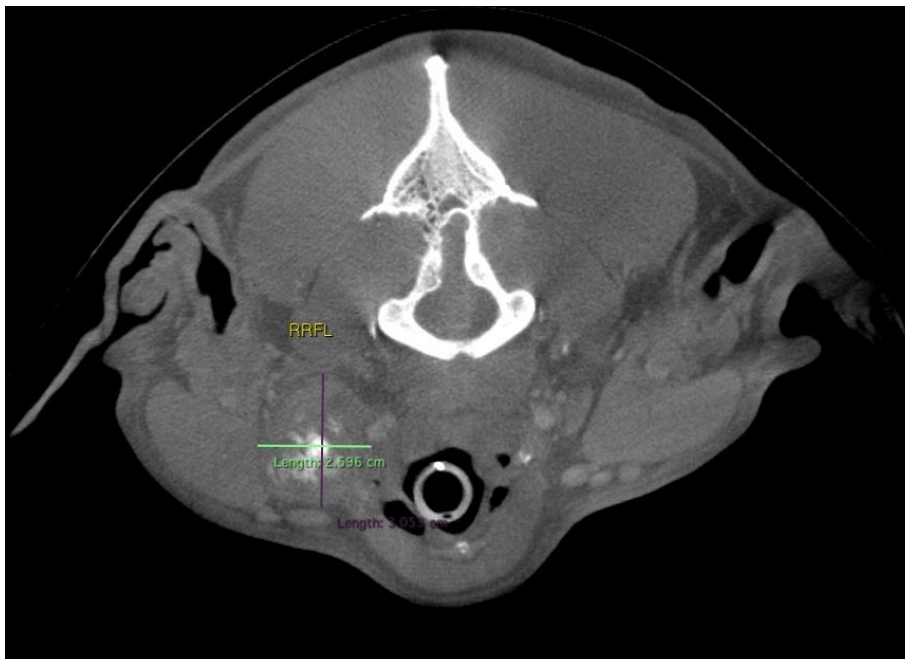
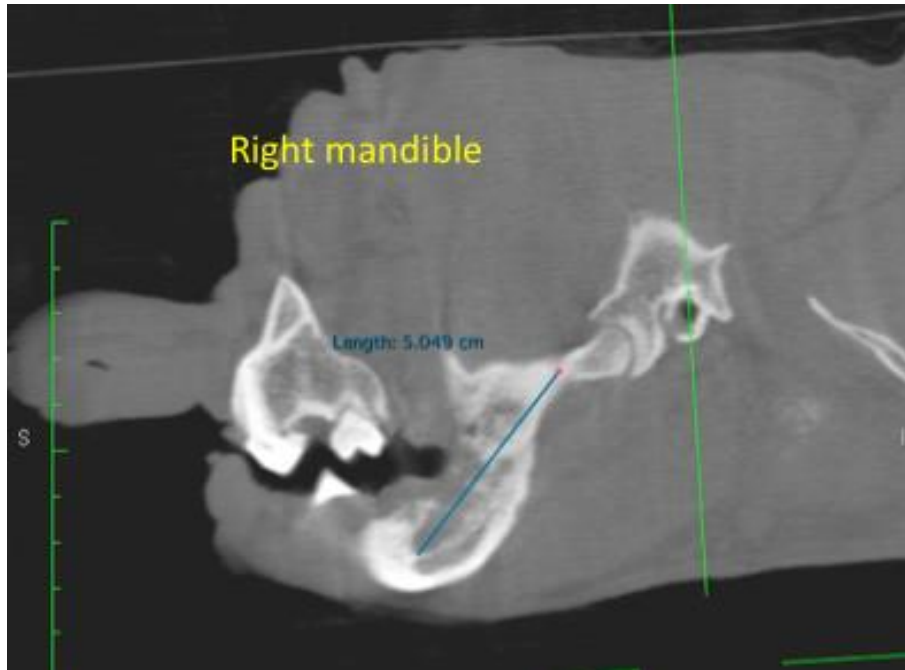
Meaux

**INVOICE**

56544

**DATE**

2-2-23





**PATIENT**

Zeak Schuldts

**SPECIES**

Canine

**BREED**

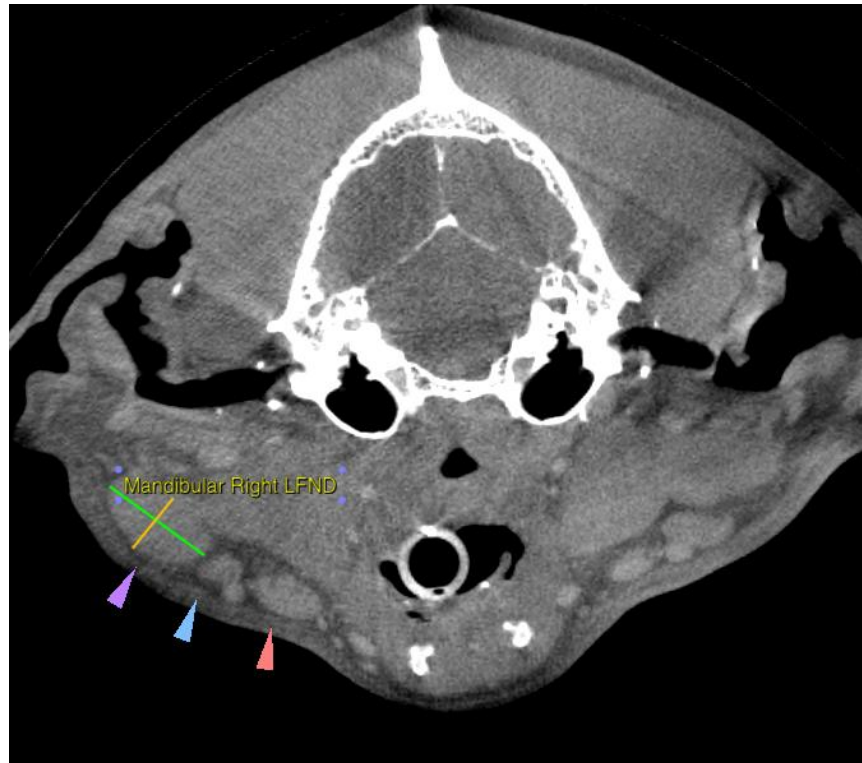
Weimaraner

**SEX**

Neutered Male

**AGE**

12 Years, 11 Months



**INTERPRETED BY**

Tilde Rodrigues Froes,  
DMV, MSc., Dr. Med  
Vet., Dipl. CBraRVet

The information and recommendations provided are based on the images presented by the referring veterinarian. No evaluation can be communicated regarding pathology that was not visible in the image/video clips provided.

**HOSPITAL NAME**

Mobile Pet Imaging

Thank you for this referral. If the clinical or image interpretation does not parallel your findings or if I can be of any further assistance please contact me.

**REFERRING VET**

Meaux

**Tilde Rodrigues Froes, DMV, MSc., Dr. Med.Vet., Dipl.CBraRVet**  
info@sonopath.com

**INVOICE**

56544

**DATE**

2-2-23