



PATIENT PRESENTING CLINICAL SIGNS

PATIENT Oliver Kostiuk
PRESENTING CLINICAL SIGNS Lethargic, vomited 20 times, anorexia, severe dehydration, increased UREA and ALP, abnormal cPLi, monocytosis. Contrast given rectally yesterday, to see the outline of the colon. Please assess. Considering ex-lap for foreign body or tumor.

SPECIES Abnormal PE/Chem/CBC/UA Results: Severe dehydration, increased UREA, increased ALP, monocytosis, abnormal cPLi.

Canine

RADIOGRAPHIC STUDY OF THE ABDOMEN AND COLLIMATED THORAX

BREED

Orthogonal views of the abdomen and collimated thorax are available for review totaling 3 images. A barium enema is visible in all three images. (Barium enema series at 12:51pm, 12:52pm and 12:53pm, contrast given yesterday according to history).

Lhasa Apso

RADIOGRAPHIC FINDINGS

SEX

Cranial abdominal serosal detail is reduced between the stomach and transverse colon, at the 11th through 13th intercostal spaces, on the right and left pancreas location, however, more on the right side. More central abdominal serosal detail is also reduced within wispy soft tissue opaque material interspersed in the small intestines.

MN

AGE

The stomach contains a moderate amount of gas and soft-tissue opacity, which redistributes normally with changes in patient position.

10 Years

The small intestines are normally distributed, of normal diameter, contain a small amount of gas, and homogeneous soft tissue fluid material.

INTERPRETED BY

No evidence of radiopaque foreign material or mechanical gastrointestinal obstruction.

Tilde Rodrigues Froes, DMV, MSc., Dr. Med Vet., Dipl. CBraRVet

The descending colon is filled with contrast media and mildly ventrally dislocated. Mild mucosal/wall irregularities are seen, especially in the end portion, near the rectum. However, a clear filling defect is not seen.

HOSPITAL NAME

The liver, spleen, and renal silhouettes are normal.

Windermere Veterinary Hospital

The urinary bladder is moderately distended, with the apex in the plane of L5, and is homogeneously soft tissue opaque.

The prostate is not visible which is normal in castrated dogs.

REFERRING VET

The visible portion of the cardiac silhouette, pulmonary parenchyma, and pulmonary vessels are normal.

Dr. Sherif Boctor

The skeletal structures are unremarkable.

INVOICE

No other abnormalities are identified.

56734

DATE

2-14-23



PATIENT **RADIOGRAPHIC DIAGNOSIS**

Oliver Kostiuk

- Reduced abdominal serosal detail especially more cranially and ventral, differential diagnosis includes regional peritonitis and pancreatitis, less likely technical artifact.
- Consider concurrent nonobstructive gastroenteritis and colitis.
- Scant peritoneal effusion, for example transudate, or inflammatory.
- No signs of mechanical gastrointestinal obstruction or radiopaque foreign material.
- Mucosal wall irregularities in the descending colon, differential diagnosis includes colitis, or artifact, less likely infiltrative wall disease.
- Normal collimated thorax.

SPECIES

Canine

BREED

Lhasa Apso

INTERPRETATION OF THE FINDINGS & FURTHER RECOMMENDATIONS

No radiographic signs of mechanical gastrointestinal obstruction or radiopaque foreign material are seen. The radiographic signs of peritonitis and pancreatitis correlate to the laboratory findings. An abdominal ultrasound may be useful to evaluate the pancreatic region and cranial abdomen, also for better analysis of the colonic wall including wall layering and thickness.

SEX

MN

AGE

10 Years

INTERPRETED BY

Tilde Rodrigues Froes,
DMV, MSc., Dr. Med
Vet., Dipl. CBraRVet

HOSPITAL NAME

Windermere
Veterinary Hospital

REFERRING VET

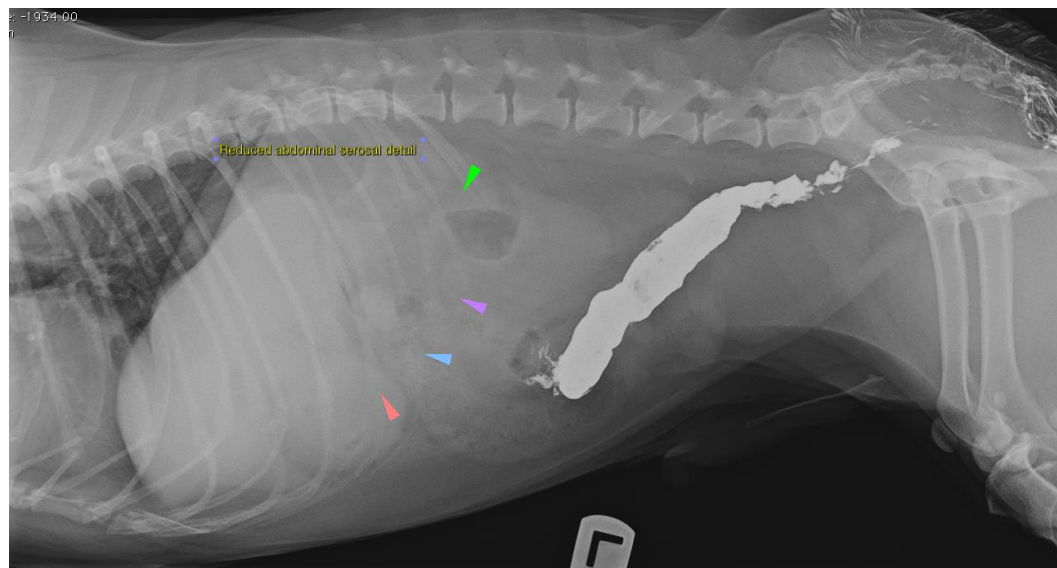
Dr. Sherif Boctor

INVOICE

56734

DATE

2-14-23





PATIENT

Oliver Kostiuk

SPECIES

Canine

BREED

Lhasa Apso

SEX

MN

AGE

10 Years

INTERPRETED BY

Tilde Rodrigues Froes,
DMV, MSc., Dr. Med
Vet., Dipl. CBraRVet

HOSPITAL NAME

Windermere
Veterinary Hospital

REFERRING VET

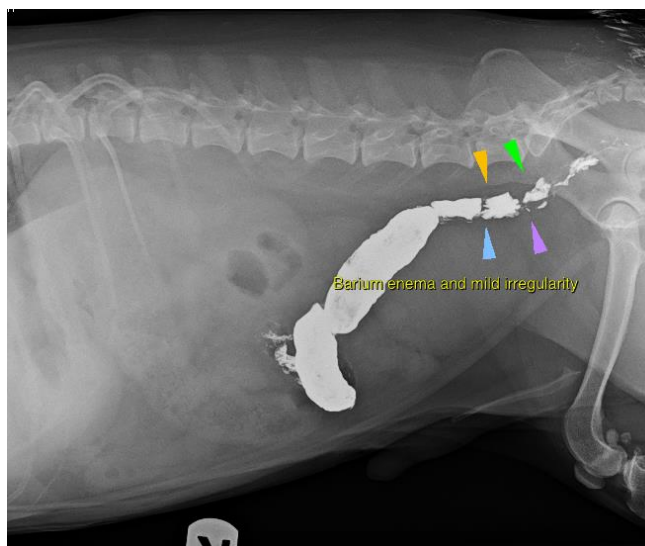
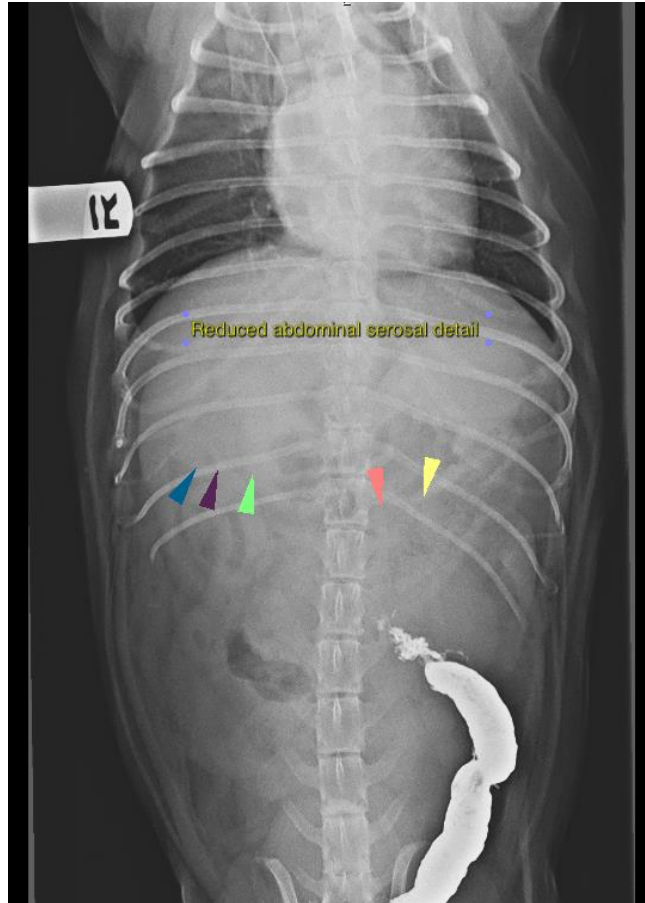
Dr. Sherif Boctor

INVOICE

56734

DATE

2-14-23





PATIENT

Oliver Kostiuk

The information and recommendations provided are based on the images presented by the referring veterinarian. No evaluation can be communicated regarding pathology that was not visible in the image/video clips provided.

SPECIES

Canine

Thank you for this referral. If the clinical or image interpretation does not parallel your findings or if I can be of any further assistance please contact me.

BREED

Lhasa Apso

Tilde Rodrigues Froes, DMV, MSc., Dr. Med.Vet., Dipl.CBraRVet
info@sonopath.com

SEX

MN

AGE

10 Years

INTERPRETED BY

Tilde Rodrigues Froes,
DMV, MSc., Dr. Med
Vet., Dipl. CBraRVet

HOSPITAL NAME

Windermere
Veterinary Hospital

REFERRING VET

Dr. Sherif Boctor

INVOICE

56734

DATE

2-14-23