



PATIENT

Diablo Aguilar

PRESENTING CLINICAL SIGNS

Reduced appetite and foaming at mouth for one day

SPECIES

Canine

RADIOGRAPHIC STUDY OF THE ABDOMEN AND COLLIMATED THORAX

Orthogonal views of the abdomen and collimated thorax are available for review totaling 6 images.

RADIOGRAPHIC FINDINGS

BREED

Doberman Pinscher

The stomach is severely distended with gas admixed with homogeneous soft tissue opaque fluid material. The pylorus is cranially and dorsally displaced.

SEX

Male Neuter

The spleen is enlarged and abnormally positioned in the ventral cranial abdomen and the mesenteric margins are mildly poorly defined due to increase in soft tissue/fluid opacity. The small intestine are displaced caudally and distended with gas.

The visible portion of the esophagus is diffusely and abnormally dilated with gas.

AGE

11 Years

The caudal vena cava peripheral pulmonary vessels included in the collimated field of view are attenuated.

The urinary bladder is mildly distended, with the apex in the plane of L7, and is homogeneously soft tissue opaque.

INTERPRETED BY

Tilde Rodrigues Froes, DMV, MSc., Dr. Med Vet., Dipl. CBraRVet

RADIOGRAPHIC DIAGNOSIS

- Radiographic findings are most consistent with gastric dilatation and volvulus with concurrent splenic displacement and congestion or small volume of hemorrhagic effusion.
- Diffuse gas dilated small intestine are likely secondary to gastric dilatation and volvulus.
- Small caudal vena cava, differential diagnosis includes dehydration and hypovolemia.
- Esophageal reflux and aerophagia.

HOSPITAL NAME

St. Catherine's Animal Hospital

INTERPRETATION OF THE FINDINGS & FURTHER RECOMMENDATIONS

Radiographic signs of gastric dilatation and volvulus. Concurrent splenic torsion should be considered. Surgery is recommended. Consider gastric tube placement or trocarisation prior to exploratory laparotomy.

REFERRING VET

Dr. Boctor

INVOICE

56724

DATE

2-14-23



PATIENT

Diablo Aguilar

SPECIES

Canine

BREED

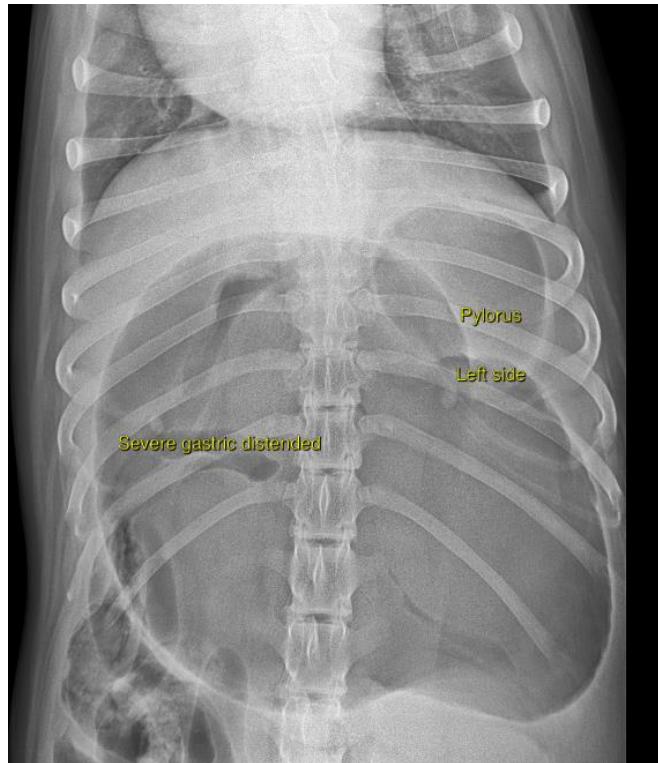
Doberman Pinscher

SEX

Male Neuter

AGE

11 Years



INTERPRETED BY

Tilde Rodrigues Froes,
DMV, MSc., Dr. Med
Vet., Dipl. CBraRVet

HOSPITAL NAME

St. Catherine's Animal
Hospital

REFERRING VET

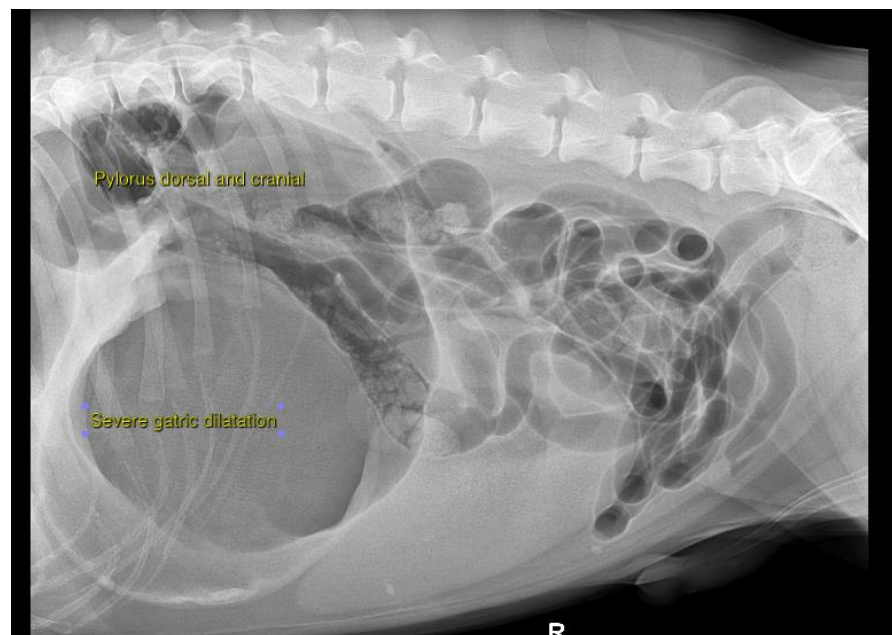
Dr. Boctor

INVOICE

56724

DATE

2-14-23





PATIENT

Diablo Aguilar

The information and recommendations provided are based on the images presented by the referring veterinarian. No evaluation can be communicated regarding pathology that was not visible in the image/video clips provided.

SPECIES

Canine

Thank you for this referral. If the clinical or image interpretation does not parallel your findings or if I can be of any further assistance please contact me.

BREED

Doberman Pinscher

Tilde Rodrigues Froes, DMV, MSc., Dr. Med.Vet., Dipl.CBraRVet
info@sonopath.com

SEX

Male Neuter

AGE

11 Years

INTERPRETED BY

Tilde Rodrigues Froes,
DMV, MSc., Dr. Med
Vet., Dipl. CBraRVet

HOSPITAL NAME

St. Catherine's Animal
Hospital

REFERRING VET

Dr. Boctor

INVOICE

56724

DATE

2-14-23