



## PATIENT

Mahina Beck

## SPECIES

Canine

## BREED

Australian Shepherd

## SEX

F

## AGE

10M

## WEIGHT

20lbs

## INTERPRETED BY

Tilde Rodrigues Froes,  
DMV, MSc., Dr. Med  
Vet., Dipl. CBraRVet

## IMAGING PERFORMED BY

Tina Lynn,  
CVT/George  
Eales, DVM

## HOSPITAL NAME

Green Prairie Animal  
Hospital

## REFERRING VET

Myers Animal Clinic-  
Dr. Myers

## INVOICE

73722

## DATE

2-10-26

## PRESENTING CLINICAL SIGNS

- Limping on RF
- Rads showed possible fragmented coronoid process

## COMPUTED TOMOGRAPHIC STUDY OF THE THORACIC LIMBS – ELBOW JOINTS

A single non-contrast computed tomographic examination of the elbow joints is provided for review, acquired in the transverse plane using a bone algorithm.

## COMPUTED TOMOGRAPHIC FINDINGS

### Right Shoulder & Elbow Joint

The medial coronoid process of the ulna demonstrates focal hypoattenuation with suspected fissure line.

On dorsal and sagittal multiplanar reformatted images, the humeroulnar and humeroradial articulations are congruent.

The anconeal process and trochlear notch are unremarkable.

No periarticular osteophytes or subchondral sclerosis are identified.

The humeral condyles exhibit normal morphology and attenuation.

### Left Elbow Joint

The medial coronoid process is within normal limits.

On dorsal and sagittal reformatted images, the humeroulnar and humeroradial joints are congruent.

The anconeal process and trochlear notch are unremarkable.

The humeral condyles demonstrate normal morphology and attenuation.

## COMPUTED TOMOGRAPHIC DIAGNOSIS

- Right medial coronoid process hypoattenuation with suspected fissure line. Primary differential diagnosis includes medial compartmental syndrome (medial coronoid disease).
- Left elbow joint within normal limits.

## INTERPRETATION OF THE FINDINGS & FURTHER RECOMMENDATIONS

The tomographic findings of the right elbow are most consistent with early compartmental syndrome-medial coronoid disease, characterized by focal hypoattenuation and suspected fissuring of the medial coronoid process.

There is no current evidence of secondary osteoarthritis, suggesting an early-stage process.

Orthopedic consultation is recommended to better define the subsequent therapeutic options.



## PATIENT

Mahina Beck

## SPECIES

Canine

## BREED

Australian Shepherd

## SEX

F

## AGE

10M

## WEIGHT

20lbs

## INTERPRETED BY

Tilde Rodrigues Froes,  
DMV, MSc., Dr. Med  
Vet., Dipl. CBraRVet

## IMAGING PERFORMED BY

Tina Lynn,  
CVT/George  
Eales, DVM

## HOSPITAL NAME

Green Prairie Animal  
Hospital

## REFERRING VET

Myers Animal Clinic-  
Dr. Myers

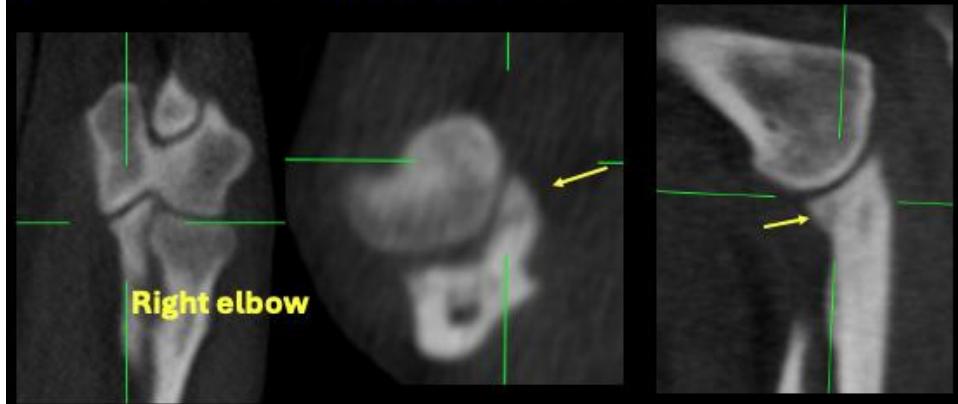
## INVOICE

73722

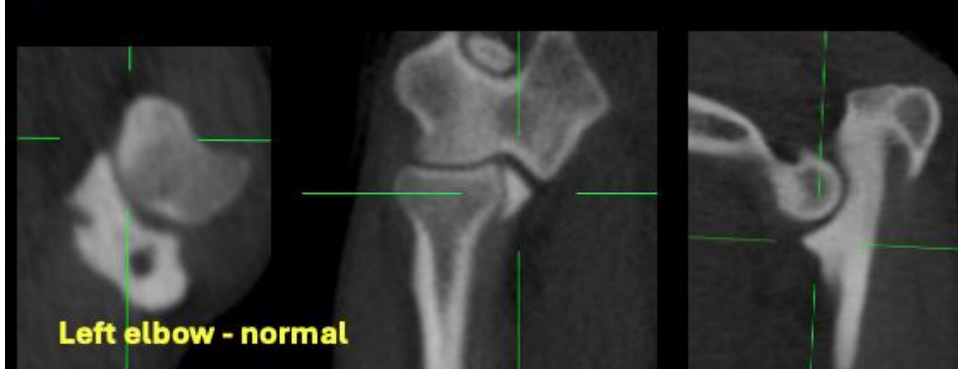## DATE

2-10-26

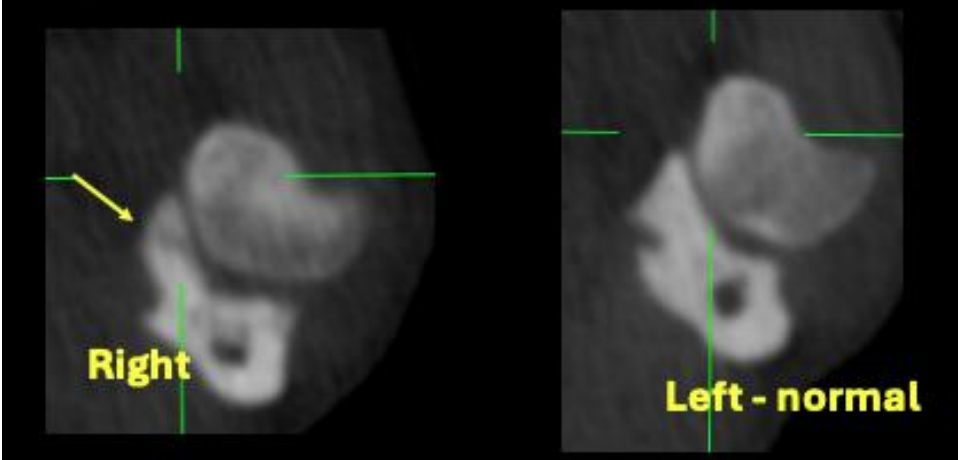
### Right medial coronoid process hypoattenuation with suspected fissure line



### Left elbow



### Right medial coronoid process hypoattenuation with suspected fissure line





## PATIENT

Mahina Beck

## SPECIES

Canine

## BREED

Australian Shepherd

## SEX

F

## AGE

10M

## WEIGHT

20lbs

## INTERPRETED BY

Tilde Rodrigues Froes,  
DMV, MSc., Dr. Med  
Vet., Dipl. CBraRVet

## IMAGING PERFORMED BY

Tina Lynn,  
CVT/George  
Eales,DVM

## HOSPITAL NAME

Green Prairie Animal  
Hospital

## REFERRING VET

Myers Animal Clinic-  
Dr. Myers

## INVOICE

73722

## DATE

2-10-26

The information and recommendations provided are based on the images presented by the referring veterinarian. No evaluation can be communicated regarding pathology that was not visible in the image/video clips provided.

Thank you for this referral. If the clinical or image interpretation does not parallel your findings or if I can be of any further assistance, please contact me.

**Tilde Rodrigues Froes, DMV, MSc., Dr. Med.Vet., Dipl.CBraRVet**  
[info@sonopath.com](mailto:info@sonopath.com)