



PATIENT PRESENTING CLINICAL SIGNS

Rixiemar Baez Patient has a chronic history of sneezing and nasal discharge(>2yrs) on well as GI problems also for >2yrs. Rhinoscopy performed on 8/25/2022 did not evidence of major abnormalities. Heart murmur II/VI recently discovered.

SPECIES Abnormal PE/Chem/CBC/UA Results: CBC --- mild thrombocytosis CHEM --- BUN mild increased

Canine

COMPUTED TOMOGRAPHIC STUDY OF THE SKULL

A pre and post-contrast head CT is provided for review. One pre-contrast series and one post-contrast series.

BREED

Dachshund

COMPUTED TOMOGRAPHIC FINDINGS

Head

SEX There is moderate to severe, more rostral and ventral, destruction and disruption of the nasal turbinates. There is diffuse mucosal thickening of the remaining nasal turbinates. The lesion is bilateral, however, more evident at the left side.

SF

AGE

Minor ventrally accumulated hypoattenuating fluid material is noted more rostrally within both nasal cavities. No mass effect is seen in the nasal cavities.

15 Years

Moderate to severe horizontal and vertical bone loss is seen throughout maxillary and mandibular arcades (> maxillary). A geographic lesion is evident adjacent to the tooth roots of the 103, 203 maxillary incisors, 104, 204 maxillary canines, 108, 208 maxillary premolars. The 105 and 206 maxillary premolars are absent.

INTERPRETED BY

Tilde Rodrigues Froes, DMV, MSc., Dr. Med Vet., Dipl. CBraRVet

A multifocal osteolysis is seen at the incisive bone, palatine process, and adjacent to the incisive maxillary canal bilaterally.

The cribriform plate is intact. The frontal sinuses are normal.

HOSPITAL NAME

Veterinary Image Center

The bulla, pharynx, and larynx are normal.

The retrobulbar spaces and globes are intact.

The temporomandibular joints are bilaterally congruent.

REFERRING VET

Dr. V. Collazo, DVM

The medial retropharyngeal and mandibular lymph nodes are normal.

COMPUTED TOMOGRAPHIC DIAGNOSIS

INVOICE

56513

DATE

2-1-23

- Bilateral, (>left side), destructive rhinitis. Differential diagnosis includes lymphoplasmacytic rhinitis, fungal rhinitis, chronic viral, and/or bacterial.
- Concurrent minor ventral fluid accumulation within both nasal cavities.
- Severe diffuse periodontal disease, more exacerbated adjacent to the maxillary incisive and canine teeth, with oronasal fistulae at the triadans 103, 104 and 204, which likely contribute to and/or cause the severity of the nasal disease. Concomitant maxillary osteomyelitis should also be considered.
- No nasal mass effect is seen.



PATIENT

Rixiemar Baez

SPECIES

Canine

BREED

Dachshund

SEX

SF

AGE

15 Years

INTERPRETED BY

Tilde Rodrigues Froes,
DMV, MSc., Dr. Med
Vet., Dipl. CBraRVet

HOSPITAL NAME

Veterinary Image
Center

REFERRING VET

Dr. V. Collazo, DVM

INVOICE

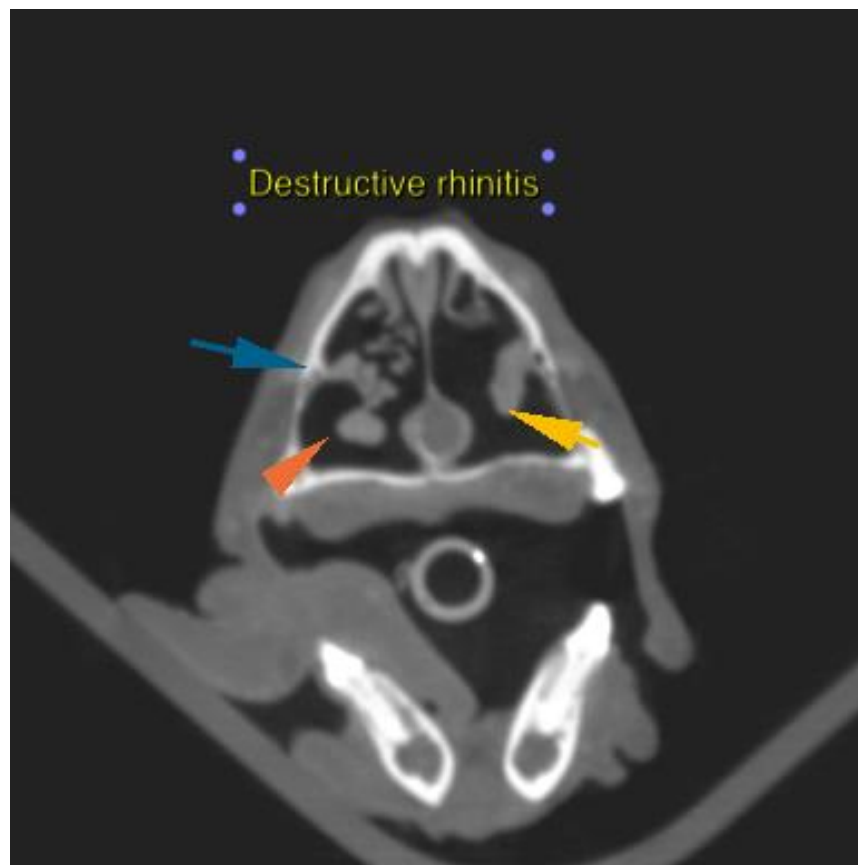
56513

DATE

2-1-23

INTERPRETATION OF THE FINDINGS & FURTHER RECOMMENDATIONS

The destructive rhinitis could be correlated to severe periodontal disease. As previously mentioned, an oronasal fistula should be considered adjacent to the incisive and canine teeth. Correlation with oral/dental exam is suggested. Also consider a therapeutic dental procedure to add and improve the rhinitis treatment. Nasal flush biopsy is suggested for confirmation.





PATIENT

Rixiemar Baez

SPECIES

Canine

BREED

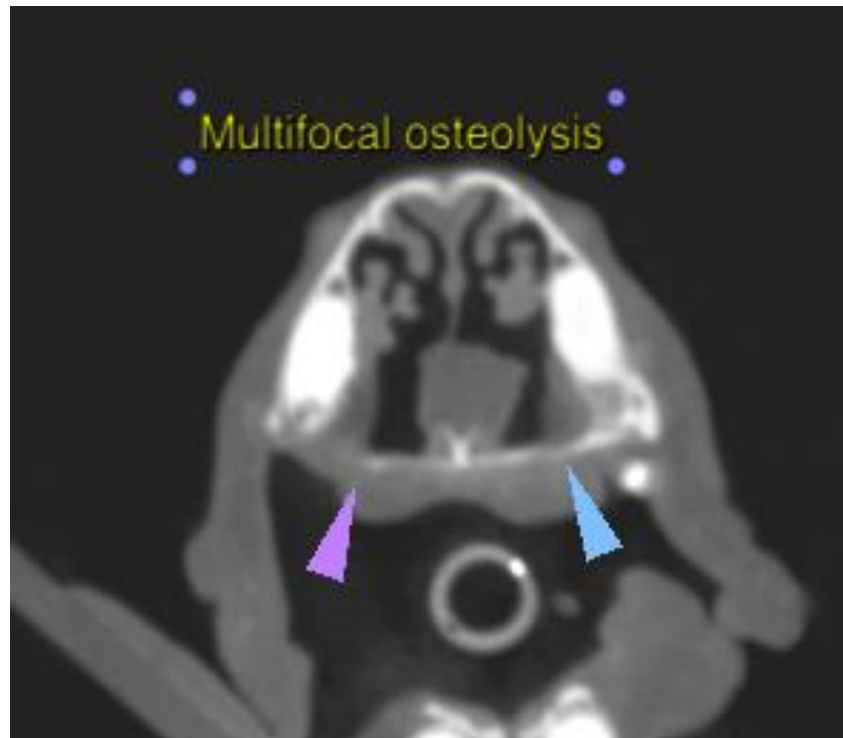
Dachshund

SEX

SF

AGE

15 Years



INTERPRETED BY

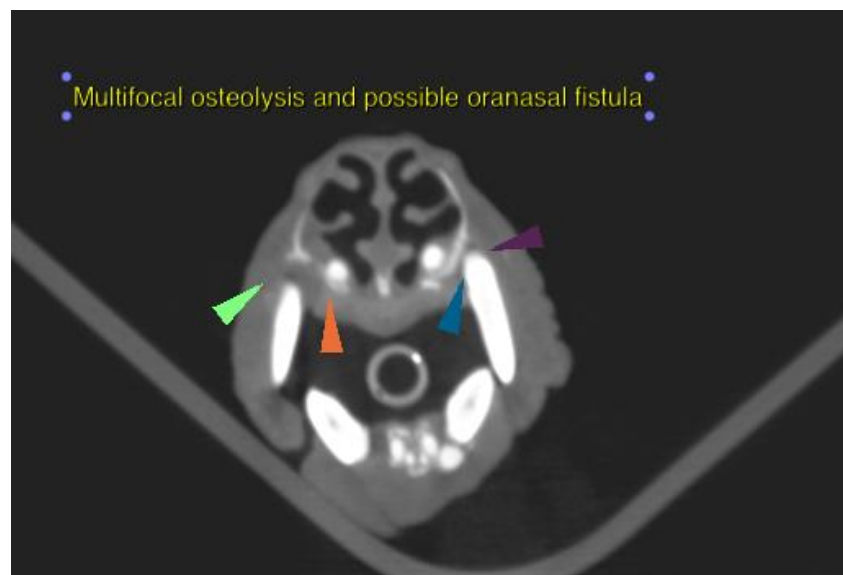
Tilde Rodrigues Froes,
DMV, MSc., Dr. Med
Vet., Dipl. CBraRVet

HOSPITAL NAME

Veterinary Image
Center

REFERRING VET

Dr. V. Collazo, DVM



INVOICE

56513

DATE

2-1-23



PATIENT

Rixiemar Baez

The information and recommendations provided are based on the images presented by the referring veterinarian. No evaluation can be communicated regarding pathology that was not visible in the image/video clips provided.

SPECIES

Canine

Thank you for this referral. If the clinical or image interpretation does not parallel your findings or if I can be of any further assistance please contact me.

BREED

Dachshund

Tilde Rodrigues Froes, DMV, MSc., Dr. Med.Vet., Dipl.CBraRVet
info@sonopath.com

SEX

SF

AGE

15 Years

INTERPRETED BY

Tilde Rodrigues Froes,
DMV, MSc., Dr. Med
Vet., Dipl. CBraRVet

HOSPITAL NAME

Veterinary Image
Center

REFERRING VET

Dr. V. Collazo, DVM

INVOICE

56513

DATE

2-1-23