



PATIENT PRESENTING CLINICAL SIGNS

Loki Deforest Collided on the another dog while playing 3 weeks ago, yelped while playing 2 weeks ago- non weight bearing & swelling on LFL for 3 weeks
 Abnormal PE/Chem/CBC/UA Results: Hard to touch- lemon sized swelling on the dorsal aspect of radius-carpal joint temp- normal, CBC, blood chem- unremarkable

SPECIES

Canine

RADIOGRAPHIC STUDY OF THE LEFT THORACIC LIMB

Radiographs of the left thoracic limb are provided for review, three images, orthogonal views.

BREED

RADIOGRAPHIC FINDINGS

Labrador Retriever
 Mix

Left Thoracic Limb

Centered on the distal metaphysis of the left radius is a moderate mixed osteolytic and osteoproliferative lesion with medium length and indistinct zone transition. There is moderate amorphous periosteal proliferation with loss of the distal and dorsal border of the cortical margins.

SEX

Male

Circumferential to the bone lesion, a soft tissue mass effect and focal swelling on the left distal radius and antebrachial joint is seen.

AGE

1 Year

The left ulna, elbow, and shoulder joints are normal.

The carpal and metacarpal joints are normal.

No other abnormalities are identified.

INTERPRETED BY

Tilde Rodrigues Froes,
 DMV, MSc., Dr. Med
 Vet., Dipl. CBraRVet

RADIOGRAPHIC DIAGNOSIS

- Monostotic aggressive mixed lesion of the left radius. Differential diagnosis includes neoplasia such as osteosarcoma, chondrosarcoma, or fibrosarcoma. Less likely fungal osteomyelitis.

HOSPITAL NAME

St. Catherine's Animal
 Hospital

INTERPRETATION OF THE FINDINGS & FURTHER RECOMMENDATIONS

FNA or biopsy of the left radius is suggested for a definitive diagnosis and is recommended as a next approach. Fungal titers for valley fever or other regional fungal disease may be appropriate.

REFERRING VET

Dr. Jui Gokhale

Three view thoracic radiographs may be useful in further evaluation of evidence of pulmonary metastatic disease.

INVOICE

56514

DATE

2-1-23



PATIENT

Loki Deforest

SPECIES

Canine

BREED

Labrador Retriever
Mix

SEX

Male

AGE

1 Year

INTERPRETED BY

Tilde Rodrigues Froes,
DMV, MSc., Dr. Med
Vet., Dipl. CBraRVet

HOSPITAL NAME

St. Catherine's Animal
Hospital

REFERRING VET

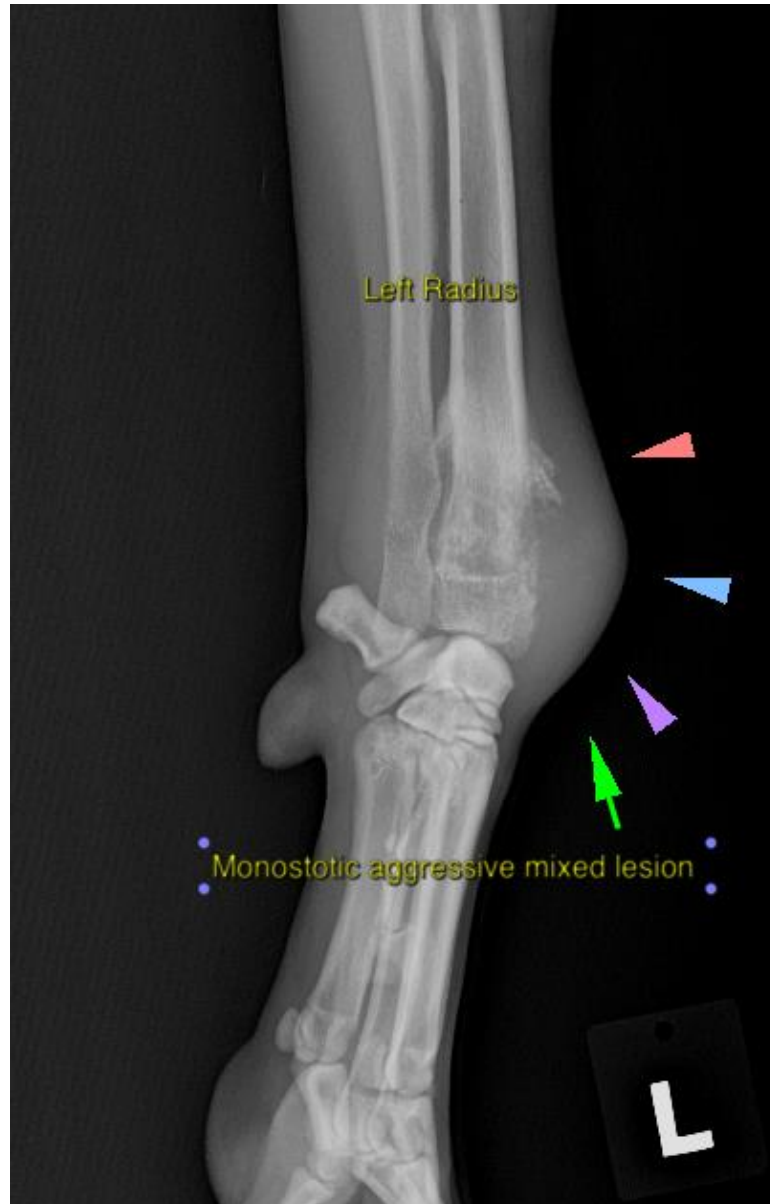
Dr. Jui Gokhale

INVOICE

56514

DATE

2-1-23





PATIENT

Loki Deforest

SPECIES

Canine

BREED

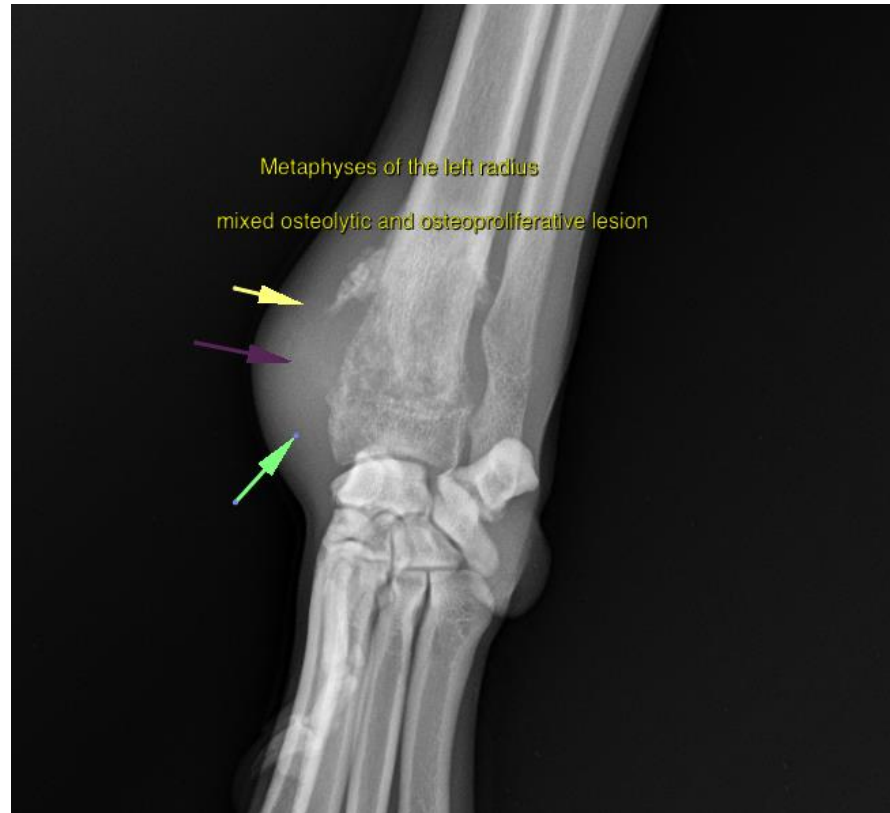Labrador Retriever
Mix

SEX

Male

AGE

1 Year



INTERPRETED BY

Tilde Rodrigues Froes,
DMV, MSc., Dr. Med
Vet., Dipl. CBraRVet

The information and recommendations provided are based on the images presented by the referring veterinarian. No evaluation can be communicated regarding pathology that was not visible in the image/video clips provided.

HOSPITAL NAME

St. Catherine's Animal
Hospital

Thank you for this referral. If the clinical or image interpretation does not parallel your findings or if I can be of any further assistance please contact me.

Tilde Rodrigues Froes, DMV, MSc., Dr. Med.Vet., Dipl.CBraRVet
info@sonopath.com

REFERRING VET

Dr. Jui Gokhale

INVOICE

56514

DATE

2-1-23