



PATIENT

Toulose Olson

SPECIES

Feline

BREED

DSH

SEX

MN

AGE

3Y, 6M

WEIGHT

11.3lbs

INTERPRETED BY

Tilde Rodrigues Froes,
DMV, MSc., Dr. Med
Vet., Dipl. CBraRVet

IMAGING PERFORMED BY

Bailey

HOSPITAL NAME

Casselton Vet Service

REFERRING VET

Dr. Jackie Schmid

INVOICE

72843

DATE

12-3-25

PRESENTING CLINICAL SIGNS

Starting in September, the patient had been chewing at his hind legs, overgrooming, and losing hair. By November, head tremors had developed, now occurring spontaneously. Recently, hind-end weakness and ataxia have worsened, with right-sided weakness and a rightward body curve noted on exam. Feline Neuro Panel was submitted to IDEXX and was all negative. Started on prednisolone 11/18/25.

COMPUTED TOMOGRAPHIC STUDY OF THE HEAD

A pre- and post-contrast CT study of the head are provided for review totaling 2 series. One pre-contrast series of the head bone algorithm. One post-contrast series of the head, bone algorithm.

COMPUTED TOMOGRAPHIC FINDINGS

No intracranial mass effect, falx cerebri deviation, abnormal parenchymal or meningeal enhancement, or ventriculomegaly is identified.

The cribriform plate is intact.

The nasal cavities and turbinates are within normal limits.

The oropharynx, nasopharynx and larynx are within normal limits.

The frontal sinuses are unremarkable.

The tympanic cavities and external auditory canals are within normal limits.

The globes and retrobulbar spaces are within normal limits.

All teeth are within normal limits.

The temporomandibular joints are bilaterally congruent.

The medial retropharyngeal lymph nodes and mandibular lymph nodes are unremarkable.

The mandibular, parotid and zygomatic salivary glands are unremarkable.

COMPUTED TOMOGRAPHIC DIAGNOSIS

- Normal CT study of the head.

INTERPRETATION OF THE FINDINGS & FURTHER RECOMMENDATIONS

The CT study of the head is unremarkable, with no tomographic changes detected that would correlate with structural intracranial or in the calvarium. It is important to note that the sensitivity of computed tomography is lower compared to MRI for detecting certain intracranial diseases, including vascular lesions, small or early neoplasms, infectious/inflammatory conditions (e.g., meningitis, encephalitis), or toxicity-related changes.



PATIENT

Touloose Olson

SPECIES

Feline

BREED

DSH

SEX

MN

AGE

3Y, 6M

WEIGHT

11.3lbs

INTERPRETED BY

Tilde Rodrigues Froes,
DMV, MSc., Dr. Med
Vet., Dipl. CBraRVet

IMAGING PERFORMED BY

Bailey

HOSPITAL NAME

Casselton Vet Service

REFERRING VET

Dr. Jackie Schmid

INVOICE

72843

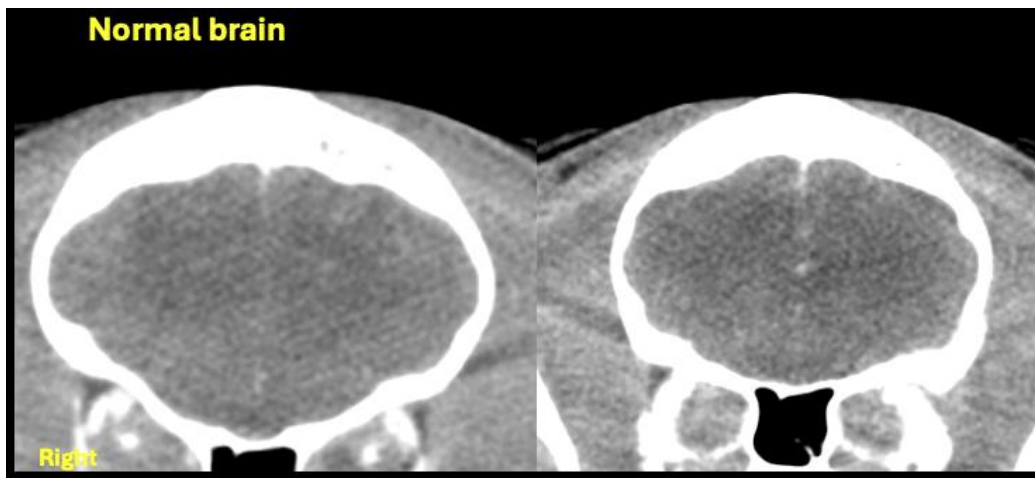
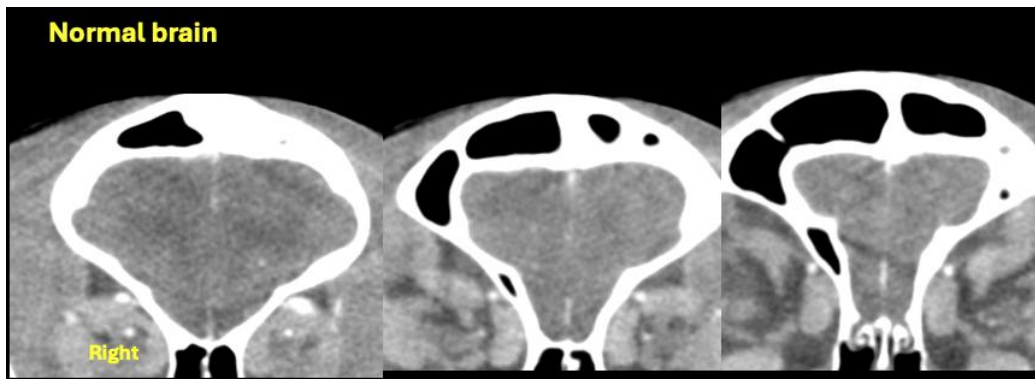
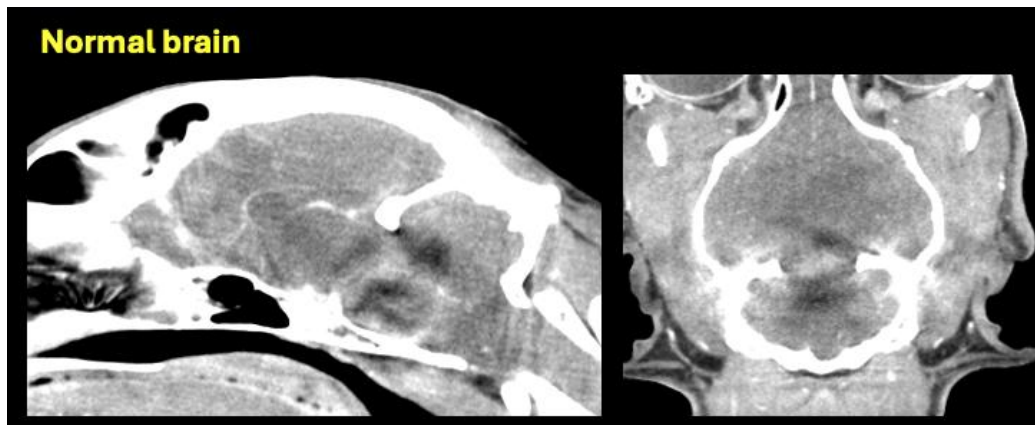
DATE

12-3-25

If neurologic signs persist or progress, MRI is recommended for superior characterization of the brain parenchyma and meninges. Also, consider a cerebrospinal fluid (CSF) analysis.

TECHNICAL COMMENTS

There is considerable hard-beam artifact in the region of the cerebellum and caudal fossa, reducing the sensitivity of the examination especially in this area.





PATIENT

Touloose Olson

SPECIES

Feline

BREED

DSH

SEX

MN

AGE

3Y, 6M

WEIGHT

11.3lbs

INTERPRETED BY

Tilde Rodrigues Froes,
DMV, MSc., Dr. Med
Vet., Dipl. CBraRVet

IMAGING PERFORMED BY

Bailey

HOSPITAL NAME

Casselton Vet Service

REFERRING VET

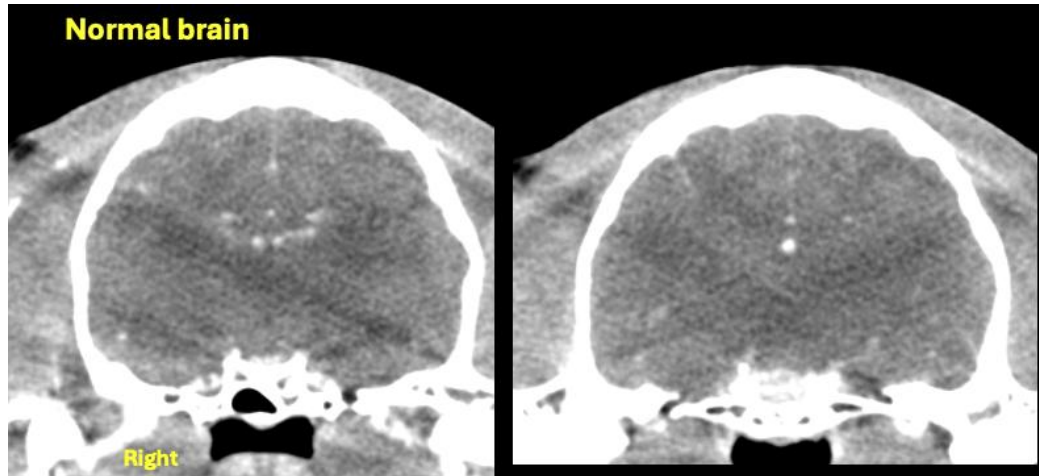
Dr. Jackie Schmid

INVOICE

72843

DATE

12-3-25



The information and recommendations provided are based on the images presented by the referring veterinarian. No evaluation can be communicated regarding pathology that was not visible in the image/video clips provided.

Thank you for this referral. If the clinical or image interpretation does not parallel your findings or if I can be of any further assistance, please contact me.

Tilde Rodrigues Froes, DMV, MSc., Dr. Med.Vet., Dipl.CBraRVet
info@sonopath.com