



## PATIENT

Happy Palella

## SPECIES

Canine

## BREED

German Shep X

## SEX

MN

## AGE

9

## WEIGHT

30.9kg

## INTERPRETED BY

Tilde Rodrigues Froes,  
DMV, MSc., Dr. Med  
Vet., Dipl. CBraRVet

## IMAGING PERFORMED BY

KP/NB

## HOSPITAL NAME

Green Dog Dental and  
Wellness

## REFERRING VET

Dr. Habawel

## INVOICE

72865

## DATE

12-3-25

## PRESENTING CLINICAL SIGNS

looking for metastasis after oral malignant melanoma diagnosis

## RADIOGRAPHIC STUDY OF THE THORAX

Radiographs of the thorax in two imaging planes are provided for review totaling 3 images. One right lateral, one left lateral and one ventrodorsal view.

## RADIOGRAPHIC FINDINGS

The thoracic trachea and esophagus are unremarkable.

The pulmonary parenchyma exhibits normal volume of expansion, and normal opacity, there is no evidence of pulmonary nodules or masses.

The cardiac silhouette is normal in size, shape and contour (VHS= 10.4, normal range). The pulmonary vasculature is within normal limits.

The pleural space, mediastinum, and diaphragm are within normal limits.

No significant abnormalities are identified in the collimated cranial abdomen or visualized osseous structures.

## RADIOGRAPHIC DIAGNOSIS

- Normal thoracic structures.

## INTERPRETATION OF THE FINDINGS & FURTHER RECOMMENDATIONS

The radiographic findings demonstrate a normal thoracic exam. No evidence of pulmonary metastatic disease.



## PATIENT

Happy Palella

## SPECIES

Canine

## BREED

German Shep X

## SEX

MN

## AGE

9

## WEIGHT

30.9kg

## INTERPRETED BY

Tilde Rodrigues Froes,  
DMV, MSc., Dr. Med  
Vet., Dipl. CBraRVet

## IMAGING PERFORMED BY

KP/NB

## HOSPITAL NAME

Green Dog Dental and  
Wellness

## REFERRING VET

Dr. Habawel

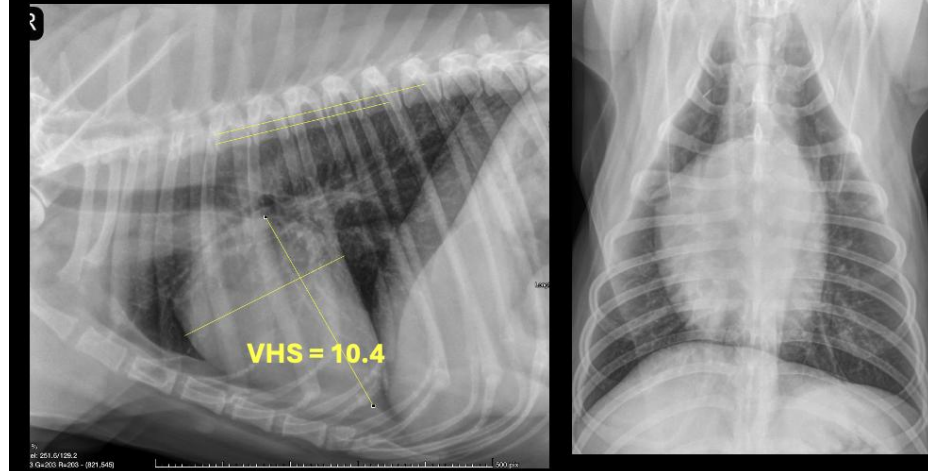
## INVOICE

72865

## DATE

12-3-25

## Normal thorax



The information and recommendations provided are based on the images presented by the referring veterinarian. No evaluation can be communicated regarding pathology that was not visible in the image/video clips provided.

Thank you for this referral. If the clinical or image interpretation does not parallel your findings or if I can be of any further assistance, please contact me.

Tilde Rodrigues Froes, DMV, MSc., Dr. Med.Vet., Dipl.CBraRVet  
[info@sonopath.com](mailto:info@sonopath.com)