



PATIENT

Marvin Dorrity

SPECIES

Canine

BREED

Jack Russell Terrier

SEX

Male

AGE

5

WEIGHT

8

INTERPRETED BY

Tilde Rodrigues Froes,
DMV, MSc., Dr. Med
Vet., Dipl. CBraRVet

IMAGING PERFORMED BY

Brandan Costas

HOSPITAL NAME

Animal Trust - Bolton

REFERRING VET

Brandan Costas

INVOICE

73028

DATE

12-17-25

PRESENTING CLINICAL SIGNS

On-going intermittent Right Forelimb lameness Examination unremarkable
Abnormal PE/Chem/CBC/UA Results: NAD

COMPUTED TOMOGRAPHIC STUDY OF THE THORACIC LIMBS

Single, non-contrast computed tomographic series of both thoracic limbs acquired using a bone algorithm.

COMPUTED TOMOGRAPHIC FINDINGS

RIGHT THORACIC LIMB

The scapula and humerus are within normal anatomical limits.

The distal radius shows a mild antecurvatum configuration; however, there is no evidence of humeroradial or humeroulnar incongruency.

The antebrachial and carpal joints are within normal limits.

The metacarpal bones and phalanges are intact, with no evidence of aggressive osseous lesions, traumatic changes, or degenerative alterations, including the unguis processes.

The digital and metacarpal pads are unremarkable, with preserved contour and normal attenuation.

The adjacent soft tissues demonstrate normal volume and attenuation, with no identifiable mass effect. No radiopaque soft tissue foreign material is detected.

LEFT THORACIC LIMB

The scapula and humerus are within normal anatomical limits.

The distal radius shows a mild antecurvatum configuration; however, there is no evidence of humeroradial or humeroulnar incongruency.

The antebrachial and carpal joints are within normal limits.

The metacarpal bones and phalanges are intact, with no evidence of aggressive osseous lesions, traumatic changes, or degenerative alterations, including the unguis processes.

The digital and metacarpal pads are unremarkable, with preserved contour and normal attenuation.

The adjacent soft tissues demonstrate normal volume and attenuation, with no identifiable mass effect. No radiopaque soft tissue foreign material is detected.

COMPUTED TOMOGRAPHIC DIAGNOSIS

- Normal computed tomographic appearance of the osseous and soft tissue structures of both thoracic limbs.
- Incidental mild bilateral distal radial antecurvatum, without associated joint incongruency or secondary degenerative changes.



PATIENT

Marvin Dorrity

SPECIES

Canine

BREED

Jack Russell Terrier

SEX

Male

AGE

5

WEIGHT

8

INTERPRETED BY

Tilde Rodrigues Froes,
DMV, MSc., Dr. Med
Vet., Dipl. CBraRVet

IMAGING PERFORMED BY

Brandan Costas

HOSPITAL NAME

Animal Trust - Bolton

REFERRING VET

Brandan Costas

INVOICE

73028

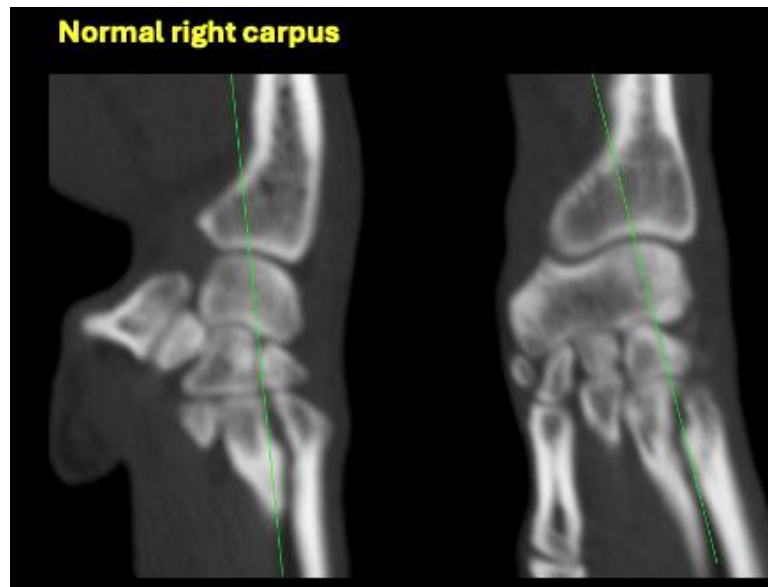
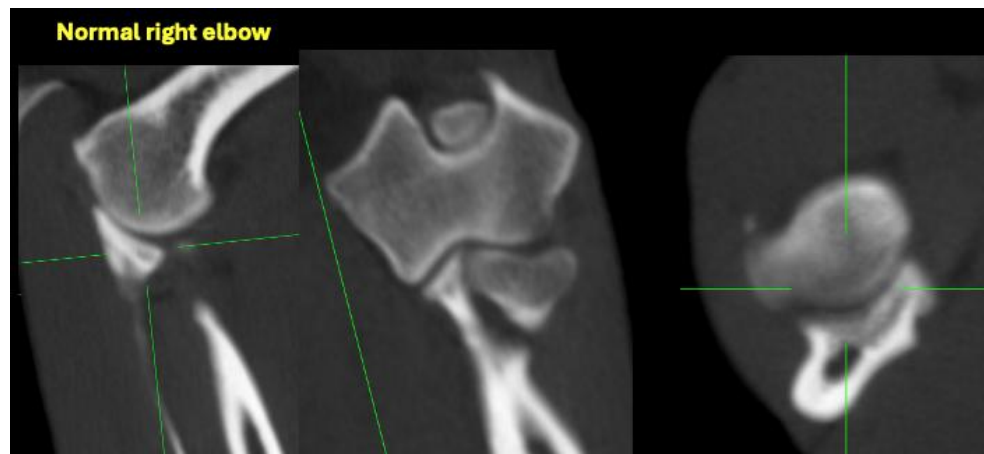
DATE

12-17-25

INTERPRETATION OF THE FINDINGS & FURTHER RECOMMENDATIONS

No tomographic abnormalities are identified in the bones, joints, or soft tissues of right thoracic limb that would explain the reported intermittent right forelimb lameness. The mild bilateral distal radial antecurvatum is considered an incidental anatomical variation, with no evidence of secondary degenerative joint disease.

It is important to note that computed tomography has limited sensitivity for detecting subtle soft tissue, ligamentous, tendinous, or cartilaginous abnormalities. If clinical signs persist, further evaluation with orthopedic reassessment, ultrasonography, or MRI may be considered to investigate non-osseous causes of lameness.





PATIENT

Marvin Dorrity

SPECIES

Canine

BREED

Jack Russell Terrier

SEX

Male

AGE

5

WEIGHT

8

INTERPRETED BY

Tilde Rodrigues Froes,
DMV, MSc., Dr. Med
Vet., Dipl. CBraRVet

IMAGING PERFORMED BY

Brandan Costas

HOSPITAL NAME

Animal Trust - Bolton

REFERRING VET

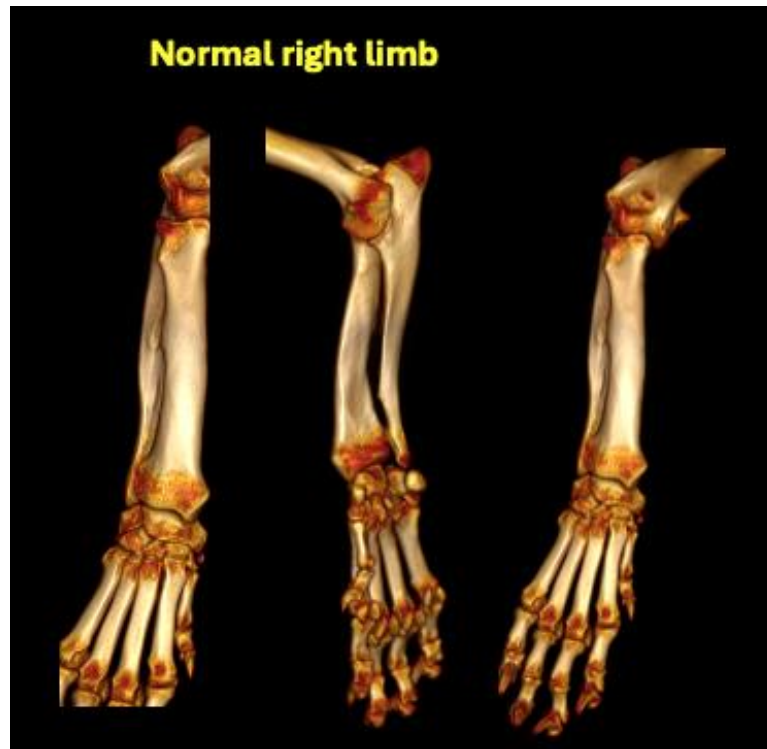
Brandan Costas

INVOICE

73028

DATE

12-17-25



The information and recommendations provided are based on the images presented by the referring veterinarian. No evaluation can be communicated regarding pathology that was not visible in the image/video clips provided.

Thank you for this referral. If the clinical or image interpretation does not parallel your findings or if I can be of any further assistance, please contact me.

Tilde Rodrigues Froes, DMV, MSc., Dr. Med.Vet., Dipl.CBraRVet
info@sonopath.com