



PATIENT

Jasper Bailey

SPECIES

Canine

BREED

Cross Breed

SEX

Male

AGE

5Y

WEIGHT

16

INTERPRETED BY

Tilde Rodrigues Froes,
DMV, MSc., Dr. Med
Vet., Dipl. CBraRVet

IMAGING PERFORMED BY

Hollie Sharp

HOSPITAL NAME

Animal Trust -
Ellesmere Port

REFERRING VET

Janet Mitchell

INVOICE

73006

DATE

12-16-25

PRESENTING CLINICAL SIGNS

lump between toes, potential fb. lanced with scapel, very thickened, no tract seen but all very thickened. flushed and attempted to probe higher up but unable

COMPUTED TOMOGRAPHIC STUDY OF THE LEFT THORACIC LIMB (CARPUS/MANUS)

Pre- and post-contrast series of the left thoracic limb are provided for review. One pre-contrast series of the left thoracic limb (bone algorithm). One post-contrast series of the left thoracic limb (bone algorithm).

COMPUTED TOMOGRAPHIC FINDINGS

LEFT THORACIC LIMB (Focused on Carpus/Manus)

The phalanges, sesamoid bones, and metacarpal bones are intact and exhibit no evidence of aggressive osseous lesions, traumatic changes, or degenerative alterations, including the unguis processes.

The adjacent soft tissues are of normal volume and attenuation, with no identifiable mass effect. There is no soft tissue radiopaque foreign material detected.

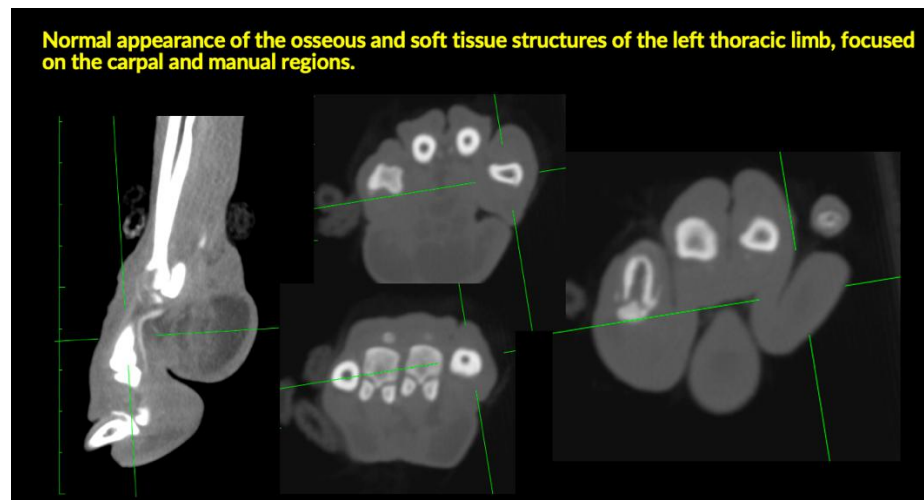
The digital and metacarpal pads are unremarkable, with preserved contour and attenuation.

COMPUTED TOMOGRAPHIC DIAGNOSIS

- Normal appearance of the osseous and soft tissue structures of the left distal thoracic limb.
- No radiopaque foreign material or soft tissue mass effect identified.

INTERPRETATION OF THE FINDINGS & FURTHER RECOMMENDATIONS

The tomographic examination of the distal left thoracic limb shows no evidence of foreign material, osseous abnormalities, or soft tissue mass effect that could account for the described soft tissue thickened between the digits. Further evaluation with biopsy of the lesion is suggested, as the abnormality may be more superficial and not clearly delineated on the CT study.





PATIENT

Jasper Bailey

SPECIES

Canine

BREED

Cross Breed

SEX

Male

AGE

5Y

WEIGHT

16

INTERPRETED BY

Tilde Rodrigues Froes,
DMV, MSc., Dr. Med
Vet., Dipl. CBraRVet

IMAGING PERFORMED BY

Hollie Sharp

HOSPITAL NAME

Animal Trust -
Ellesmere Port

REFERRING VET

Janet Mitchell

INVOICE

73006

DATE

12-16-25

The information and recommendations provided are based on the images presented by the referring veterinarian. No evaluation can be communicated regarding pathology that was not visible in the image/video clips provided.

Thank you for this referral. If the clinical or image interpretation does not parallel your findings or if I can be of any further assistance, please contact me.

Tilde Rodrigues Froes, DMV, MSc., Dr. Med.Vet., Dipl.CBraRVet
info@sonopath.com