



PATIENT

Alexander Rodriguez

SPECIES

Feline

BREED

DSH

SEX

Male Neutered

AGE

6

WEIGHT

12

INTERPRETED BY

Tilde Rodrigues Froes,
DMV, MSc., Dr. Med
Vet., Dipl. CBraRVet

IMAGING PERFORMED BY

Armando Sobrado

HOSPITAL NAME

Miami Springs Animal
Hospital

REFERRING VET

Paul Cameau

INVOICE

72558

DATE

11-6-25

PRESENTING CLINICAL SIGNS

A mass was removed from the patient's right hind limb. Histopathology revealed it to be malignant, and further evaluation is recommended to rule out metastasis or any other abnormalities in the patient's body.

COMPUTED TOMOGRAPHIC STUDY OF THE THORAX, ABDOMEN AND SPINE

A pre- and post-contrast CT study of the whole body (thorax, abdomen, and spine) was provided for review, totaling two series: one pre-contrast and one post-contrast series acquired using a soft tissue algorithm.

COMPUTED TOMOGRAPHIC FINDINGS

SPINE AND BODY WALL

There is a diffuse, infiltrative, multinodular soft tissue thickening involving the cutaneous and subcutaneous tissues of the right dorsal gluteal region, extending cranially along the right flank.

The lesion is predominantly superficial, with the thickest portion measuring approximately 8.0 mm in depth. It extends from the level of the L7 lumbar vertebra cranially toward the subcutaneous tissue overlying the mid portion of the right hindlimb (biceps femoris muscle). The margins are indistinct due to the infiltrative nature of the lesion, but the process remains superficial in most of the lesion, without evidence of underlying bone involvement.

The right inguinal lymph node is mildly enlarged, measuring approximately 1.0 cm in length, slightly larger than the contralateral node.

The sacral and medial iliac lymph nodes are within normal limits.

The vertebral bodies, sacrum, and caudal vertebrae are unremarkable, with normal alignment, intervertebral disc spaces, and vertebral canal. No aggressive osseous lesions are identified.

THORAX

The trachea and main bronchi are within normal limits.

The pulmonary parenchyma exhibits normal attenuation. No pulmonary micronodules, nodules, or masses are observed.

The bronchial tree shows regular branching and tapering, and bronchial walls are thin and smooth. The bronchus-to-artery ratio is normal.

The heart and pulmonary vessels appear normal. The contrast medium adequately opacifies the cardiac chambers and vessels on the post-contrast series.

The sternal, cranial mediastinal, and tracheobronchial lymph nodes are within normal limits.

The pleural space, diaphragm, and thoracic wall are unremarkable.

The thoracic esophagus is unremarkable.



PATIENT

Alexander Rodriguez

SPECIES

Feline

BREED

DSH

SEX

Male Neutered

AGE

6

WEIGHT

12

INTERPRETED BY

Tilde Rodrigues Froes,
DMV, MSc., Dr. Med
Vet., Dipl. CBraRVet

IMAGING PERFORMED BY

Armando Sobrado

HOSPITAL NAME

Miami Springs Animal
Hospital

REFERRING VET

Paul Cameau

INVOICE

72558

DATE

11-6-25

ABDOMEN

The liver is homogeneously soft tissue attenuating and uniformly contrast enhancing with normal size and shape. The gallbladder, cystic duct and common bile duct are within normal limits.

The kidneys are normal in size, shape, contour, and attenuation pre- and post-contrast. The renal pelvis and ureters are within normal limits.

The urinary bladder is moderately filled by homogeneously hypoattenuating fluid material admixed with hyperattenuating contrast material. Normal wall thickness.

The spleen is homogeneously soft tissue attenuating, and uniformly contrast enhancing, with normal size and shape.

The gastrointestinal tract shows normal distribution and distention, without mural thickening or mass effect.

The colon and rectum contain a normal mixture of gas and fecal material, with normal wall thickness.

The pancreas, adrenal glands, and abdominal lymph nodes are within normal limits.

The serosal fat has normal attenuation, and no peritoneal effusion or masses are observed.

COMPUTED TOMOGRAPHIC DIAGNOSIS

- Infiltrative behavior, multinodular, superficial soft tissue lesion extending along the right dorsal gluteal and flank region, consistent with possible local neoplastic recurrence.
- Mild right inguinal lymphadenopathy – reactive or metastatic.
- Normal spine and vertebral alignment.
- No evidence of thoracic or abdominal metastatic disease.

INTERPRETATION OF THE FINDINGS & FURTHER RECOMMENDATIONS

The tomographic findings indicate a superficial infiltrative soft tissue lesion extending along the right dorsal gluteal and flank region, compatible with possible local recurrence of the previously excised neoplasm, the primary differential diagnoses include soft tissue sarcoma, feline injection site sarcoma. The mild enlargement of the right inguinal lymph node may represent a reactive or early metastatic process.

No evidence of pulmonary, abdominal, or osseous metastatic disease is identified.

Support material: [Alexander Rodriguez CT.mov](#), [Alexander Rodriguez CT 1 .mov](#)



PATIENT

Alexander Rodriguez

SPECIES

Feline

BREED

DSH

SEX

Male Neutered

AGE

6

WEIGHT

12

INTERPRETED BY

Tilde Rodrigues Froes,
DMV, MSc., Dr. Med
Vet., Dipl. CBraRVet

IMAGING PERFORMED BY

Armando Sobrado

HOSPITAL NAME

Miami Springs Animal
Hospital

REFERRING VET

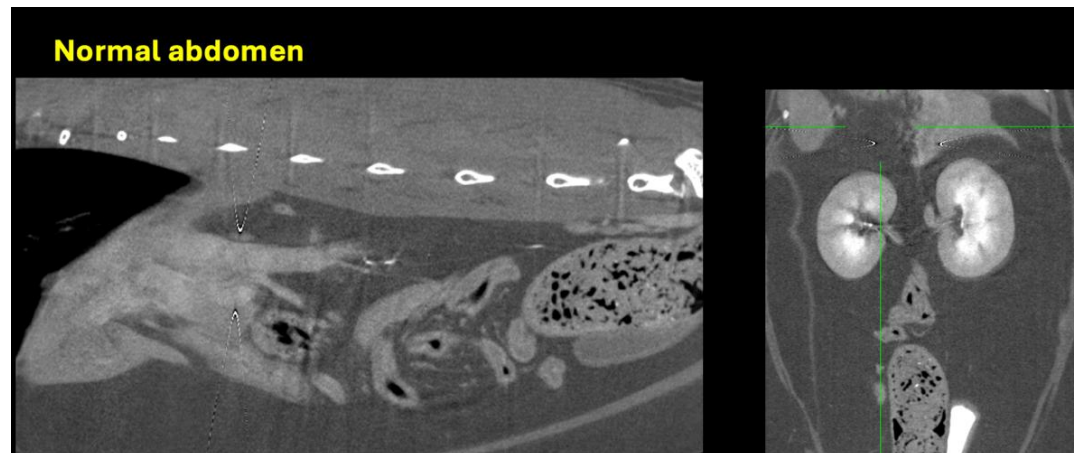
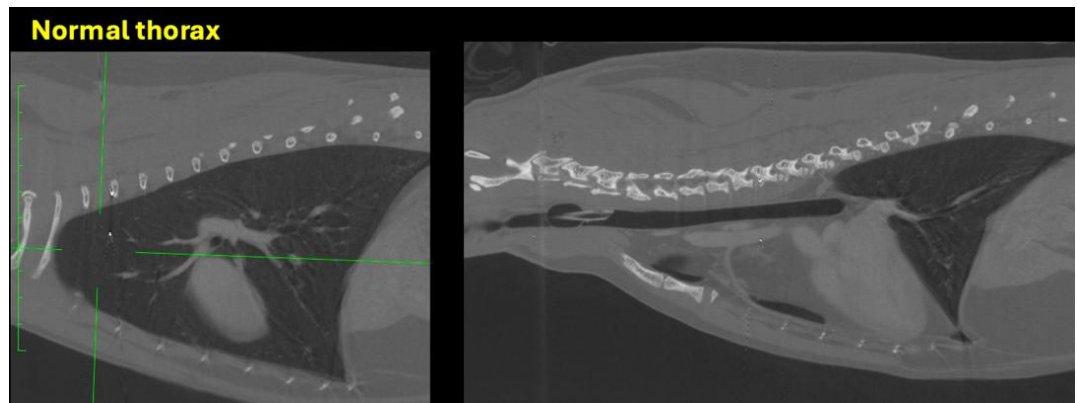
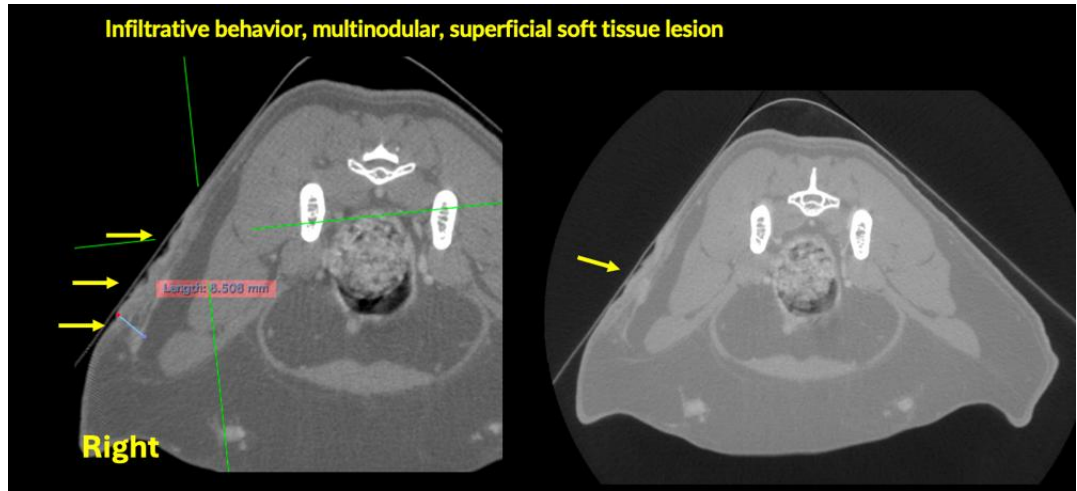
Paul Cameau

INVOICE

72558

DATE

11-6-25





PATIENT

Alexander Rodriguez

SPECIES

Feline

BREED

DSH

SEX

Male Neutered

AGE

6

WEIGHT

12

INTERPRETED BY

Tilde Rodrigues Froes,
DMV, MSc., Dr. Med
Vet., Dipl. CBraRVet

IMAGING PERFORMED BY

Armando Sobrado

HOSPITAL NAME

Miami Springs Animal
Hospital

REFERRING VET

Paul Cameau

INVOICE

72558

DATE

11-6-25

The information and recommendations provided are based on the images presented by the referring veterinarian. No evaluation can be communicated regarding pathology that was not visible in the image/video clips provided.

Thank you for this referral. If the clinical or image interpretation does not parallel your findings or if I can be of any further assistance, please contact me.

Tilde Rodrigues Froes, DMV, MSc., Dr. Med.Vet., Dipl.CBraRVet
info@sonopath.com