



PATIENT

Caroline Johnson

SPECIES

Canine

BREED

Cavalier

SEX

FS

AGE

5

WEIGHT

14.2lbs

INTERPRETED BY

Tilde Rodrigues Froes,
DMV, MSc., Dr. Med
Vet., Dipl. CBraRVet

IMAGING PERFORMED BY

Arch Gordon

HOSPITAL NAME

Coral Ridge Animal
Hospital

REFERRING VET

Arch Gordon

INVOICE

72474

DATE

11-3-25

PRESENTING CLINICAL SIGNS

Reluctance to jump up and down Possible pain in back noted by owners On exam fully ambulatory , no neurologic deficits noted very mild tenderness in Lumbosacral area Owner also reports litter mate had Chiari malformation

RADIOGRAPHIC STUDY OF THE LUMBAR SPINE

Orthogonal views (lateral and ventrodorsal projections) of thoracolumbar and lumbar spine are provided for review, totaling

RADIOGRAPHIC FINDINGS

Thoracolumbar and Lumbar Spine

The vertebral alignment is within normal limits. The vertebral bodies are normal in shape, size and opacity.

There is a discrete narrowing of the L3-L4 intervertebral disc space. The remaining intervertebral disc spaces are within normal limits.

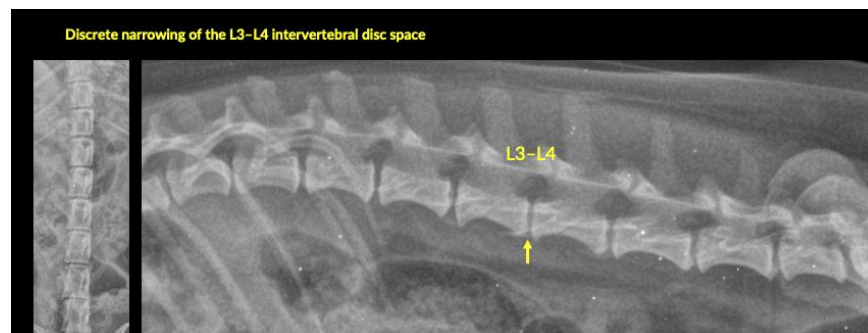
The visible abdominal and thoracic soft tissues are unremarkable.

RADIOGRAPHIC DIAGNOSIS

- Discrete narrowing of the L3-L4 intervertebral disc space. Differential diagnoses: positional artifact or, less likely, mild intervertebral disc disease.
- Otherwise, normal thoracolumbar and lumbar spine study.

INTERPRETATION OF THE FINDINGS & FURTHER RECOMMENDATIONS

The radiographic findings reveal minimal narrowing of the L3-L4 intervertebral disc space, which may represent a positional technical artifact. However, early intervertebral disc degeneration cannot be entirely excluded. Pain management may be considered as clinically indicated. Correlation with clinical findings and, if warranted, advanced imaging such as computed tomography (CT), myelotomography, or magnetic resonance imaging (MRI) is recommended for further assessment of potential disc pathology, particularly if any neurological signs are present.





PATIENT

Caroline Johnson

SPECIES

Canine

BREED

Cavalier

SEX

FS

AGE

5

WEIGHT

14.2lbs

INTERPRETED BY

Tilde Rodrigues Froes,
DMV, MSc., Dr. Med
Vet., Dipl. CBraRVet

IMAGING PERFORMED BY

Arch Gordon

HOSPITAL NAME

Coral Ridge Animal
Hospital

REFERRING VET

Arch Gordon

INVOICE

72474

DATE

11-3-25

The information and recommendations provided are based on the images presented by the referring veterinarian. No evaluation can be communicated regarding pathology that was not visible in the image/video clips provided.

Thank you for this referral. If the clinical or image interpretation does not parallel your findings or if I can be of any further assistance, please contact me.

Tilde Rodrigues Froes, DMV, MSc., Dr. Med.Vet., Dipl.CBraRVet
info@sonopath.com