



PATIENT

Wiley Kelly

SPECIES

Canine

BREED

German Shepherd

SEX

Neutered Male

AGE

6

WEIGHT

30.95kg

INTERPRETED BY

Tilde Rodrigues Froes,
DMV, MSc., Dr. Med
Vet., Dipl. CBraRVet

IMAGING PERFORMED BY

RVT

HOSPITAL NAME

River Valley Veterinary
Wellness Clinic

REFERRING VET

Jennifer Stelfox

INVOICE

72786

DATE

11-27-25

PRESENTING CLINICAL SIGNS

On November 21 River Valley Veterinary clinic took xrays of pelvis, femurs, stifles and hocks. Xrays were taken as the dog previously has had an FHO RHL years ago and seemed to be functioning well, but has been favoring the RHL more since Sept 2025. The dog was reluctant to have the RHL stifle extended during rehab exam and had DWB on the RHL. Dr Stelfox's impression of the November 21 rads. V/D pelvic rad shows the FHO RHL site and the sx site on the RHL femoral neck looks smooth, but there is a linear piece of bone projecting from the rt acetabulum towards the RHL femoral neck - is this bony projection rubbing agt the femoral neck? Lateral left and right stifles - nsf except there is some mild OA in left hock. No obvious effusion in either stifle. VD of left and right stifles - small "devils horn" on right stifle lateral tibial plateau. Likely a partial ACL tear. I advsie that a radiologist review these rads and comment on whether he/she agrees with rt stifle change on the V/D view of the rt stile that could be a partial CCL tear and to comment on whether the bony acetabular projection is likely to be contacting the FHO site femoral neck and causing irritation.

RADIOGRAPHIC STUDY OF THE HINDLIMBS - STIFLE JOINTS

Radiographs of the hindlimbs (stifle joints) were provided for review, totaling five images: two lateral views of the right stifle joint, one lateral view of the left stifle joint, and two ventrodorsal/craniocaudal views of the pelvis and stifle joints. The lateral projections of both stifles are mildly oblique.

RADIOGRAPHIC FINDINGS

RIGHT STIFLE JOINT

A spiculated cortical proliferation is present along the caudal surface of the mid-distal femur, located approximately 4.0 cm cranial to the gastrocnemius sesamoid, likely an atypical enthesophyte.

The femorotibiopatellar joint is congruent.

The patella is normal in shape, contour, and position.

No radiographic evidence of stifle joint swelling; however, assessment is limited by summation artifacts caused by superimposition of the penile bone and abdominal wall.

No evidence of degenerative osseous changes involving the proximal tibia, femoral condyles, or sesamoids.

There is a noticeable reduction in gluteal and femoral muscle mass compared to the contralateral limb.

Mild, diffuse osteopenia is present, more evident in the tibia.

In the included pelvic region, the right femoral head is absent. The femoral neck margins are predominantly regular and sclerotic, with a few subchondral microcysts in the most proximal aspect.

The acetabulum is shallow with slight surface irregularity, including in the proximal ipsilateral coxal bone.

A small thin rectangular osseous body is visible within the coxofemoral joint (1.5 cm), this lesion is likely projecting from the acetabulum towards the right femoral neck. Accompanied by additional tiny mild mineralized osteochondromas.

LEFT STIFLE JOINT

The femorotibiopatellar joint is congruent.



PATIENT

Wiley Kelly

SPECIES

Canine

BREED

German Shepherd

SEX

Neutered Male

AGE

6

WEIGHT

30.95kg

INTERPRETED BY

Tilde Rodrigues Froes,
DMV, MSc., Dr. Med
Vet., Dipl. CBraRVet

IMAGING PERFORMED BY

RVT

HOSPITAL NAME

River Valley Veterinary
Wellness Clinic

REFERRING VET

Jennifer Stelfox

INVOICE

72786

DATE

11-27-25

The patella is normal in shape, contour, and position.

No degenerative osseous changes are identified in the proximal tibia, femoral condyles, or sesamoids.

In the collimated pelvic field, the left coxofemoral joint is congruent.

RADIOGRAPHIC DIAGNOSIS

- Right mid-distal femoral spiculated cortical proliferation- atypical enthesophyte, appearing associated with the distal insertion of the pectineus muscle-tendon; possible tendinopathy.
- The right stifle joint appears normal, with no evidence of joint swelling or degenerative changes that would correlate with cranial cruciate ligament instability.
- Absence of the right femoral head, with sclerotic femoral neck margins containing microcysts, a shallow acetabulum, and intra-articular osseous bodies/osteochondromas. The differential diagnosis includes chronic degenerative changes; however, unilateral septic arthritis should be fully excluded despite the generally regular osseous alterations.
- Right-sided muscle atrophy (gluteal and femoral) with mild, diffuse osteopenia, more pronounced in the tibia, consistent with disuse.

INTERPRETATION OF THE FINDINGS & FURTHER RECOMMENDATIONS

The radiographic findings in the right hindlimb demonstrate a spiculated cortical proliferation in the mid-distal femur, associated with the distal insertion of the pectineus muscle-tendon—an atypical enthesophyte, compatible with possible tendinopathy.

Additionally, there is absence of the femoral head, likely associated with a previous osteotomy, accompanied by degenerative changes. Both a tiny and a larger intra-articular osseous fragment or osteochondroma are present, although their exact contribution to the patient's clinical pain cannot be fully determined. Despite the predominantly regular appearance of the osseous margins, unilateral septic arthritis should remain a differential diagnosis. If attainable, consider arthrocentesis for joint fluid analysis.

The right stifle joint is within normal limits, with no radiographic evidence of indirect signs of osteoarthritis, cranial cruciate ligament instability, or joint effusion. Correlation with orthopedic examination, including tibial thrust and cranial drawer tests, is recommended.

TECHNICAL COMMENTS

Both stifle projections are mildly oblique, and the right stifle is additionally affected by summation artifact.



PATIENT

Wiley Kelly

SPECIES

Canine

BREED

German Shepherd

SEX

Neutered Male

AGE

6

WEIGHT

30.95kg

INTERPRETED BY

Tilde Rodrigues Froes,
DMV, MSc., Dr. Med
Vet., Dipl. CBraRVet

IMAGING PERFORMED BY

RVT

HOSPITAL NAME

River Valley Veterinary
Wellness Clinic

REFERRING VET

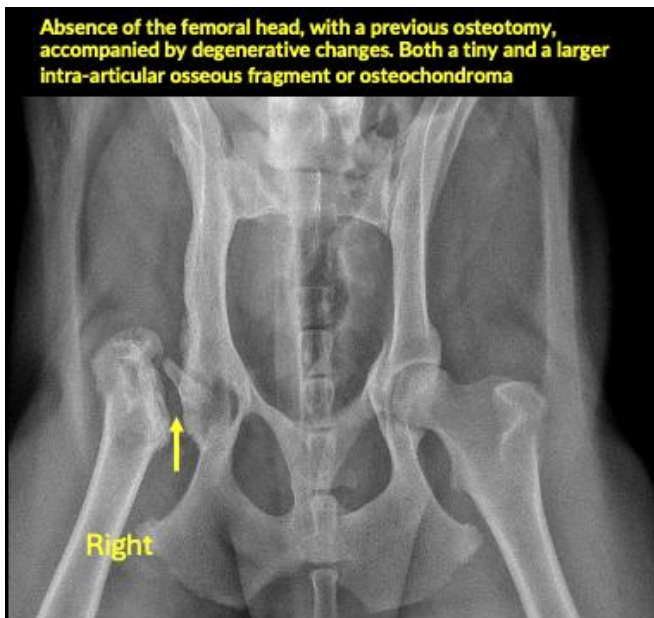
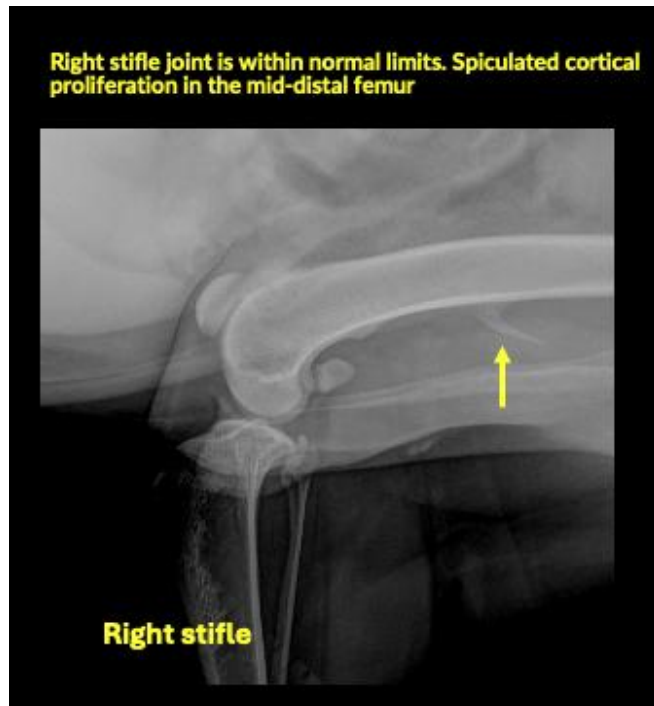Jennifer Stelfox

INVOICE

72786

DATE

11-27-25





PATIENT

Wiley Kelly

SPECIES

Canine

BREED

German Shepherd

SEX

Neutered Male

AGE

6

WEIGHT

30.95kg

INTERPRETED BY

Tilde Rodrigues Froes,
DMV, MSc., Dr. Med
Vet., Dipl. CBraRVet

**IMAGING
PERFORMED BY**

RVT

HOSPITAL NAME

River Valley Veterinary
Wellness Clinic

REFERRING VET

Jennifer Stelfox

INVOICE

72786

DATE

11-27-25

The information and recommendations provided are based on the images presented by the referring veterinarian. No evaluation can be communicated regarding pathology that was not visible in the image/video clips provided.

Thank you for this referral. If the clinical or image interpretation does not parallel your findings or if I can be of any further assistance, please contact me.

Tilde Rodrigues Froes, DMV, MSc., Dr. Med.Vet., Dipl.CBraRVet
info@sonopath.com