



## PATIENT

Kevin Arma

## SPECIES

Canine

## BREED

Black Lab

## SEX

MN

## AGE

6

## WEIGHT

56

## INTERPRETED BY

Tilde Rodrigues Froes,  
DMV, MSc., Dr. Med  
Vet., Dipl. CBraRVet

## IMAGING PERFORMED BY

David

## HOSPITAL NAME

Animal Surgical Center  
- Oceanside

## REFERRING VET

Short

## INVOICE

72756

## DATE

11-25-25

## PRESENTING CLINICAL SIGNS

Ambulatory x 4, right forelimb lameness, with significant offloading, early mm atrophy, no specific localization to discomfort

## COMPUTED TOMOGRAPHIC STUDY OF THE THORACIC LIMBS (ELBOWS) & CERVICAL SPINE

A single, non-contrast computed tomographic study of both thoracic limbs, with emphasis on the elbow joints and cervical spine, was provided for review. Transverse images were acquired using a bone algorithm.

## COMPUTED TOMOGRAPHIC FINDINGS

### RIGHT ELBOW JOINT

The medial coronoid process, anconeal process, radial head, and humeral condyles are within normal limits.

On dorsal and sagittal reformats, the humeroulnar and humeroradial joints are congruent. The remaining collimated limb structures are unremarkable.

The axillary lymph node is mild enlarged.

### LEFT ELBOW JOINT

The medial coronoid process, anconeal process, radial head, and humeral condyles are within normal limits.

On dorsal and sagittal reformats, the humeroulnar and humeroradial joints are congruent. The remaining collimated limb structures are unremarkable.

The axillary lymph node is mild enlarged.

### CERVICAL SPINE

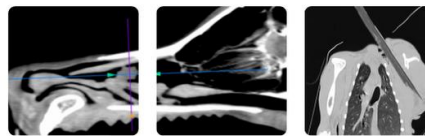
C1-7 cervical vertebral bodies are evaluated.

The cervical vertebral bodies, vertebral canal, articular facets, and spinous processes are within normal limits.

Within the limits of a non-contrast study, no abnormalities of the cervical soft tissues are identified.

## COMPUTED TOMOGRAPHIC DIAGNOSIS

- Normal CT appearance of both elbow joints.
- Normal cervical spine CT within the limits of a non-contrast study.
- The axillary lymph nodes are mildly enlarged, consistent with reactive lymphadenitis of nonspecific cause.



## PATIENT

Kevin Arma

## SPECIES

Canine

## BREED

Black Lab

## SEX

MN

## AGE

6

## WEIGHT

56

## INTERPRETED BY

Tilde Rodrigues Froes,  
DMV, MSc., Dr. Med  
Vet., Dipl. CBraRVet

## IMAGING PERFORMED BY

David

## HOSPITAL NAME

Animal Surgical Center  
- Oceanside

## REFERRING VET

Short

## INVOICE

72756

## DATE

11-25-25

## INTERPRETATION OF THE FINDINGS & FURTHER RECOMMENDATIONS

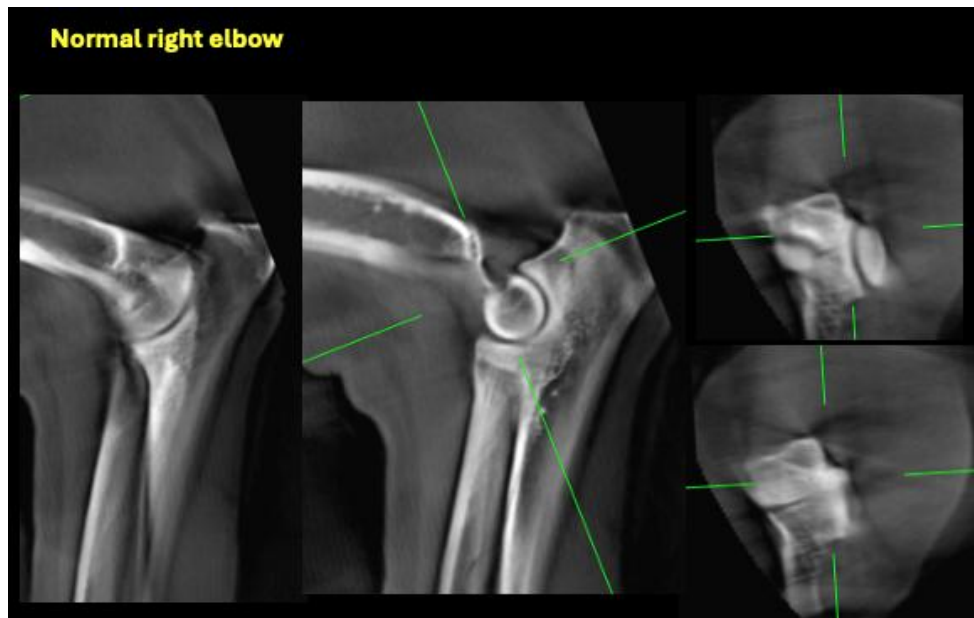
The CT study of the elbow joints and cervical spine reveals no tomographic abnormalities that would account for the patient's right forelimb lameness. Even with normal CT findings consider soft tissue lesions not visible on CT (e.g., biceps tendinopathy, supraspinatus tendinopathy, strain).

Undetermined cause of enlargement of the axillary lymph nodes.

Orthopedic and neurologic re-evaluation are recommended, and an MRI study should be considered if the patient does not improve with pain management.

## TECHNICAL COMMENTS

The examination is moderately limited by movement and streak artifacts. Additionally, the absence of post-contrast series reduces the accuracy of soft-tissue structure evaluation.





## PATIENT

Kevin Arma

## SPECIES

Canine

## BREED

Black Lab

## SEX

MN

## AGE

6

## WEIGHT

56

## INTERPRETED BY

Tilde Rodrigues Froes,  
DMV, MSc., Dr. Med  
Vet., Dipl. CBraRVet

## IMAGING PERFORMED BY

David

## HOSPITAL NAME

Animal Surgical Center  
- Oceanside

## REFERRING VET

Short

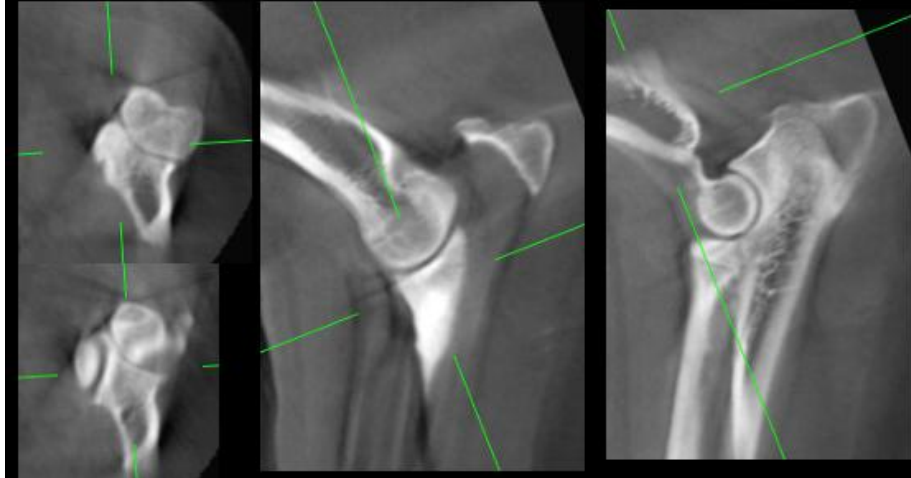
## INVOICE

72756

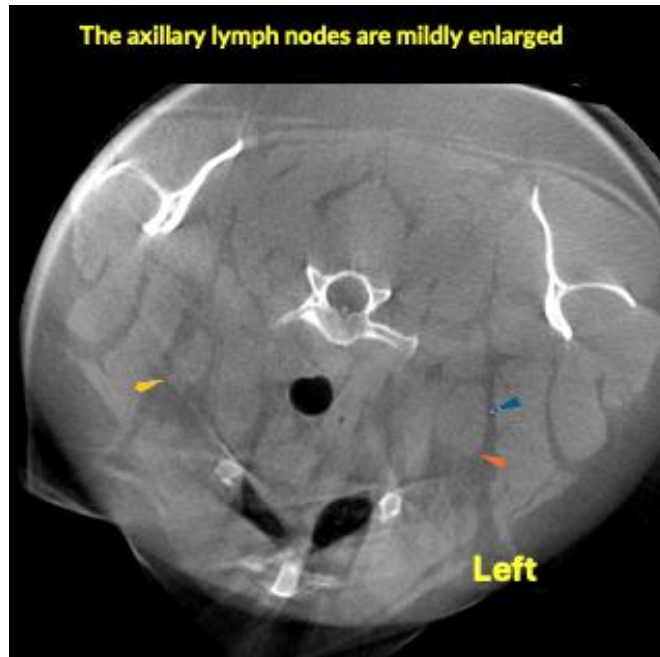
## DATE

11-25-25

### Normal left elbow



### The axillary lymph nodes are mildly enlarged



The information and recommendations provided are based on the images presented by the referring veterinarian. No evaluation can be communicated regarding pathology that was not visible in the image/video clips provided.

Thank you for this referral. If the clinical or image interpretation does not parallel your findings or if I can be of any further assistance, please contact me.

Tilde Rodrigues Froes, DMV, MSc., Dr. Med.Vet., Dipl.CBraRVet  
[info@sonopath.com](mailto:info@sonopath.com)