



PATIENT

Kasey Reidt

SPECIES

Canine

BREED

Golden Retriever

SEX

Female

AGE

25W

WEIGHT

57lbs

INTERPRETED BY

Tilde Rodrigues Froes,
DMV, MSc., Dr. Med
Vet., Dipl. CBraRVet

IMAGING PERFORMED BY

Dr. Burge

HOSPITAL NAME

Wilson Veterinary
Hospital

REFERRING VET

Dr. Garrett

INVOICE

72590

DATE

11-12-25

PRESENTING CLINICAL SIGNS

Recurrent lameness in the left forelimb after exercise since October 2025. Radiographs concerning for possible underlying elbow dysplasia.

COMPUTED TOMOGRAPHIC FINDINGS

LEFT ELBOW JOINT

The medial coronoid process is heterogeneous and irregular, with a small peripheral fragment measuring approximately 2.4 × 4.6 mm. Discrete osteophyte formation is observed along the dorsal border of the anconeal process and the medial humeral condyle.

Additionally, discrete subchondral irregularities with focal sclerosis are identified in the medial humeral condyle.

On dorsal and sagittal reformatted images, the humeroulnar and humeroradial joints appear congruent.

RIGHT ELBOW JOINT

The medial coronoid process, anconeal process, radial head, and humeral condyles are within normal limits.

On dorsal and sagittal reformatted images, the humeroulnar and humeroradial joints appear congruent.

COMPUTED TOMOGRAPHIC DIAGNOSIS

- Findings in the left elbow joint are consistent with medial coronoid disease (fragmented medial coronoid process), characterized by irregularity and fragmentation of the medial coronoid process, associated with early osteoarthritic changes in the anconeal process and medial humeral condyle.
- Discrete subchondral irregularities with focal sclerosis are identified in the left medial humeral condyle. Differential diagnoses include a “kissing lesion” secondary to medial coronoid disease or concurrent osteochondrosis (OCD).
- The right elbow joint is within normal limits.

INTERPRETATION OF THE FINDINGS & FURTHER RECOMMENDATIONS

The tomographic findings indicate unilateral medial compartment disease affecting the left elbow joint, consistent with fragmented medial coronoid process (FMCP) and secondary mild degenerative joint disease.

It is recommended to correlate with orthopedic examination findings. Orthopedic consultation for arthroscopy or surgical planning evaluation of left elbow is suggested.



PATIENT

Kasey Reidt

SPECIES

Canine

BREED

Golden Retriever

SEX

Female

AGE

25W

WEIGHT

57lbs

INTERPRETED BY

Tilde Rodrigues Froes,
DMV, MSc., Dr. Med
Vet., Dipl. CBraRVet

IMAGING PERFORMED BY

Dr. Burge

HOSPITAL NAME

Wilson Veterinary
Hospital

REFERRING VET

Dr. Garrett

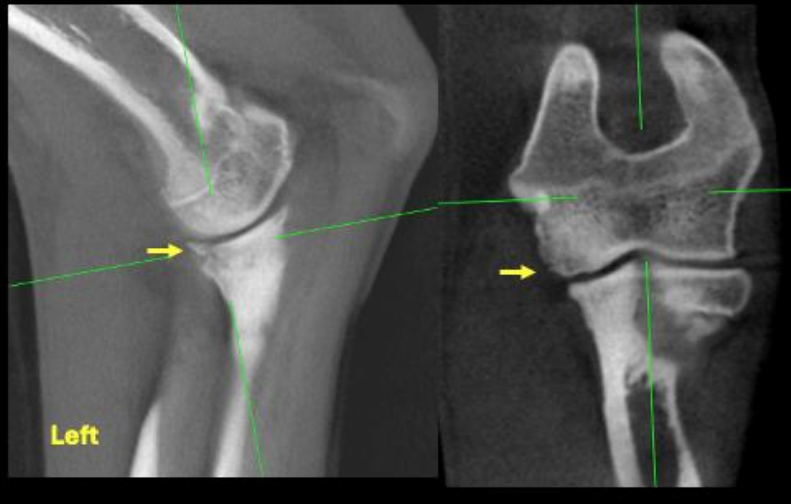
INVOICE

72590

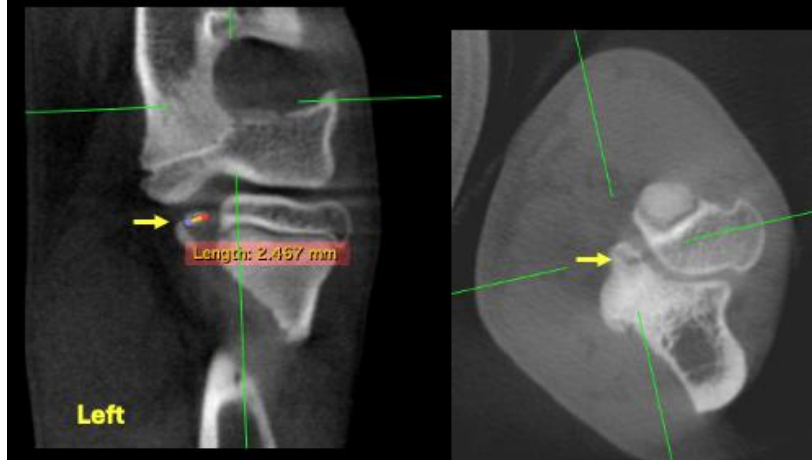DATE

11-12-25

MCP disease, fragmented and kissing lesion



MCP disease and fragmented





PATIENT

Kasey Reidt

SPECIES

Canine

BREED

Golden Retriever

SEX

Female

AGE

25W

WEIGHT

57lbs

INTERPRETED BY

Tilde Rodrigues Froes,
DMV, MSc., Dr. Med
Vet., Dipl. CBraRVet

IMAGING PERFORMED BY

Dr. Burge

HOSPITAL NAME

Wilson Veterinary
Hospital

REFERRING VET

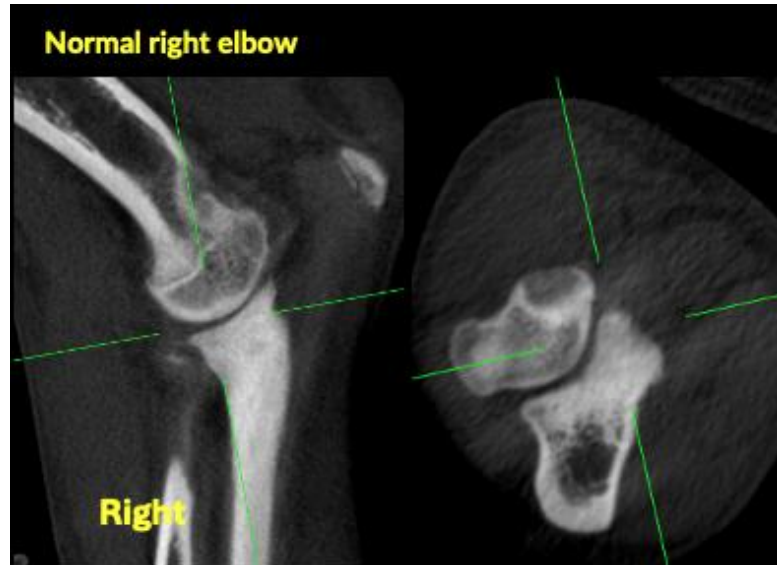Dr. Garrett

INVOICE

72590

DATE

11-12-25



The information and recommendations provided are based on the images presented by the referring veterinarian. No evaluation can be communicated regarding pathology that was not visible in the image/video clips provided.

Thank you for this referral. If the clinical or image interpretation does not parallel your findings or if I can be of any further assistance, please contact me.

Tilde Rodrigues Froes, DMV, MSc., Dr. Med.Vet., Dipl.CBraRVet
info@sonopath.com