



PATIENT

Milo Kannan

SPECIES

Canine

BREED

Aust Cattle

SEX

Male Neutered

AGE

6Y, 2M

WEIGHT

55

INTERPRETED BY

Tilde Rodrigues Froes,
DMV, MSc., Dr. Med
Vet., Dipl. CBraRVet

IMAGING PERFORMED BY

Taren Denny LVT,
Amanda C

HOSPITAL NAME

Gentle Doctor Animal
Hospital

REFERRING VET

Nicholas Hayes

INVOICE

73179

DATE

1-5-26

PRESENTING CLINICAL SIGNS

chronic intermittent cough first diagnosed with kennel cough back on 11/10 and was not originally treated with any medications. came back a few weeks later for coughing and began steroids and antibiotics, finished and pet did not get better

RADIOGRAPHIC STUDY OF THE THORAX

Radiographs of the thorax in two imaging planes are provided for review totaling 3 images. One right lateral, one left lateral and one ventrodorsal view.

RADIOGRAPHIC FINDINGS

The thoracic trachea and esophagus are unremarkable.

The pulmonary parenchyma exhibits normal volume of expansion, and normal opacity, there is no evidence of abnormal opacities, pulmonary nodules or masses.

The cardiac silhouette is normal in size, shape and contour (VHS= 9.3, normal range). The pulmonary vasculature is within normal limits.

The pleural space, mediastinum, and diaphragm are within normal limits.

There is tiny incomplete bridging vertebral endplate spondylosis deformans at T5-6.

No significant abnormalities are identified in the collimated cranial abdomen.

RADIOGRAPHIC DIAGNOSIS

- Normal thoracic structures.

INTERPRETATION OF THE FINDINGS & FURTHER RECOMMENDATIONS

The radiographic findings demonstrate a normal thoracic examination, with no evidence of pulmonary pneumonia or other abnormalities that would account for the patient's current respiratory clinical signs.

The absence of radiographic abnormalities in the lungs does not completely exclude the possibility of inflammatory bronchitis, acute infectious disease, tracheitis, or canine infectious respiratory disease complex (CIRDC – kennel cough).



PATIENT

Milo Kannan

SPECIES

Canine

BREED

Aust Cattle

SEX

Male Neutered

AGE

6Y, 2M

WEIGHT

55

INTERPRETED BY

Tilde Rodrigues Froes,
DMV, MSc., Dr. Med
Vet., Dipl. CBraRVet

IMAGING PERFORMED BY

Taren Denny LVT,
Amanda C

HOSPITAL NAME

Gentle Doctor Animal
Hospital

REFERRING VET

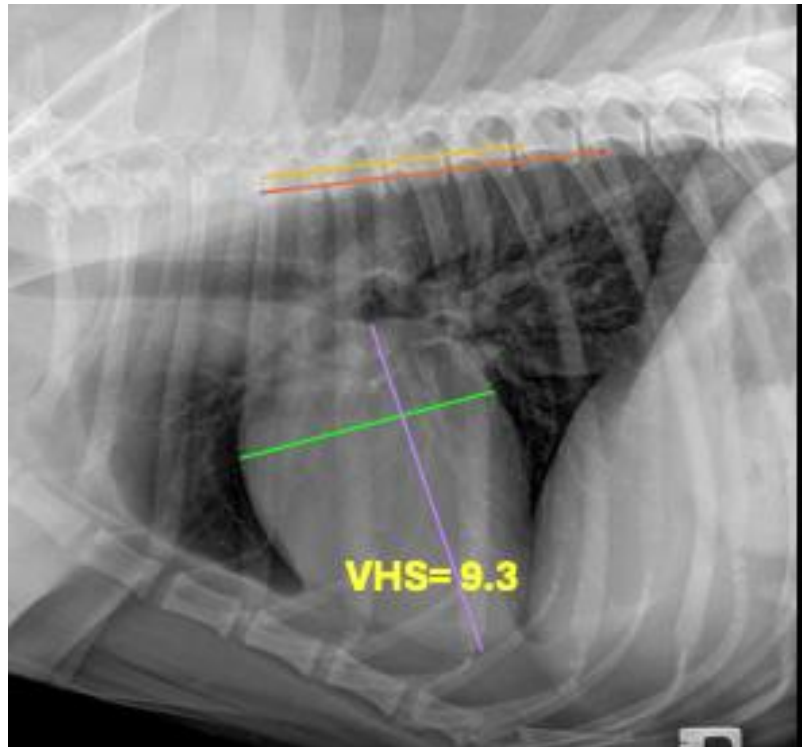
Nicholas Hayes

INVOICE

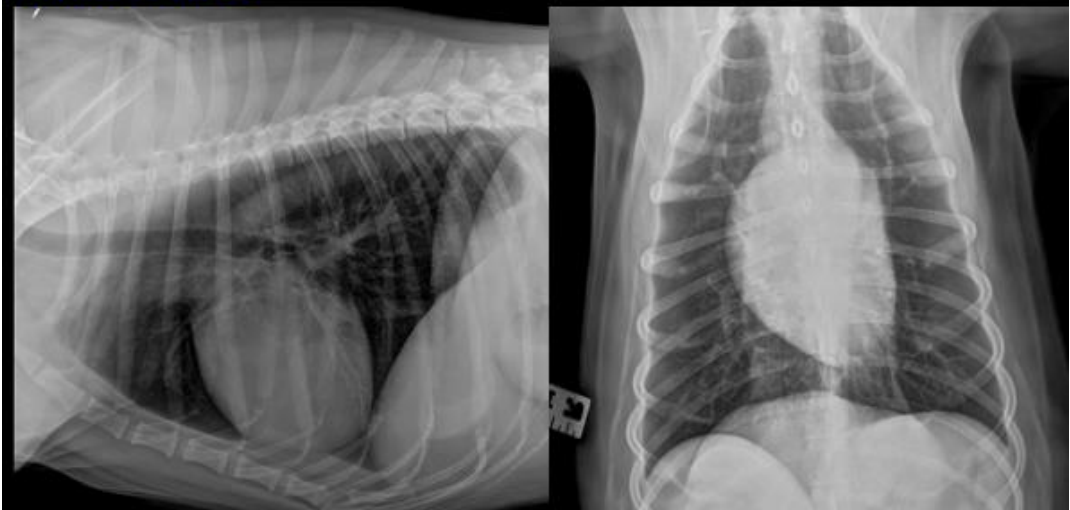
73179

DATE

1-5-26



Normal thorax





PATIENT

Milo Kannan

SPECIES

Canine

BREED

Aust Cattle

SEX

Male Neutered

AGE

6Y, 2M

WEIGHT

55

INTERPRETED BY

Tilde Rodrigues Froes,
DMV, MSc., Dr. Med
Vet., Dipl. CBraRVet

IMAGING PERFORMED BY

Taren Denny LVT,
Amanda C

HOSPITAL NAME

Gentle Doctor Animal
Hospital

REFERRING VET

Nicholas Hayes

INVOICE

73179

DATE

1-5-26

The information and recommendations provided are based on the images presented by the referring veterinarian. No evaluation can be communicated regarding pathology that was not visible in the image/video clips provided.

Thank you for this referral. If the clinical or image interpretation does not parallel your findings or if I can be of any further assistance, please contact me.

Tilde Rodrigues Froes, DMV, MSc., Dr. Med.Vet., Dipl.CBraRVet
info@sonopath.com