



PATIENT

Mattie Blanton

PRESENTING CLINICAL SIGNS

evidence of mass in left nare.

SPECIES

Canine

COMPUTED TOMOGRAPHIC STUDY OF THE SKULL

A non-contrast computed tomographic study evaluation of the head is provided for review.

BREED

Australian Shepherd

COMPUTED TOMOGRAPHIC FINDINGS

A focal, rounded, well-defined soft tissue attenuating mass abuts from the left rostral common nasal meatus and ventral nasal cartilage. It measures approximately 1.4cm x 1.0cm x 1.5cm, partially obstructing the rostral portion of the left nostril. The palatine process of the incisive bone adjacently is normal, with no evidence of bone involvement.

SEX

FS

The retropharyngeal lymph nodes are normal size.

The remainder of nasal cavities, nasal turbinates, and frontal sinus are unremarkable.

AGE

12 Years

The air column of the nasopharynx and larynx is normal.

The remaining bone structures of the head and face are normal.

Bilaterally, the mandible, maxilla, and all teeth are normal.

INTERPRETED BY

Tilde Rodrigues Froes,
DMV, MSc., Dr. Med
Vet., Dipl. CBraRVet

Bilaterally, the temporomandibular joints are congruent.

No other abnormalities are identified.

COMPUTED TOMOGRAPHIC DIAGNOSIS

- Solitary, small soft tissue mass within the rostral portion of the left nostril such as nasal neoplasm or inflammatory granuloma.
- No evidence of lymphadenopathy.
- No evidence of adjacent bone involvement

HOSPITAL NAME

Animal Medical
Center of Mt.
Pleasant

INTERPRETATION OF THE FINDINGS & FURTHER RECOMMENDATIONS

The differential diagnosis for the focal soft tissue lesion at the left rostral nasal includes nasal carcinoma, squamous cell carcinoma, lymphoma, or less likely inflammatory granuloma. No signs of concurrent regional inflammation. Biopsy is needed for a definitive diagnosis.

REFERRING VET

Dr. Steven Epstein

INVOICE

56011

DATE

1-5-23



PATIENT

Mattie Blanton

SPECIES

Canine

BREED

Australian Shepherd

SEX

FS

AGE

12 Years

INTERPRETED BY

Tilde Rodrigues Froes,
DMV, MSc., Dr. Med
Vet., Dipl. CBraRVet

HOSPITAL NAME

Animal Medical
Center of Mt.
Pleasant

REFERRING VET

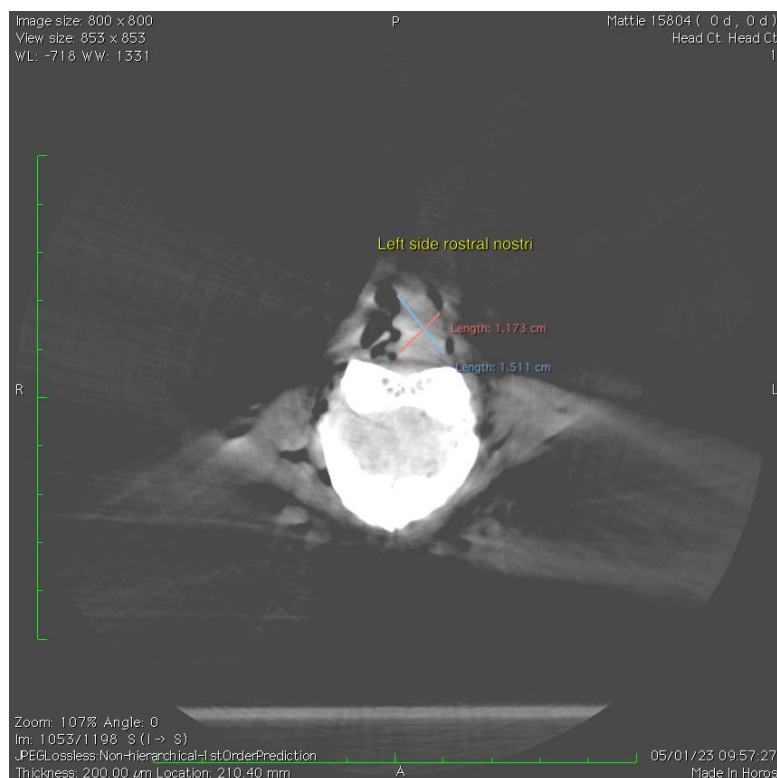
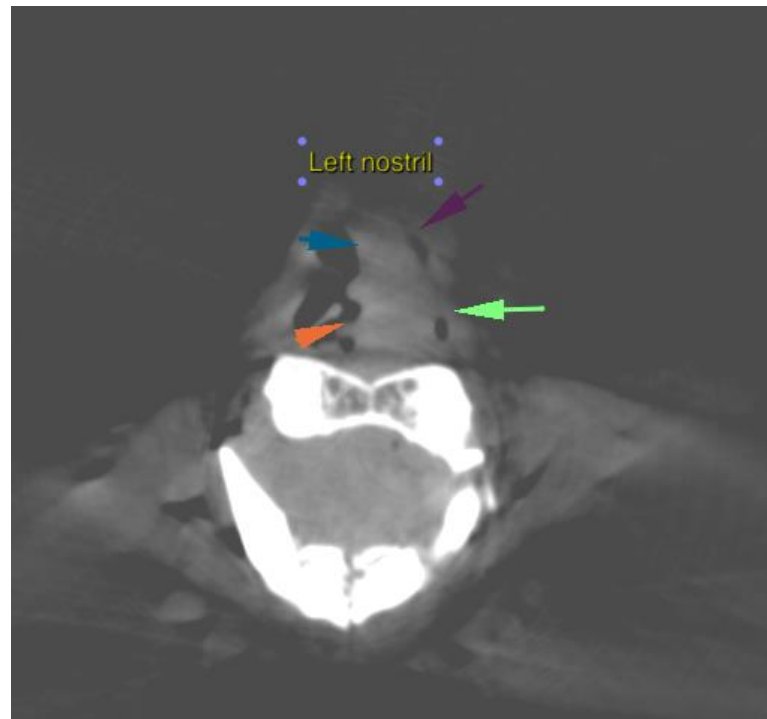
Dr. Steven Epstein

INVOICE

56011

DATE

1-5-23





PATIENT

Mattie Blanton

SPECIES

Canine

BREED

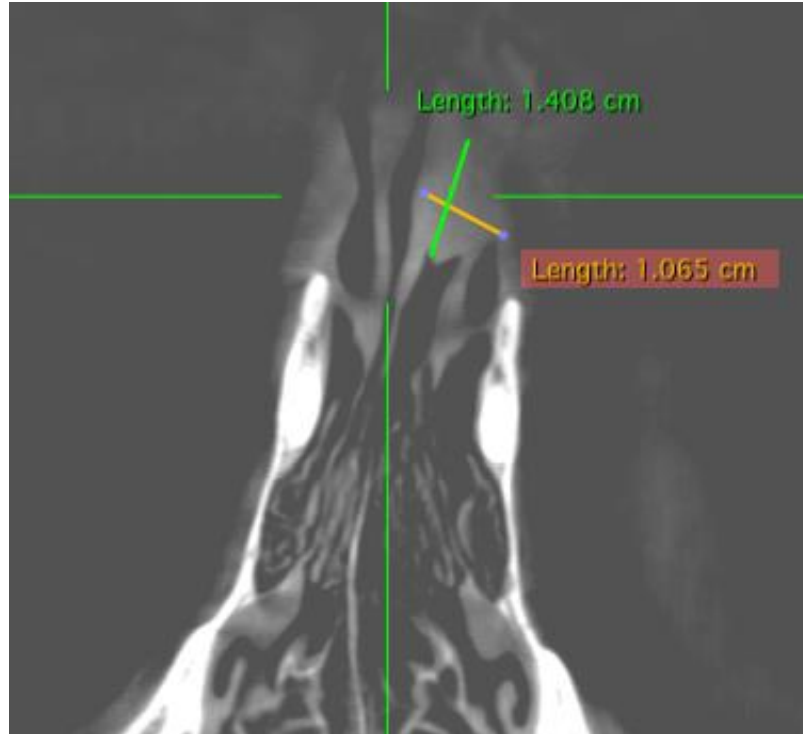
Australian Shepherd

SEX

FS

AGE

12 Years



INTERPRETED BY

Tilde Rodrigues Froes,
DMV, MSc., Dr. Med
Vet., Dipl. CBraRVet

The information and recommendations provided are based on the images presented by the referring veterinarian. No evaluation can be communicated regarding pathology that was not visible in the image/video clips provided.

Thank you for this referral. If the clinical or image interpretation does not parallel your findings or if I can be of any further assistance please contact me.

HOSPITAL NAME

Animal Medical
Center of Mt.
Pleasant

Tilde Rodrigues Froes, DMV, MSc., Dr. Med.Vet., Dipl.CBraRVet
info@sonopath.com

REFERRING VET

Dr. Steven Epstein

INVOICE

56011

DATE

1-5-23