



**PATIENT**

Zoey - Whitey  
Alexander

**SPECIES**

Feline

**BREED**

Persian

**SEX**

MN

**AGE**

15 Years

**INTERPRETED BY**

Tilde Rodrigues Froes,  
DMV, MSc., Dr. Med  
Vet., Dipl. CBraRVet

**HOSPITAL NAME**

State Avenue Vet  
Clinic

**REFERRING VET**

Dr. Raul Casas-Dolz

**INVOICE**

56478

**DATE**

1-31-23

**PRESENTING CLINICAL SIGNS**

01-29-2023 7:02:46pm Oral: rt upper premolar--inflamed, broken. Mucous membranes/CRT: Normal Eyes: Normal, medial canthus discharge staining Ears: Normal Cardiovascular: Normal Respiratory: Normal Abdomen: Normal Musculoskeletal: Normal Skin: Normal Lymph nodes: Normal Urogenital: Normal Neuro: No apparent abnormalities ABNORMAL: CT image--both middle ears have hyperechogenic image. Otic exam sedated--dark debris present at tympanic membrane. Rt ear TM appears intact. Left ear TM unable to visualize. see photos Broken upper rt premolar.

**COMPUTED TOMOGRAPHIC STUDY OF THE HEAD**

A head CT without contrast is provided for review.

**COMPUTED TOMOGRAPHIC FINDINGS**

There is mild diffuse wall thickening of the external ear canal bilaterally. Hypoattenuating material is completely filling the tympanic bullae, causing mild external expansion, and mild wall thickening; however, no evidence of lytic changes are seen. At least four ventral dependent otoliths associated with the hypoattenuating material within the left tympanic bulla are seen. There is no evidence of mass effect associated with the soft tissue fluid accumulation in the tympanic cavities. There is no evidence of external ear canal stenosis.

The nasopharynx and nasal cavities are normal.

Moderate horizontal and vertical bone loss is seen throughout the mandibular and maxillary arcades.

An irregular osteolytic lesion crosses over the 107 premolar maxillary crown; the root appears intact, however with demarcated geographic lesion. A more demarcated geographic lesion is evident adjacent to the tooth root of the 203 maxillary inciseive, and there is an irregular shape of the 201 maxillary inciseive.

The 108, 109, 208, and 209 teeth are absent.

No evidence of enlarged retropharyngeal lymph nodes.

No other abnormalities are identified.

**COMPUTED TOMOGRAPHIC DIAGNOSIS**

- Completed soft tissue attenuating material in tympanic bullae with mild wall thickening, and without lytic changes; differential diagnosis includes bilateral chronic otitis media.
- Concurrent microlithiases in left tympanic bulla.
- No evidence of mass effect.
- Mild thickening of the external ear canals, without polyps or masses.
- Diffuse periodontal disease. Complicated fracture with widened pulpa (pulpitis) and periapical bone lysis of the *triadan* 107 and 201. More exacerbated periodontal disease adjacent to the 203 tooth.
- Absent teeth - 108, 109, 208, and 209.



**PATIENT**

Zoey - Whitey  
Alexander

**SPECIES**

Feline

**BREED**

Persian

**SEX**

MN

**AGE**

15 Years

**INTERPRETED BY**

Tilde Rodrigues Froes,  
DMV, MSc., Dr. Med  
Vet., Dipl. CBraRVet

**HOSPITAL NAME**

State Avenue Vet  
Clinic

**REFERRING VET**

Dr. Raul Casas-Dolz

**INVOICE**

56478

**DATE**

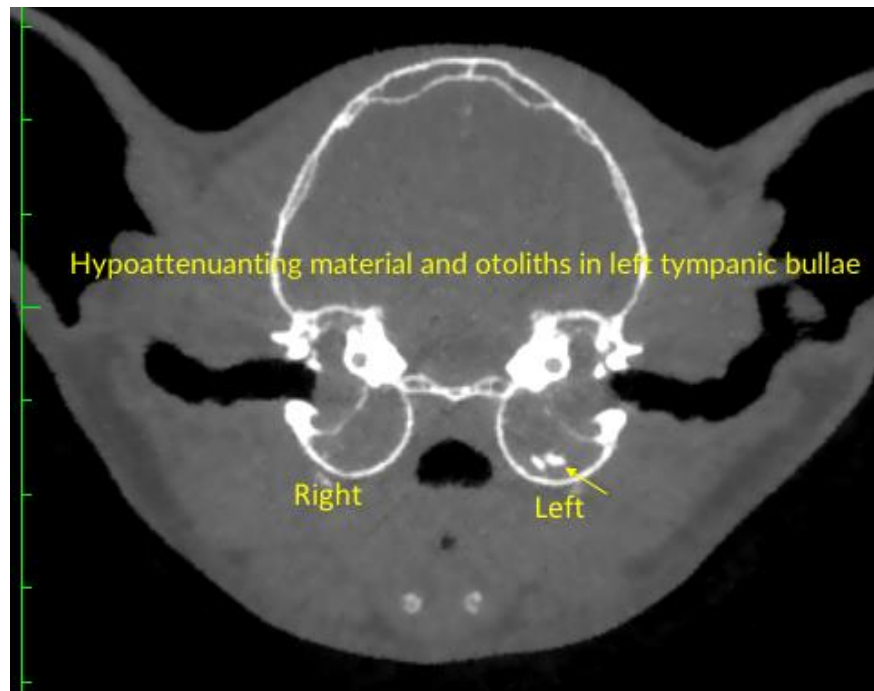
1-31-23

**INTERPRETATION OF THE FINDINGS & FURTHER RECOMMENDATIONS**

The tomographic findings of the middle ear apparatus are correlated to the patient's history. No evidence of mass or polypoid lesions into the ear canal. The microlithiasis within the left tympanic bulla indicate chronicity of the material content. The sensitivity of computed tomography to see the integrity of the tympanic membrane is low.

Moderate periodontal disease, and oronasal fistula cannot be completely excluded. Correlation with oral/dental exam is suggested.

Fracture of the 107 tooth correlates to the patient history, consider an extraction of this tooth.





**PATIENT**

Zoey - Whitey  
Alexander

**SPECIES**

Feline

**BREED**

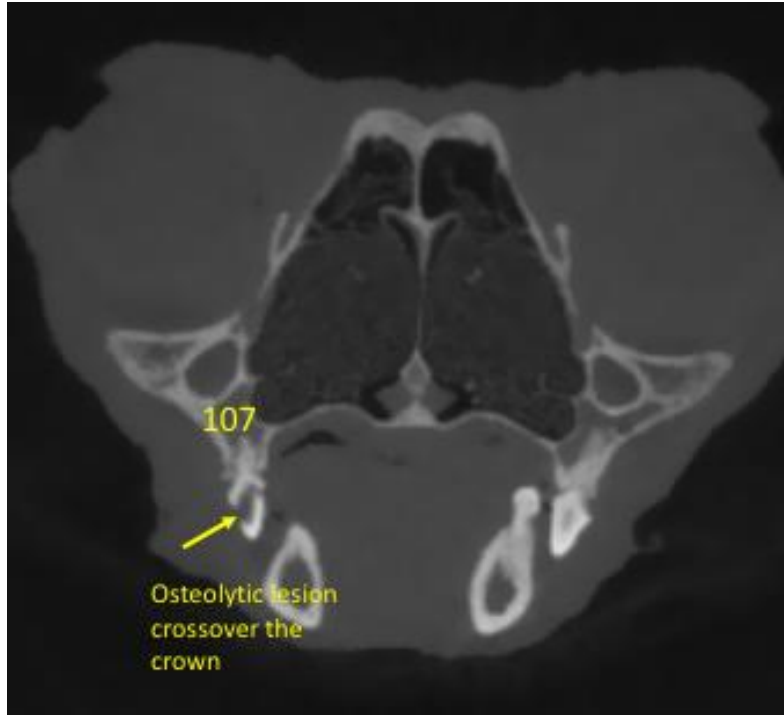
Persian

**SEX**

MN

**AGE**

15 Years



**INTERPRETED BY**

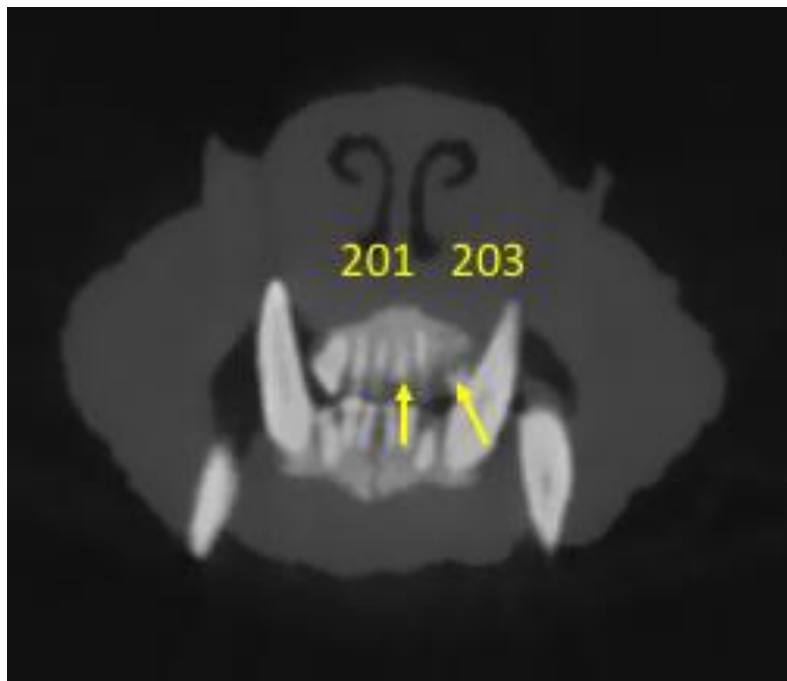
Tilde Rodrigues Froes,  
DMV, MSc., Dr. Med  
Vet., Dipl. CBraRVet

**HOSPITAL NAME**

State Avenue Vet  
Clinic

**REFERRING VET**

Dr. Raul Casas-Dolz



**INVOICE**

56478

**DATE**

1-31-23



**PATIENT**

Zoey - Whitey  
Alexander

The information and recommendations provided are based on the images presented by the referring veterinarian. No evaluation can be communicated regarding pathology that was not visible in the image/video clips provided.

**SPECIES**

Feline

Thank you for this referral. If the clinical or image interpretation does not parallel your findings or if I can be of any further assistance please contact me.

**BREED**

Persian

**Tilde Rodrigues Froes, DMV, MSc., Dr. Med.Vet., Dipl.CBraRVet**  
info@sonopath.com

**SEX**

MN

**AGE**

15 Years

**INTERPRETED BY**

Tilde Rodrigues Froes,  
DMV, MSc., Dr. Med  
Vet., Dipl. CBraRVet

**HOSPITAL NAME**

State Avenue Vet  
Clinic

**REFERRING VET**

Dr. Raul Casas-Dolz

**INVOICE**

56478

**DATE**

1-31-23