



PATIENT

Nala Sanchez

SPECIES

Canie

BREED

Dachshund

SEX

SF

AGE

7Y

WEIGHT

21lbs

INTERPRETED BY

Tilde Rodrigues Froes,
DMV, MSc., Dr. Med
Vet., Dipl. CBraRVet

IMAGING PERFORMED BY

Alondra Aviles Lopez
VT

HOSPITAL NAME

Veterinary Image
Center

REFERRING VET

Dr. Colon, DVM

INVOICE

73530

DATE

1-29-26

PRESENTING CLINICAL SIGNS

History:

- Patient presented for a CT scan Hx of HL ataxia.

Abnormal PE/Chem/CBC/UA Results: CBC: WNL CHEM: CA 12.0 8.6-11.8 mg/dL

COMPUTED TOMOGRAPHIC STUDY OF THE THORACIC AND LUMBAR SPINE

A pre- and post-contrast computed tomographic examination of the cervical, thoracic, and lumbar spine was provided for review. Two series were obtained, including one pre-contrast and one post-contrast acquisitions. Images were reconstructed in the transverse plane using bone algorithms.

COMPUTED TOMOGRAPHIC FINDINGS

SPINE

A normal number of vertebral bodies is present (C1–C7, T1–T13, L1–L7, sacrum, and caudal vertebrae).

Vertebral alignment is normal throughout the cervical, thoracic, and lumbar spine.

At the L2–L3 intervertebral level, there is a moderate to marked amount of ventrally located, slightly hyperattenuating extradural material within the vertebral canal. The material demonstrates contrast enhancement on the post-contrast series and is better delineated in this phase. The lesion results in moderate spinal cord compression. The material has an oval configuration.

At the L4–L5 level, a mild amount of slightly hyperattenuating extradural material is present, causing discrete spinal cord compression.

Multiple small in situ mineralized foci are observed within several intervertebral disc spaces along the spine.

Vertebral bodies show homogeneous osseous attenuation, smooth cortical margins, and normal size and shape.

The paraspinal musculature is symmetric, with normal volume and attenuation.

The collimated portions of the thorax and abdomen are unremarkable.

COMPUTED TOMOGRAPHIC DIAGNOSIS

- L2–L3: Moderate to marked, slightly hyperattenuating extradural material causing moderate spinal cord compression. The material demonstrates peripheral contrast enhancement and is better delineated on post-contrast images. Findings are most consistent with intervertebral disc herniation associated with compressive myelopathy. Despite this atypical enhancement pattern, neoplasia is considered a less likely differential diagnosis.
- L4–L5: Mild extradural hyperattenuating material resulting in discrete spinal cord compression, compatible with mild intervertebral disc herniation.



PATIENT

- Multifocal intervertebral disc mineralization, consistent with chondroid disc degeneration.

Nala Sanchez

INTERPRETATION OF THE FINDINGS & FURTHER RECOMMENDATIONS

SPECIES

The tomographic findings identify moderate to marked, slightly hyperattenuating extradural material at the L2–L3 level resulting in moderate spinal cord compression. The material demonstrates peripheral contrast enhancement and is better delineated on post-contrast images. These findings are most consistent with intervertebral disc herniation associated with compressive myelopathy. Despite the atypical enhancement pattern, neoplasia is considered a less likely differential diagnosis.

Canie

BREED

A second, milder compressive lesion is present at L4–L5.

Dachshund

SEX

Correlation with a complete neurological examination is recommended to assist in determining the most appropriate treatment approach.

SF

AGE

TECHNICAL COMMENTS

7Y

The lateral markers are shifted.

WEIGHT

21lbs

INTERPRETED BY

Tilde Rodrigues Froes,
DMV, MSc., Dr. Med
Vet., Dipl. CBraRVet

**IMAGING
PERFORMED BY**

Alondra Aviles Lopez
VT

HOSPITAL NAME

Veterinary Image
Center

REFERRING VET

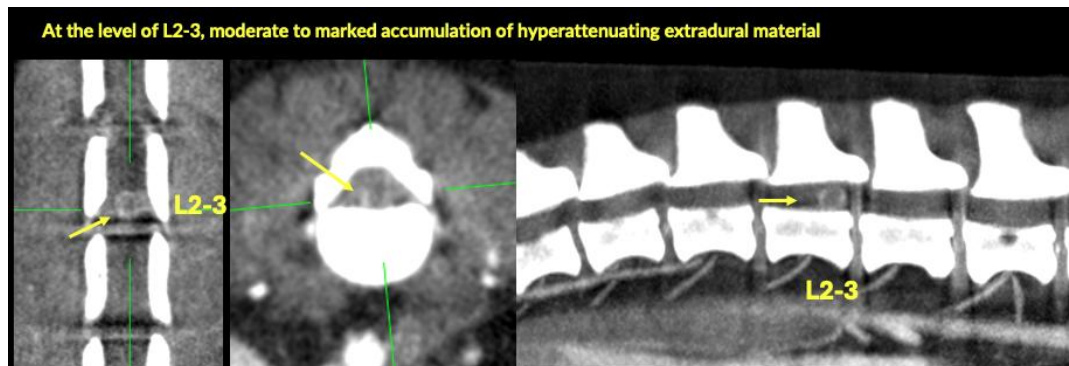
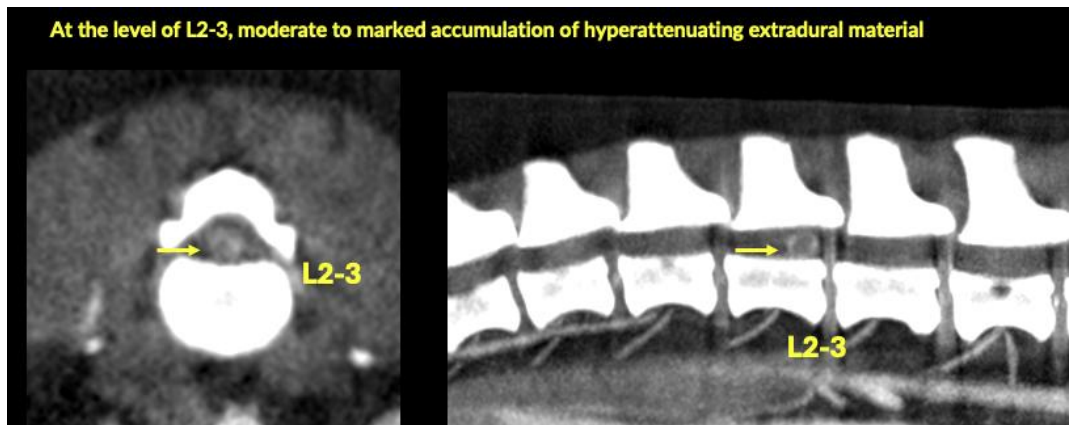
Dr. Colon, DVM

INVOICE

73530

DATE

1-29-26





PATIENT

Nala Sanchez

SPECIES

Canine

BREED

Dachshund

SEX

SF

AGE

7Y

WEIGHT

21lbs

INTERPRETED BY

Tilde Rodrigues Froes,
DMV, MSc., Dr. Med
Vet., Dipl. CBraRVet

IMAGING PERFORMED BY

Alondra Aviles Lopez
VT

HOSPITAL NAME

Veterinary Image
Center

REFERRING VET

Dr. Colon, DVM

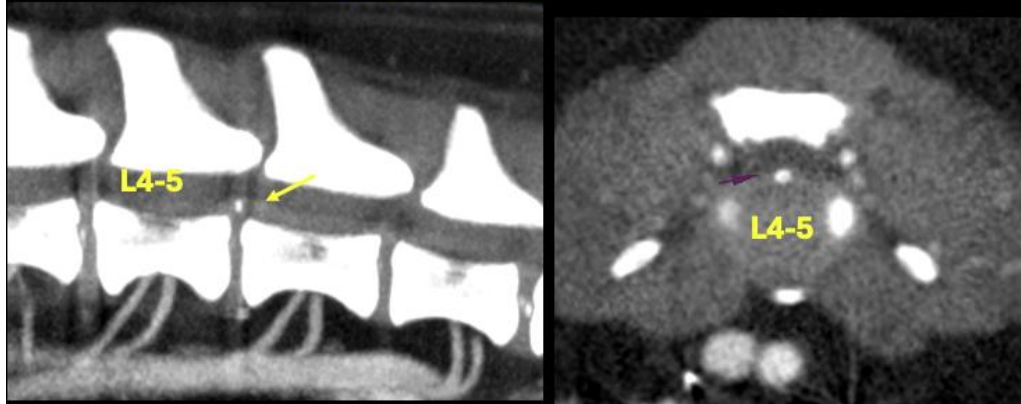
INVOICE

73530

DATE

1-29-26

At the L4-L5 level, a mild amount of slightly hyperattenuating extradural material



The information and recommendations provided are based on the images presented by the referring veterinarian. No evaluation can be communicated regarding pathology that was not visible in the image/video clips provided.

Thank you for this referral. If the clinical or image interpretation does not parallel your findings or if I can be of any further assistance, please contact me.

Tilde Rodrigues Froes, DMV, MSc., Dr. Med.Vet., Dipl.CBraRVet
info@sonopath.com