



**PATIENT PRESENTING CLINICAL SIGNS**

Abi Katzer Abi is a 2 year old spayed coonhound dog who has history of vomiting and decreased appetite for the last two days. She is a kind of dog that likes to eat everything

**SPECIES RADIOGRAPHIC STUDY OF THE ABDOMEN**

Canine Orthogonal views of the abdomen and collimated thorax are provided for review totaling 6 images.

**BREED RADIOGRAPHIC FINDINGS**

Coonhound The stomach is moderately filled with gas admixed with soft tissue opaque fluid material, heterogeneous soft tissue ingesta, and mobile traces of mineral opaque foreign material, which redistributes normally with changes in the patient's position.

**SEX** The small intestinal loops are mainly gas filled; some loops have granular mineralized content. There is no evidence of enlarged intestinal loops or segmental dilation.

Spayed Female The ileocolic junction is normal in position, with gas and a very small portion of granular mineralized content.

**AGE** The descending colon contains a moderate amount of heterogeneous soft tissue opaque fecal material admixed with gas and traces of mineral opaque foreign material.

2 Years No signs of gastrointestinal mechanical obstruction are seen.

**INTERPRETED BY** The abdominal serosal detail is normal.

Tilde Rodrigues Froes, DMV, MSc., Dr. Med Vet., Dipl. CBraRVet The liver, spleen, and renal silhouettes are normal in size, shape, and contour.

The urinary bladder is empty.

**HOSPITAL NAME** The collimated thorax is normal.

Beaches-Fallingbrook Veterinary Clinic No other abnormalities are identified.

**RADIOGRAPHIC DIAGNOSIS**

- Non-obstructive gastrointestinal gravel like material. Differential diagnosis, traces of bones or other foreign material.
- Traces of mineral foreign material in the descending colon, consistent with small bits of gravel and likely to pass without incident.
- Otherwise, normal abdomen and colon.

**REFERRING VET**

Dr Sam Shahsavari

**INVOICE INTERPRETATION OF THE FINDINGS & FURTHER RECOMMENDATIONS**

56252 No evidence of gastrointestinal mechanical obstruction. A concurrent nonobstructive gastroenteritis and colitis correlate to dietary indiscretion. Other differential diagnosis includes inflammatory disease, and less likely infectious disease. Recommend supportive care and repeat abdominal imaging, ultrasound, or radiographs, if patient fails to improve or worsens.

**DATE**

1-19-23



**PATIENT**

Abi Katzer

**SPECIES**

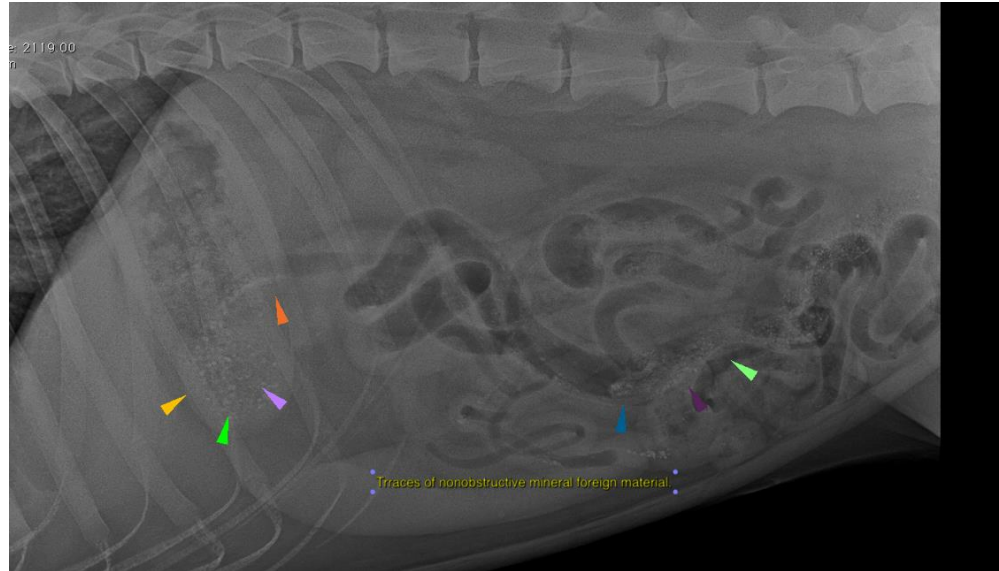
Canine

**BREED**

Coonhound

**SEX**

Spayed Female



**AGE**

2 Years

**INTERPRETED BY**

Tilde Rodrigues Froes,  
DMV, MSc., Dr. Med  
Vet., Dipl. CBraRVet

**HOSPITAL NAME**

Beaches-Fallingbrook  
Veterinary Clinic

**REFERRING VET**

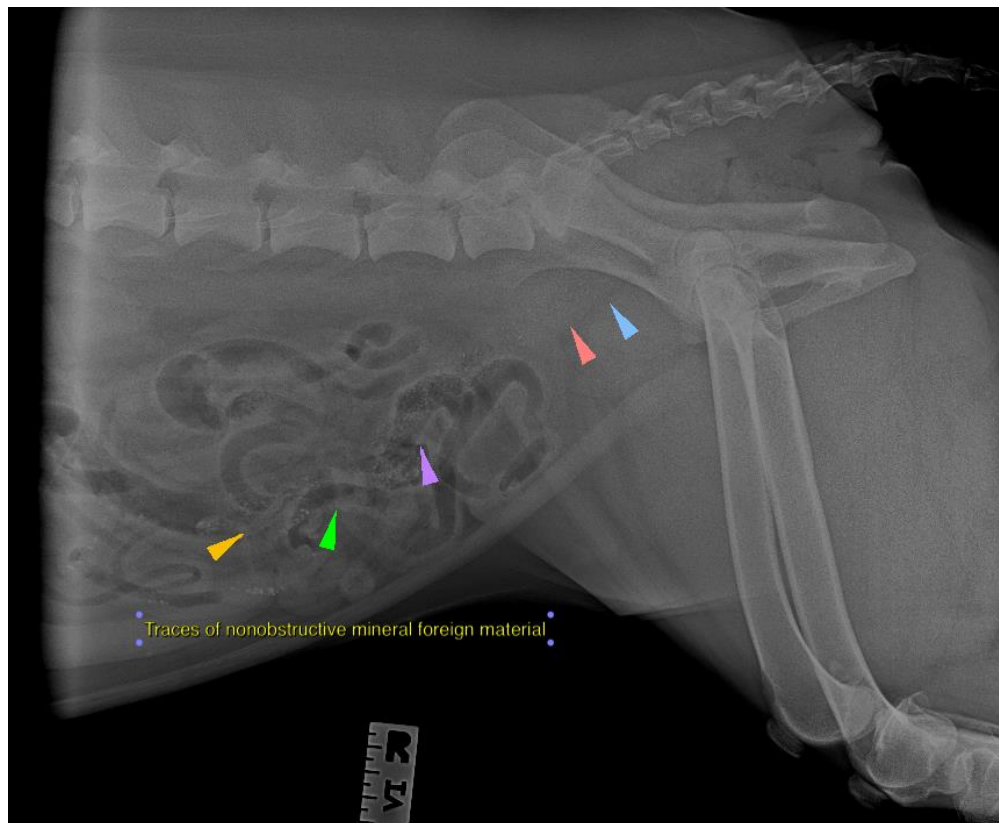
Dr Sam Shhsavari

**INVOICE**

56252

**DATE**

1-19-23





**PATIENT**

Abi Katzer

The information and recommendations provided are based on the images presented by the referring veterinarian. No evaluation can be communicated regarding pathology that was not visible in the image/video clips provided.

**SPECIES**

Canine

Thank you for this referral. If the clinical or image interpretation does not parallel your findings or if I can be of any further assistance please contact me.

**BREED**

Coonhound

**Tilde Rodrigues Froes, DMV, MSc., Dr. Med.Vet., Dipl.CBraRVet**  
info@sonopath.com

**SEX**

Spayed Female

**AGE**

2 Years

**INTERPRETED BY**

Tilde Rodrigues Froes,  
DMV, MSc., Dr. Med  
Vet., Dipl. CBraRVet

**HOSPITAL NAME**

Beaches-Fallingbrook  
Veterinary Clinic

**REFERRING VET**

Dr Sam Shavsavari

**INVOICE**

56252

**DATE**

1-19-23