



**PATIENT PRESENTING CLINICAL SIGNS**

Shyla Bowers  
Coughing, Overweight, Increased respiratory efforts  
Abnormal PE/Chem/CBC/UA Results: Bloodwork Pending

**SPECIES RADIOGRAPHIC STUDY OF THE THORAX AND COLLIMATED ABDOMEN (WHOLE BODY)**

Feline Radiographs of the thorax and collimated abdomen, in one imaging plane is provided for review.

**RADIOGRAPHIC FINDINGS**

**BREED** The trachea is normal.

Domestic Short Hair A moderate bronchial pattern with peribronchial cuffing by soft tissue opaque material is noted throughout all lung lobes.

**SEX** The cardiac silhouette is of normal to minimally increased overall size with moderate pericardial fat. The visible pulmonary vasculature is normal.

Female Spayed The pleural space and mediastinum are normal.

**AGE** The liver and renal silhouettes are normal in size, shape, contour, and opacity.

10 Years The stomach is moderately distended and predominately gas filled.

The intestines are of normal size and diameter, respectively, and are normally positioned.

**INTERPRETED BY** The colon contains gas admixed with heterogeneous soft tissue opaque fecal material.

Tilde Rodrigues Froes, DMV, MSc., Dr. Med Vet., Dipl. CBraRVet  
The remainder abdomen is normal.

The abdominal serosal detail is normal.

**HOSPITAL NAME** No other abnormalities are identified.

New Bridge Veterinary Practice Abundant fat stores are seen in the subcutaneous tissues, pericardium, and throughout the abdomen.

The musculoskeletal structures are unremarkable.

**REFERRING VET RADIOGRAPHIC DIAGNOSIS**

- Dr. Abina Glennon
- Moderate generalized bronchial pattern with tree in bud appearance, differential diagnosis includes allergic lower airway disease, chronic bronchitis, infectious bronchitis.
  - Normal heart with pericardial fat. Other differential diagnosis includes less likely mild cardiomegaly (e.g., compensated nonspecific cardiomyopathy).
  - Gastric air dilatation, possible aerophagy.
  - Otherwise, normal abdomen.

**INVOICE**

56231

**DATE**

1-18-23



**PATIENT**

Shyla Bowers

**SPECIES**

Feline

**BREED**

Domestic Short Hair

**SEX**

Female Spayed

**AGE**

10 Years

**INTERPRETED BY**

Tilde Rodrigues Froes,  
DMV, MSc., Dr. Med  
Vet., Dipl. CBraRVet

**HOSPITAL NAME**

New Bridge  
Veterinary Practice

**REFERRING VET**

Dr. Abina Glennon

**INVOICE**

56231

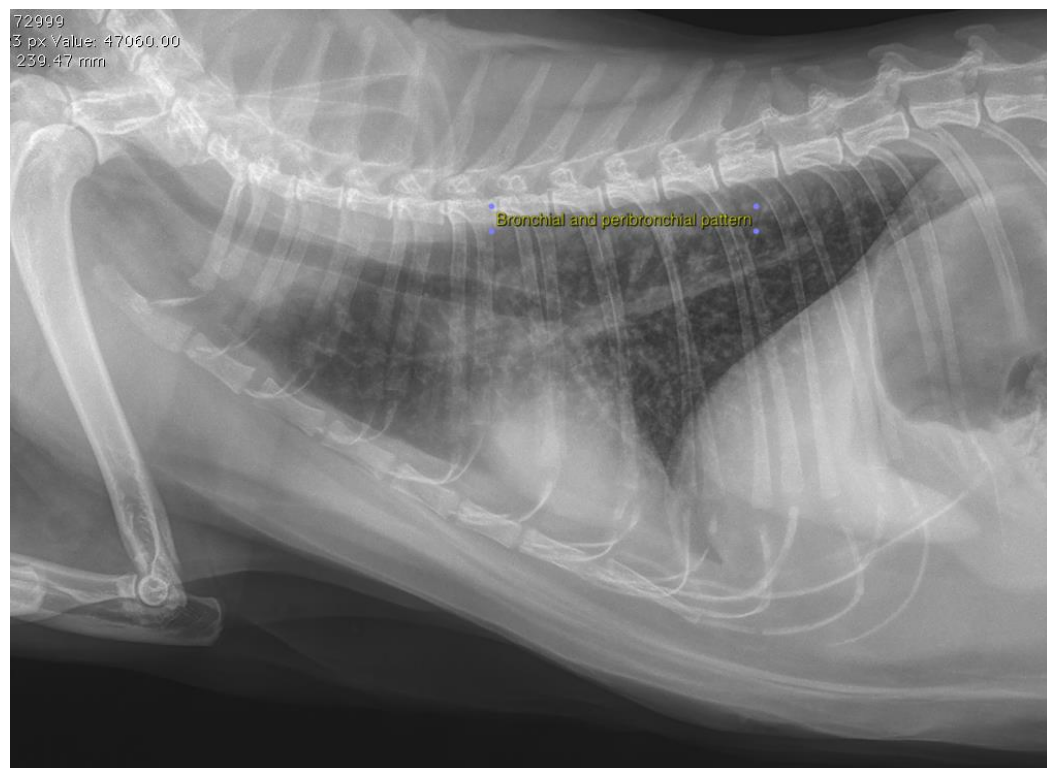
**DATE**

1-18-23

**INTERPRETATION OF THE FINDINGS & FURTHER RECOMMENDATIONS**

The pulmonary radiographic findings are correlated to the patient's history of coughing and increased respiratory efforts. Medical therapy is suggested. If the patient does not improve, a bronchoalveolar lavage may be useful in obtaining samples for cytology, culture, and sensitivity.

If cardiac murmur is detected, an echocardiography may be useful in the further evaluation of the cardiac function and because of the overall mild enlargement. However, that could be correlated to the patient being overweight.



The information and recommendations provided are based on the images presented by the referring veterinarian. No evaluation can be communicated regarding pathology that was not visible in the image/video clips provided.

Thank you for this referral. If the clinical or image interpretation does not parallel your findings or if I can be of any further assistance please contact me.

**Tilde Rodrigues Froes, DMV, MSc., Dr. Med.Vet., Dipl.CBraRVet**  
info@sonopath.com