



PATIENT PRESENTING CLINICAL SIGNS

Sam Flay firm ventral thoracic mass on chest noted 2-3 months, growing steadily, initially 3.5 cm, does not cause discomfort. FNA performed revealing mast cell tumour, multiple masses note don physical exam Hx 0.5 cm ulcerated right forelimb paw mass excision April 2018 (Mild pleocellular hyperplastic dermatitis with dermal fibrosis/granulation tissue response)

SPECIES

Canine

COMPUTED TOMOGRAPHIC STUDY OF THORAX AND ABDOMEN

Two high-resolution plain CT studies of the thorax and abdomen are provided for review.

BREED

Lab

COMPUTED TOMOGRAPHIC FINDINGS

THORAX

SEX

A rounded, well-defined, soft tissue attenuating subcutaneous mass is seen along the ventral border of the thoracic abdominal transition region (xiphoid region) measuring approximately 9.1cm x 6.0cm x 8.1cm. Also, mild soft tissue stranding of subcutaneous fat is seen adjacently.

MN

AGE

11 Years

A large, well-defined ovoid shaped soft tissue attenuating mass spans the first to third sternebra ventrally within the cranial mediastinum and measures approximately 7.1cm x 4.6cm x 5.3cm. Within the cranial mediastinum are multiple, variably sized, rounded to ovoid structures with the largest measuring approximately 3.3cm x 2.7cm.

Moderate bilateral dorsally dependent soft tissue attenuating pleural effusion is present and most evident in one third of the caudal thoracic cavity.

INTERPRETED BY

Tilde Rodrigues Froes, DMV, MSc., Dr. Med Vet., Dipl. CBraRVet

The bilateral axillary and accessory axillary lymph nodes are markedly enlarged and homogeneously soft tissue attenuating. The largest measures approximately 3.6cm x 4.1cm on the left side and 2.5cm x 3.9cm on the right side.

The lung lobes are reduced in volume dorsally in consequence of passive atelectasis.

HOSPITAL NAME

Animal Health Partners

There are a few mineral opaque foci that are less than 2mm in diameter and are superimposed over the periphery of the lungs. No mass effect or soft tissue nodules are detected.

ABDOMEN

REFERRING VET

Dr. Lea Mehrkens

The liver is homogeneously soft tissue attenuating with normal shape and contour.

The gallbladder is unremarkable.

The spleen is diffusely enlarged, homogeneously soft tissue attenuating, and of normal shape and contour.

INVOICE

56226

The renal silhouettes are normal in size, shape, contour, and attenuation. The renal length is 7.1cm in the right kidney and 7.7cm in the left kidney.

DATE

1-18-23

The stomach is moderately filled and normally positioned, containing gas admixed with heterogenous soft tissue attenuating material – food, with gas.



PATIENT

Sam Flay

The duodenum and small intestine are nondilated and contain a minimal amount of fluid, scant amount of fine mineral attenuating material, and gas.

SPECIES

Canine

The colon and rectum contain gas admixed with soft tissue and mineral attenuating fecal material.

The pancreas and mesentery are normal.

The abdominal lymph nodes and adrenal glands are normal.

BREED

Lab

The urinary bladder is moderately filled, with the apex in the plane of L6, and is homogeneously soft tissue opaque.

The prostate is reduced in size, normal in castrated patient.

SEX

MN

The attenuation of the abdominal fat and retroperitoneal fat are normal.

Multifocal lumbar and lumbosacral intervertebral disc space are mildly narrowed, and complete or incomplete bridging spondylosis deformans.

AGE

11 Years

Mild periarticular ossification is seen at the caudal aspect of both shoulders.

At least three small sized, subcutaneous soft tissue attenuating nodules are seen around the body with one measuring 0.84cm and located at the left thoracic wall (Serie 3 Im.250/639), one measuring 1.2cm and situated ventrally in the left limb (Serie 3 Im. 546/639), and one measuring 0.91cm situated in right side of the caudal abdominal wall (Serie 3 Im 487/639).

INTERPRETED BY

Tilde Rodrigues Froes,
DMV, MSc., Dr. Med
Vet., Dipl. CBraRVet

COMPUTED TOMOGRAPHIC DIAGNOSIS

- Soft tissue attenuating mass in the xiphoid topographic region, mast cell tumor and soft tissue sarcoma are the most likely differential diagnoses.
- Regional edema, inflammation, or mild hemorrhage adjacently.
- Cranial mediastinal, sternal, and axillary lymphadenopathy consistent with neoplastic process, such as metastatic disease. Differential diagnosis: cutaneous mast cell tumor with lymph node involvement and/or less likely bone marrow, other neoplasm such as round cell tumor, or other metastatic disease.
- Bilateral pleural effusion, inflammatory or metastatic.
- Pulmonary osteomas, incidental.
- Splenomegaly. Differential diagnosis: metastatic mast cell tumor infiltration, lymphoid hyperplasia, hematopoiesis, or correlated to anesthesia procedure.
- Mild bilateral shoulder osteoarthritis - incidental finding.
- Multifocal chronic lumbar and lumbosacral intervertebral disc disease and spondylosis deformans.
- At least three subcutaneous attenuating nodules along the body (thoracic and abdominal wall and ventrally adjacent to the left pelvic limb). Differential diagnosis: metastatic cutaneous lesions and less likely granuloma.

HOSPITAL NAME

Animal Health
Partners

REFERRING VET

Dr. Lea Mehrkens

INVOICE

56226

DATE

1-18-23



PATIENT **INTERPRETATION OF THE FINDINGS & FURTHER RECOMMENDATIONS**

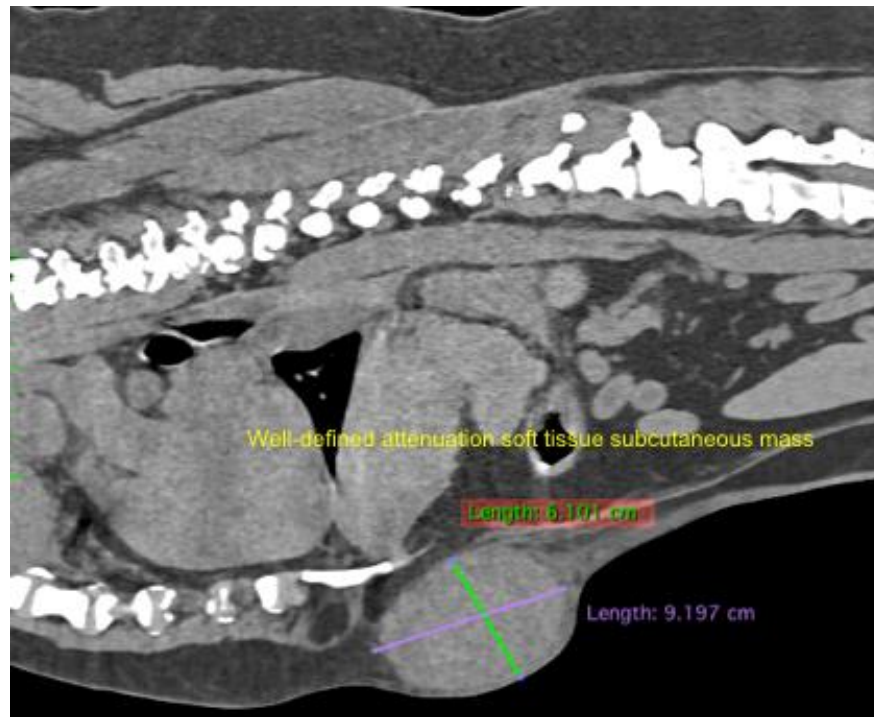Sam Flay The thoracic tomographic findings suggest aggressive metastatic disease likely correlated to the previous diagnosis of cutaneous mast cell tumor. A diagnosis and therapeutic thoracocentesis is suggested.

SPECIES
Canine Fine needle aspirates or excisional biopsy of the subcutaneous mass and enlarged axillary lymph nodes is suggested.

BREED
Lab Evaluation of the smaller subcutaneous nodules, and if attainable, a fine needle aspirates is suggested.

SEX
MN It is uncommon for a cutaneous mast cell tumor to be associated with bone marrow involvement; however, it is possible. Correlation with laboratory abnormalities and potential bone marrow aspiration for staging in the future are both proposed. Consultation with an oncology specialist is suggested.

AGE
11 Years



INTERPRETED BY

Tilde Rodrigues Froes, DMV, MSc., Dr. Med Vet., Dipl. CBraRVet

HOSPITAL NAME

Animal Health Partners

REFERRING VET

Dr. Lea Mehrkens

INVOICE

56226

DATE

1-18-23



PATIENT

Sam Flay

SPECIES

Canine

BREED

Lab

SEX

MN

AGE

11 Years

INTERPRETED BY

Tilde Rodrigues Froes,
DMV, MSc., Dr. Med
Vet., Dipl. CBraRVet

HOSPITAL NAME

Animal Health
Partners

REFERRING VET

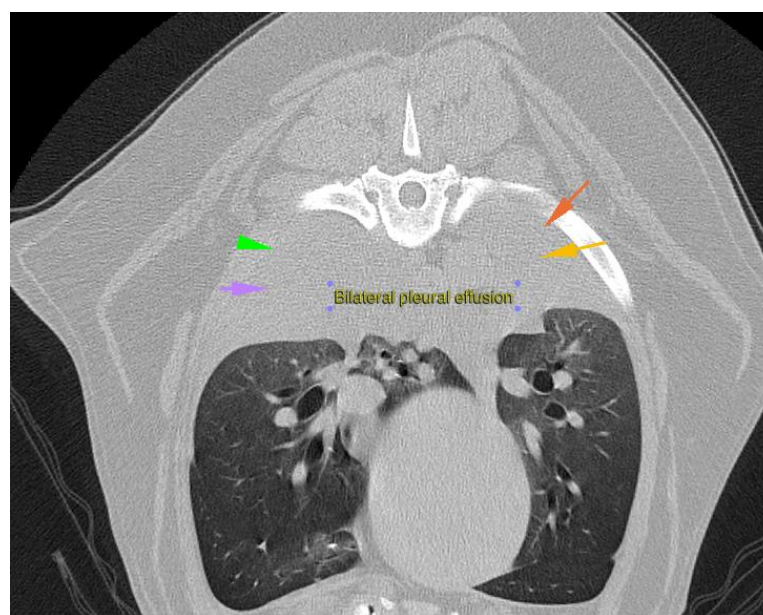
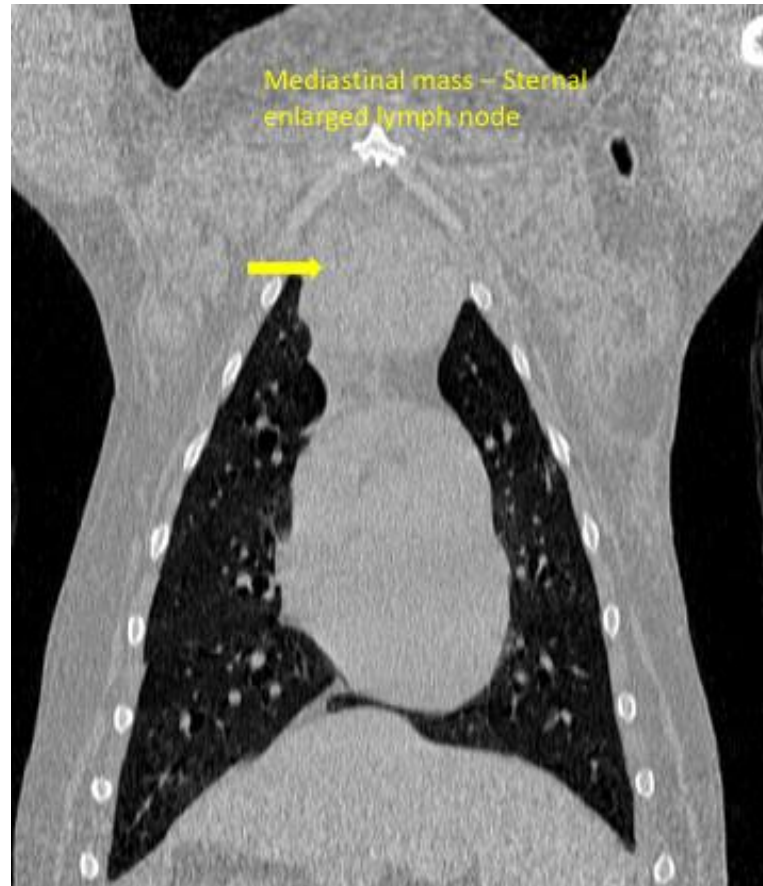Dr. Lea Mehrkens

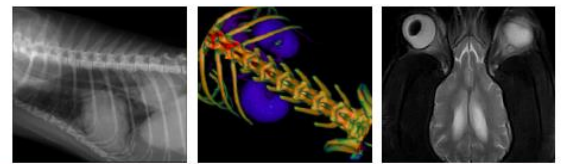
INVOICE

56226

DATE

1-18-23





PATIENT

Sam Flay

SPECIES

Canine

BREED

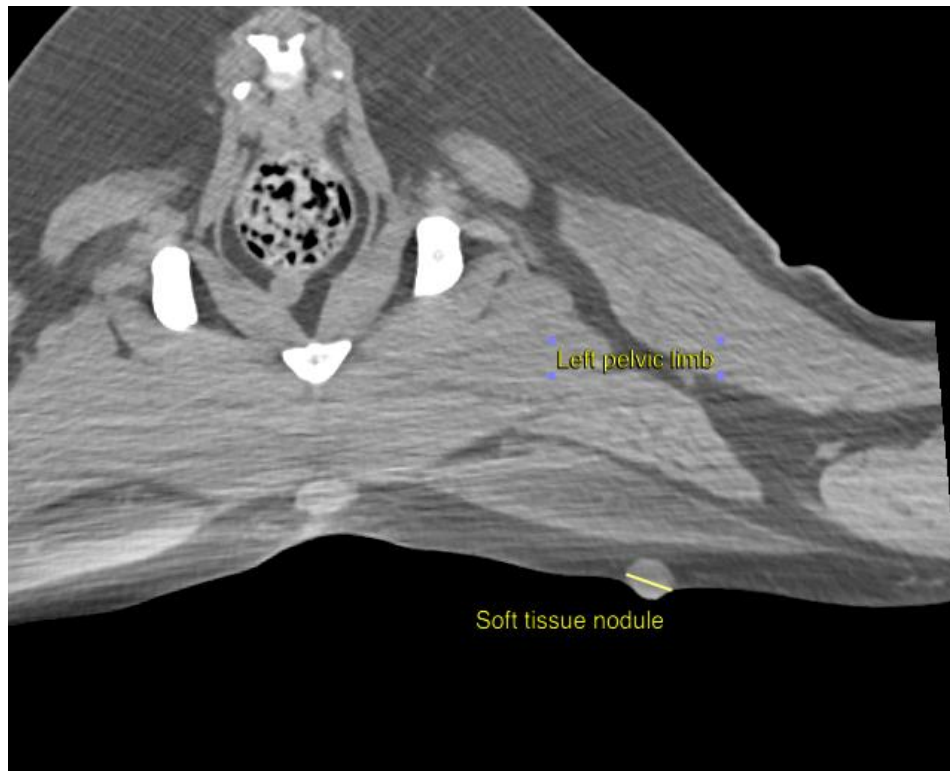
Lab

SEX

MN

AGE

11 Years



INTERPRETED BY

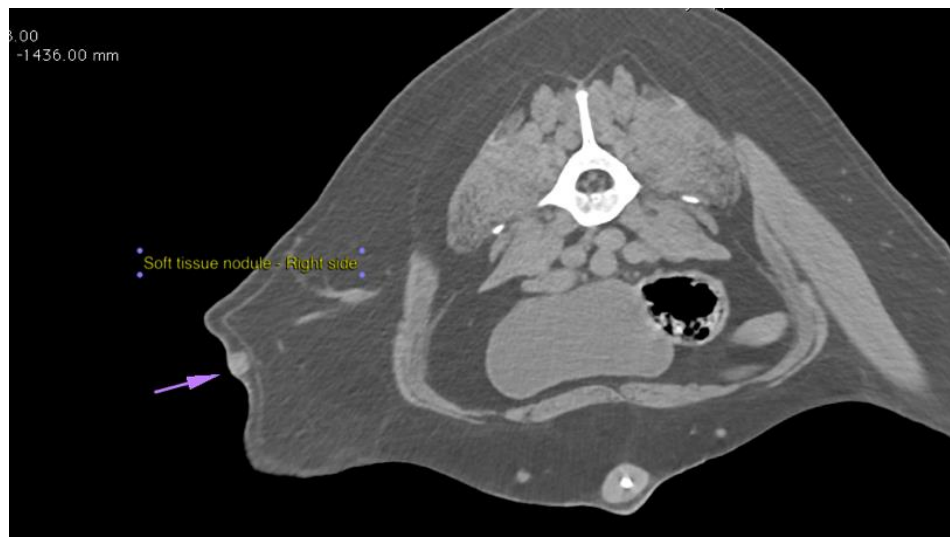
Tilde Rodrigues Froes,
DMV, MSc., Dr. Med
Vet., Dipl. CBraRVet

HOSPITAL NAME

Animal Health
Partners

REFERRING VET

Dr. Lea Mehrkens

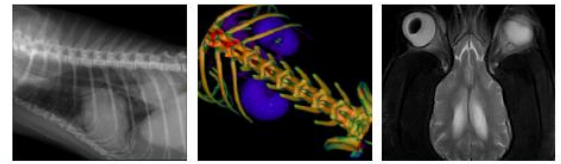


INVOICE

56226

DATE

1-18-23



PATIENT

Sam Flay

The information and recommendations provided are based on the images presented by the referring veterinarian. No evaluation can be communicated regarding pathology that was not visible in the image/video clips provided.

SPECIES

Canine

Thank you for this referral. If the clinical or image interpretation does not parallel your findings or if I can be of any further assistance please contact me.

BREED

Lab

Tilde Rodrigues Froes, DMV, MSc., Dr. Med.Vet., Dipl.CBraRVet
info@sonopath.com

SEX

MN

AGE

11 Years

INTERPRETED BY

Tilde Rodrigues Froes,
DMV, MSc., Dr. Med
Vet., Dipl. CBraRVet

HOSPITAL NAME

Animal Health
Partners

REFERRING VET

Dr. Lea Mehrkens

INVOICE

56226

DATE

1-18-23