



PATIENT

Milo Secondhand
Hounds

PRESENTING CLINICAL SIGNS

Imaging for cleft palate surgery planning.
Abnormal PE/Chem/CBC/UA Results: Elevated BUN 3.6mg/dL and Crea 1.5mg/dL

SPECIES

Canine

COMPUTED TOMOGRAPHIC STUDY OF HEAD

A high-resolution pre- and post-contrast CT study of the head are provided for review.

BREED

Boxer

COMPUTED TOMOGRAPHIC FINDINGS

Extensive interrupted regions of osseous bone defects are seen bilaterally extending through the incisive bone, parts of the palatal processes of the maxilla, and caudally to the palatine bone. In addition, communication of the soft palate is seen adjacent to the pterygoid bones and continuing nasal oral communications. The lesion is an exceptionally wide and long defect of 4cm length in the hard palate plus 4.0cm length in the soft palate and more than 2.0cm width at its widest portion. The interruption involves portions of the soft palate, adjacently and ventrally to the choana, and essentially covering the entire length of the palate. Only a rudimentary rim of hard and soft palate is remaining. Irregular shape and thickening of the presphenoid and pterygoid bones with narrowing of the caudal choana and rostral nasopharynx are seen. The soft palate extends dorsally to attach to the presphenoid and pterygoid hamuli which creates a bilateral mediadorsal opening to the mid nasopharynx.

SEX

M

AGE

17 Weeks, 5 Days

There is multifocal moderate turbinate lysis in the mid to ventral nasal passages.

INTERPRETED BY

Tilde Rodrigues Froes,
DMV, MSc., Dr. Med
Vet., Dipl. CBraRVet

No evidence of non-enhancing fluid attenuating accumulations are seen throughout the nasal passages, choana, and nasopharynx.

The cribriform plate is intact.

HOSPITAL NAME

Casselton Vet Service

The medial retropharyngeal lymph nodes are mildly enlarged and asymmetrical. LRFL measures approximately 0.5cm x 1.5cm; RRFL measures 0.7cm x 1.7cm.

The mandibular lymph nodes are mildly enlarged. The left deep cervical lymph node is enlarged as well.

REFERRING VET

Dr. Kyla Boas

The tympanic cavities and osseous bulla are normal.

The retrobulbar spaces are normal.

INVOICE

56225

The temporomandibular joints are bilaterally congruent.

A juvenile supernumerary incisive tooth is present.

DATE

1-18-23



PATIENT **COMPUTED TOMOGRAPHIC DIAGNOSIS**

Milo Secondhand Hounds

- Extensive cleft palate extending along bony portion (hard palate), and flexible portion (soft palate) seen bilaterally.
- Dorsal communication of the nasopharynx with the nasal passages.
- Mild to moderate destructive rhinitis, likely secondary to palate defect, other differential concurrent infectious rhinitis.
- No evidence of incomplete cribriform plate.
- Retropharyngeal, mandibular, and left deep cervical lymphadenopathy, likely reactive.
- Supernumerary incisive tooth, incidental in this age.

SPECIES

Canine

BREED

Boxer

INTERPRETATION OF THE FINDINGS & FURTHER RECOMMENDATIONS

The extensive cleft palate correlates with the patient history affecting the hard and soft palate bilaterally.

SEX

M

No evidence of fluid accumulation is noted in the nasal cavity, however there is evidence of destructive rhinitis.

Other abnormalities such as hypoplastic tympanic bullae, absent vomer, and incomplete cribriform plate is not present.

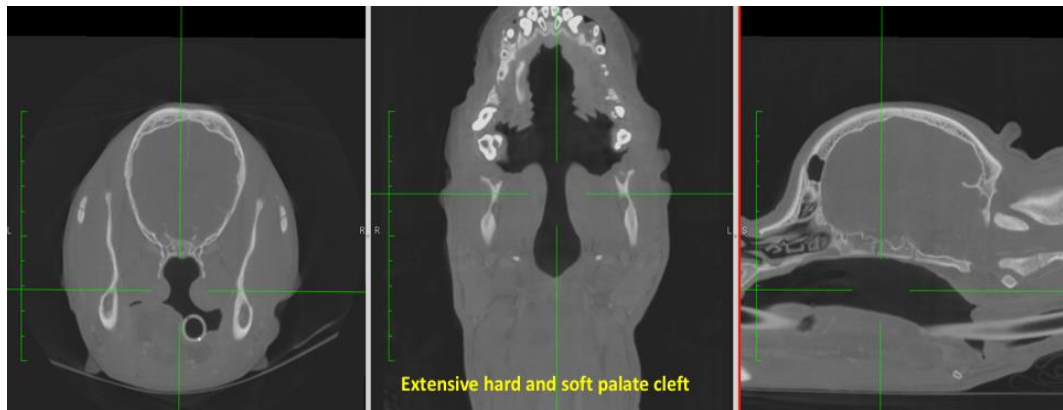
AGE

17 Weeks, 5 Days

Consider a thoracic x-ray previous to surgery to look for signs of pneumonia.

INTERPRETED BY

Tilde Rodrigues Froes, DMV, MSc., Dr. Med Vet., Dipl. CBraRVet



HOSPITAL NAME

Casselton Vet Service

REFERRING VET

Dr. Kyla Boas

INVOICE

56225

DATE

1-18-23



PATIENT

Milo Secondhand
Hounds

SPECIES

Canine

BREED

Boxer

SEX

M

AGE

17 Weeks, 5 Days

INTERPRETED BY

Tilde Rodrigues Froes,
DMV, MSc., Dr. Med
Vet., Dipl. CBraRVet

HOSPITAL NAME

Casselton Vet Service

REFERRING VET

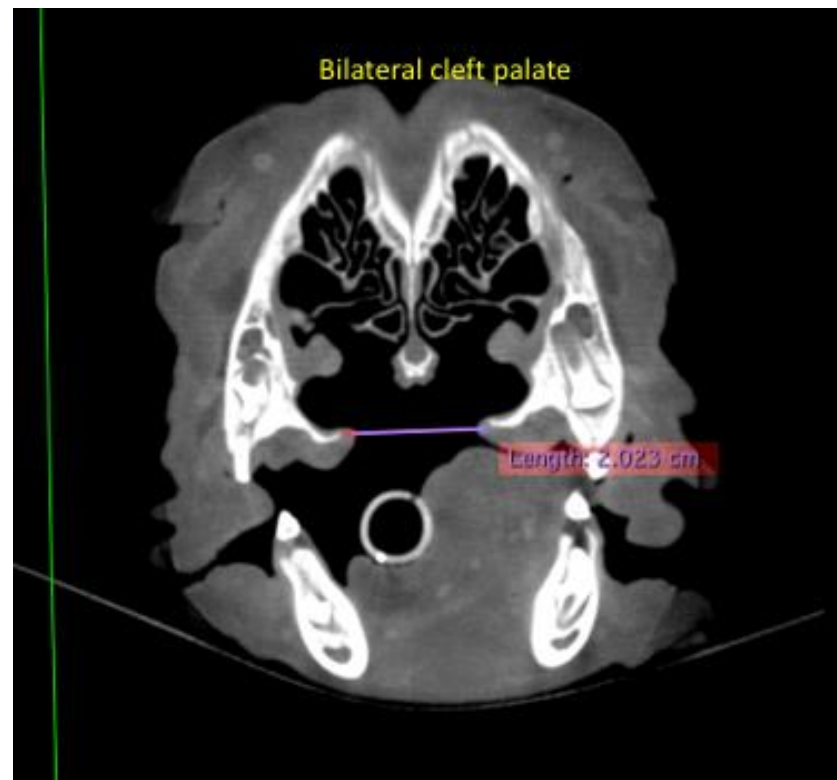
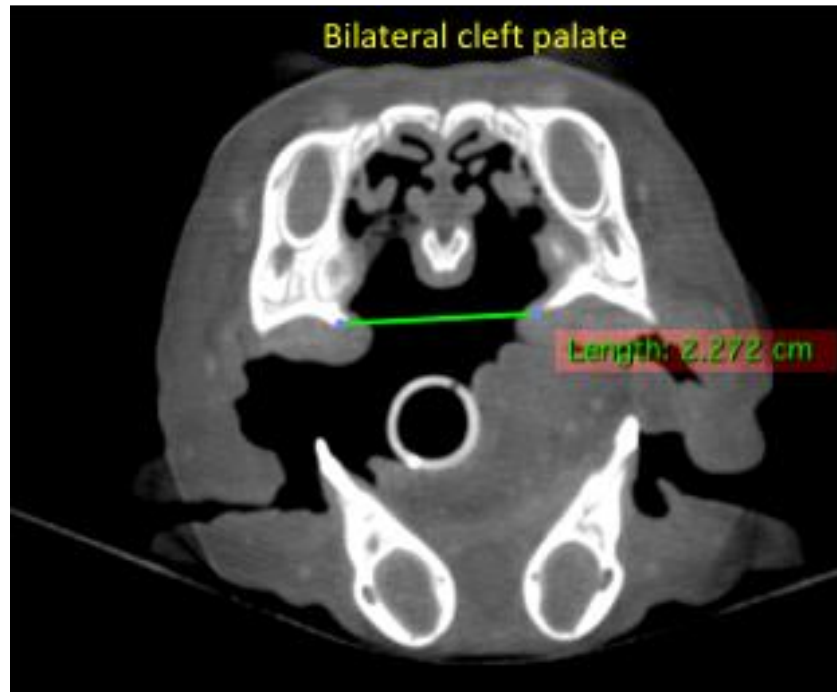
Dr. Kyla Boas

INVOICE

56225

DATE

1-18-23





PATIENT

Milo Secondhand
Hounds

SPECIES

Canine

BREED

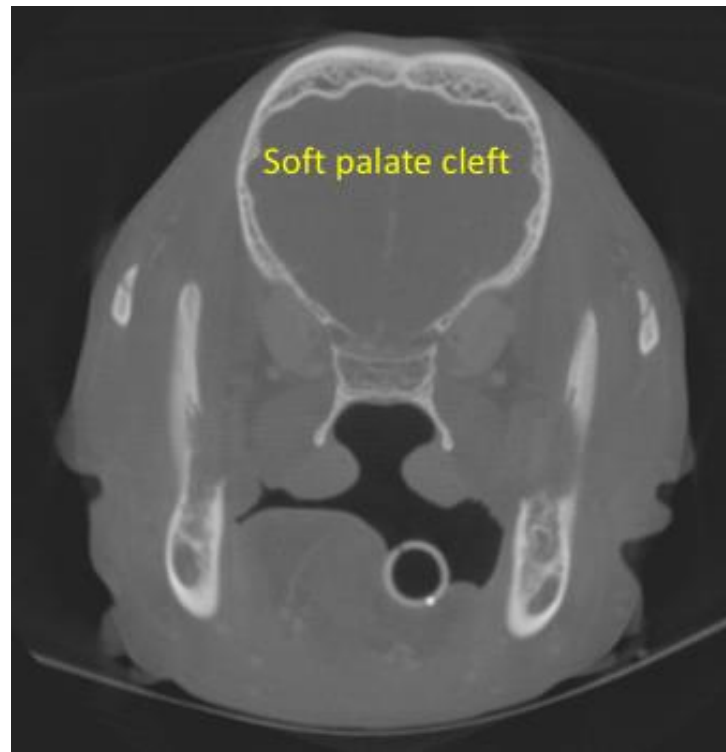Boxer

SEX

M

AGE

17 Weeks, 5 Days



INTERPRETED BY

Tilde Rodrigues Froes,
DMV, MSc., Dr. Med
Vet., Dipl. CBraRVet

HOSPITAL NAME

Casselton Vet Service

REFERRING VET

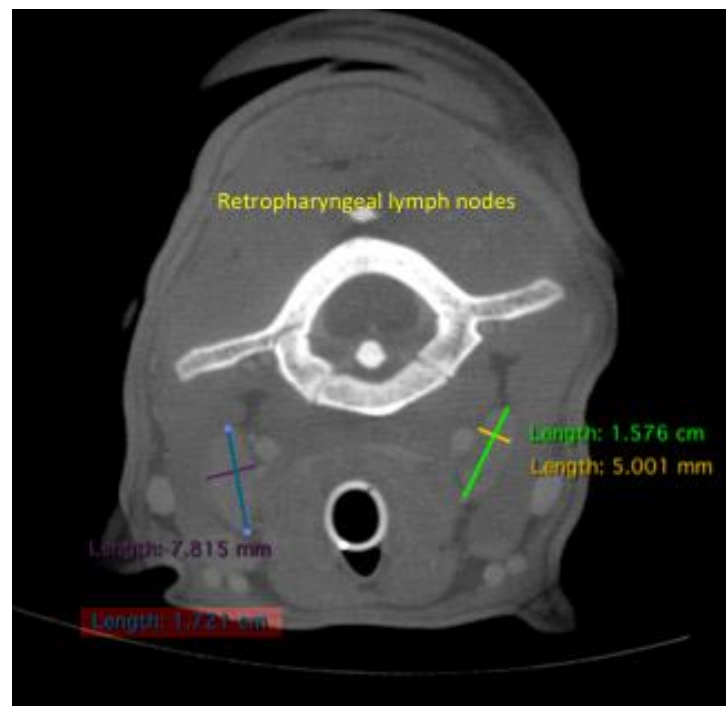
Dr. Kyla Boas

INVOICE

56225

DATE

1-18-23





PATIENT

Milo Secondhand
Hounds

The information and recommendations provided are based on the images presented by the referring veterinarian. No evaluation can be communicated regarding pathology that was not visible in the image/video clips provided.

Thank you for this referral. If the clinical or image interpretation does not parallel your findings or if I can be of any further assistance please contact me.

SPECIES

Canine

Tilde Rodrigues Froes, DMV, MSc., Dr. Med.Vet., Dipl.CBraRVet
info@sonopath.com

BREED

Boxer

SEX

M

AGE

17 Weeks, 5 Days

INTERPRETED BY

Tilde Rodrigues Froes,
DMV, MSc., Dr. Med
Vet., Dipl. CBraRVet

HOSPITAL NAME

Casselton Vet Service

REFERRING VET

Dr. Kyla Boas

INVOICE

56225

DATE

1-18-23