



**PATIENT PRESENTING CLINICAL SIGNS**

Little Man Gould

History: would like another opinion about ear problems ongoing problem for two years shakes head and debris come out of ears scratches ears to the point of causing cuts has eye discharge since this all started started having issues eating for about a week--not eating as much (is on wet food) normal water intake no v/d no c/s not currently on any meds right now  
**Physical Exam:**  
**General Appearance:** BAR, active, BCS 5/9  
**CRT/MM:** difficult to examine the mouth, appears WNL  
**Eyes:** Corneas clear, pupils normal size, symmetrical, sclera white, mild medial canthus ocular discharge  
**Ears:** Severe bilateral dark debris, intense pruritus. Swab from each showed dark debris 3+ yeast, 2+ cocci, neutrophils. Canals appear swollen. Very sensitive to any handling of the head  
**Oral Cavity:** Difficult to examine  
**Nasal Cavity:** No nasal drainage, nares WNL  
**Cardiovascular:** Regular rhythm; no murmur detected  
**Respiratory:** Lungs auscultate clear bilaterally; trachea clear  
**Abdomen:** Abdomen palpates normally; no pain, tenderness or masses on palpation  
**Rectal:** Did not perform rectal exam  
**Musculoskeletal:** Normal ambulation/no lameness reported  
**Integument:** Normal amount of shedding; skin/coat WNL  
**Lymph Nodes:** Lymph nodes normal in size; SM LN symmetric and not overtly enlarged  
**Urogenital:** External genitalia appears normal  
**Neurologic:** No apparent abnormalities noted  
**Assessment:** Dr Jessie Evoniuk Severe uncontrolled otitis RO otitis media, other Geriatric pet Previous cardiac arrest under GA for dental  
**Plan:** Dr Jessie Evoniuk Recommend CT scan for further exam +- ear flush +- culture repeat. Historically has grown Pseudomonas. Discussed safety and risk vs benefit given previous arrest. Pending full bloodwork up. Cytology of the ears performed Will discuss with previous vet to assess happening. Discussed sedation vs full anesthetic event. Discussed has been chronic and long-term, may respond temporarily. No previous allergy issues or issues with ears before the last 2 years. Discussed no travel, has been in ND for the last several years.

**SPECIES**

Feline

**BREED**

Domestic Medium Hair

**SEX**

MN

**AGE**

14 Years

**COMPUTED TOMOGRAPHIC STUDY OF THE SKULL**

A head CT without contrast is provided for review.

**COMPUTED TOMOGRAPHIC FINDINGS**

There is mild multifocal accumulation of fluid to soft tissue attenuating material in the horizontal ear canal bilaterally. There is focal accumulation of soft tissue fluid adjacent to the entrance of the medium ear canal and adjacent to the tympanic membrane region. The whole horizontal wall of the ear canal is thickened and irregular with moderate concurrent stenosis, bilaterally. There is no accumulation of fluid in the middle ear and no evidence of tympanic bullae wall thickening or lysis.

There is mild fluid soft tissue attenuating material in the nasal cavity and ventrally within the left frontal sinus.

The pharynx and larynx are normal.

No evidence of enlarged retropharyngeal lymph node.

The right 3<sup>rd</sup> premolar (108), and 1<sup>st</sup> premolar (106 and 206) are absent.

Moderate horizontal and vertical bone loss is seen throughout the mandibular and maxillary arcades.

**INTERPRETED BY**

Tilde Rodrigues Froes, DMV, MSc., Dr. Med Vet., Dipl. CBraRVet

**HOSPITAL NAME**

State Avenue Vet Clinic

**REFERRING VET**

Dr. Jessica Evoniuk

**INVOICE**

56199

**DATE**

1-17-23



**PATIENT**

The C2-C3 and C3-C4 intervertebral disc spaces are narrowed with incomplete and complete bridging spondylosis deformans.

Little Man Gould

**COMPUTED TOMOGRAPHIC DIAGNOSIS**

**SPECIES**

Feline

- Bilateral otitis externa with evidence of chronicity.
- Subjective thickening in the region of the tympanic membrane.
- No evidence of otitis media.
- Diffuse periodontal disease and multiple absent teeth.
- Mild predominantly left sided nasal fluid accumulation, differential diagnosis: nondestructive rhinitis, and sinusitis.
- C2-C3 and C3-C4 chronic disc disease and spondylosis deformans.

**BREED**

Domestic Medium Hair

**INTERPRETATION OF THE FINDINGS & FURTHER RECOMMENDATIONS**

**SEX**

The tomographic findings of the external ear apparatus correlate to the patient's history. For better analysis of the integrity of the tympanic membrane, otoscopy is suggested.

MN

For the suspicion of rhinitis, rhinoscopy is suggested for further evaluation.

**AGE**

14 Years

Correlate the oral/dental findings with a dental exam.

**INTERPRETED BY**

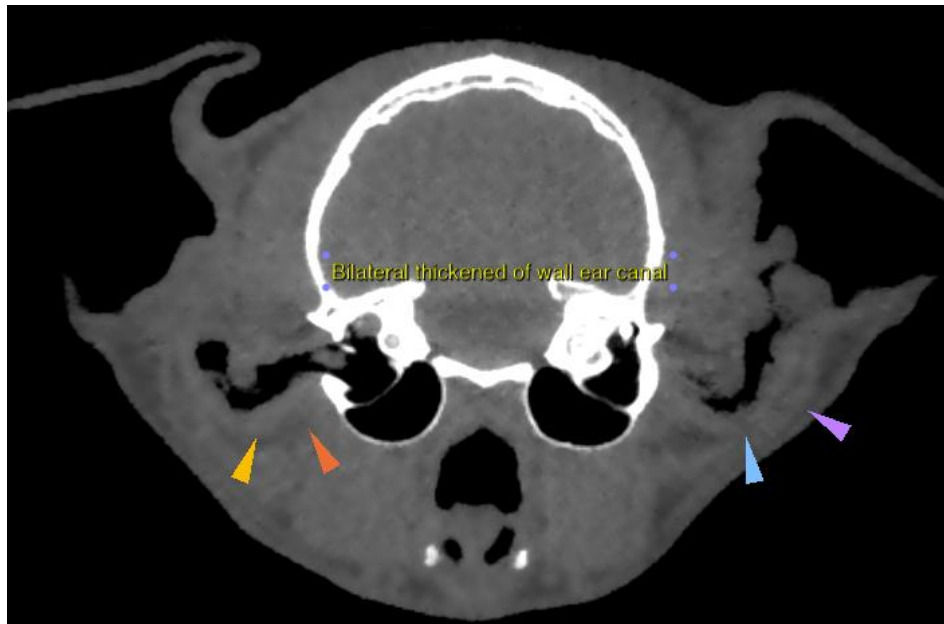
Tilde Rodrigues Froes, DMV, MSc., Dr. Med Vet., Dipl. CBraRVet

**HOSPITAL NAME**

State Avenue Vet Clinic

**REFERRING VET**

Dr. Jessica Evoniuk



**INVOICE**

56199

**DATE**

1-17-23



**PATIENT**

Little Man Gould

**SPECIES**

Feline

**BREED**

Domestic Medium  
Hair

**SEX**

MN

**AGE**

14 Years

**INTERPRETED BY**

Tilde Rodrigues Froes,  
DMV, MSc., Dr. Med  
Vet., Dipl. CBraRVet

**HOSPITAL NAME**

State Avenue Vet  
Clinic

**REFERRING VET**

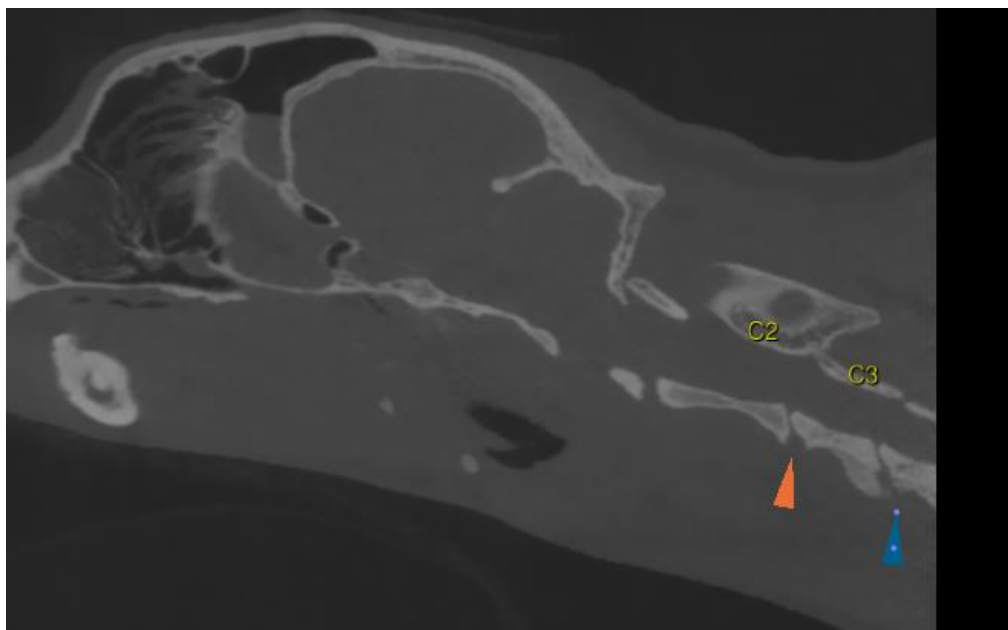
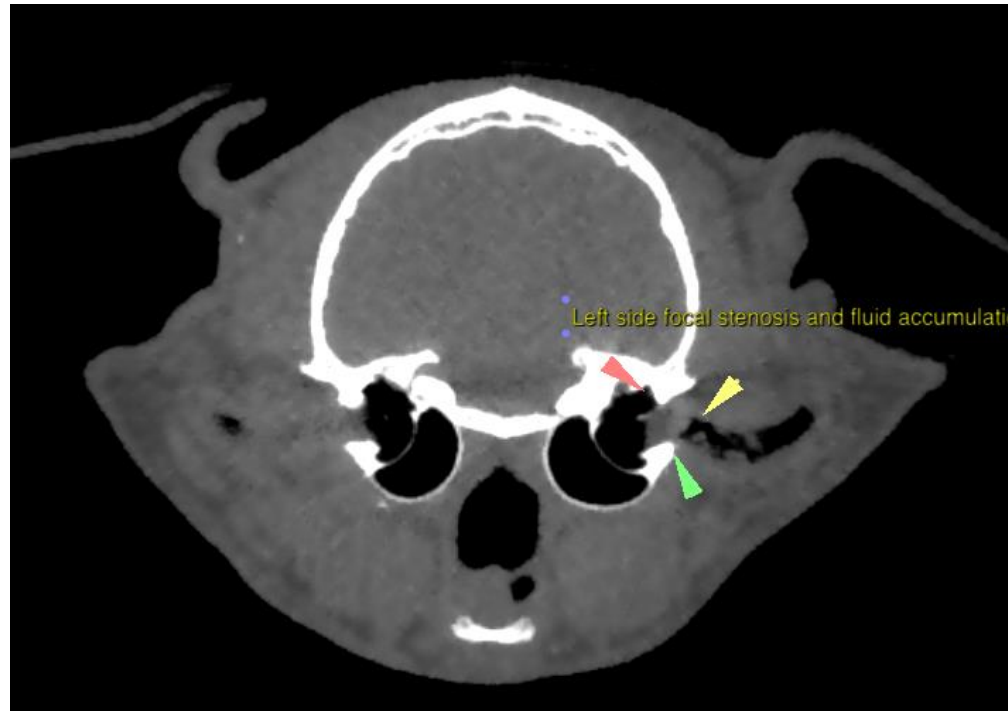
Dr. Jessica Evoniuk

**INVOICE**

56199

**DATE**

1-17-23





**PATIENT**

Little Man Gould

The information and recommendations provided are based on the images presented by the referring veterinarian. No evaluation can be communicated regarding pathology that was not visible in the image/video clips provided.

**SPECIES**

Feline

Thank you for this referral. If the clinical or image interpretation does not parallel your findings or if I can be of any further assistance please contact me.

**Tilde Rodrigues Froes, DMV, MSc., Dr. Med.Vet., Dipl.CBraRVet**  
info@sonopath.com

**BREED**

Domestic Medium  
Hair

**SEX**

MN

**AGE**

14 Years

**INTERPRETED BY**

Tilde Rodrigues Froes,  
DMV, MSc., Dr. Med  
Vet., Dipl. CBraRVet

**HOSPITAL NAME**

State Avenue Vet  
Clinic

**REFERRING VET**

Dr. Jessica Evoniuk

**INVOICE**

56199

**DATE**

1-17-23