



**PATIENT**

Ginger Velasco

**PRESENTING CLINICAL SIGNS**

Outdoor cat, difficulty walking, hind end, right side. Knuckling.

**SPECIES**

Feline

**RADIOGRAPHIC STUDY OF THE PELVIS**

Radiographs of the spine and pelvis are provided for review totaling 2 orthogonal views.

**RADIOGRAPHIC FINDINGS**

Generalized decrease in bone opacity and thin cortices, especially on the long bones and pelvic bones.

**BREED**

DSH

The contrast between the bone opacity and soft tissue opacity is decreased.

**SEX**

Male

The L4 vertebral body is shorter in length in comparison with the adjacent vertebral bodies. In addition, an ill-defined fracture line is seen. No clear evidence of luxation or subluxation is seen.

The stomach contains a moderate to severe amount of gas admixed with homogeneous soft tissue opaque ingesta material.

**AGE**

4 Months

The small intestines are normally distributed, of normal diameter, and contain a moderate amount of gas throughout.

All portions of the colon are moderately distended with gas admixed with heterogeneous soft tissue opaque fecal material.

**INTERPRETED BY**

No other abnormalities are identified.

**RADIOGRAPHIC DIAGNOSIS**

- Suspect metabolic bone disease such as nutritional secondary hyperparathyroidism, less likely osteogenesis imperfecta or vitamin D deficiency.
- Pathological vertebral L4 fracture, apparently stable.
- Post-prandial stomach with gastric digestive food. Differential diagnosis: less likely intermittent or partial pyloric outflow obstruction.

**INTERPRETATION OF THE FINDINGS & FURTHER RECOMMENDATIONS**

The adjustment of good quality cat food is recommended. Pain management could be considered. Cage restriction could also be considered as conservative therapy for the pathological vertebral fracture. Correlate to physical exam and neurolocalization.

In the absence of clinical signs of vomiting, the stomach distention is most likely post-prandial.

**HOSPITAL NAME**

Four Corners  
Veterinary Practice

**REFERRING VET**

Melina Maritato

**INVOICE**

56198

**DATE**

1-17-23

Tilde Rodrigues Froes,  
DMV, MSc., Dr. Med  
Vet., Dipl. CBraRVet



**PATIENT**

Ginger Velasco

**SPECIES**

Feline

**BREED**

DSH

**SEX**

Male

**AGE**

4 Months

**INTERPRETED BY**

Tilde Rodrigues Froes,  
DMV, MSc., Dr. Med  
Vet., Dipl. CBraRVet

**HOSPITAL NAME**

Four Corners  
Veterinary Practice

**REFERRING VET**

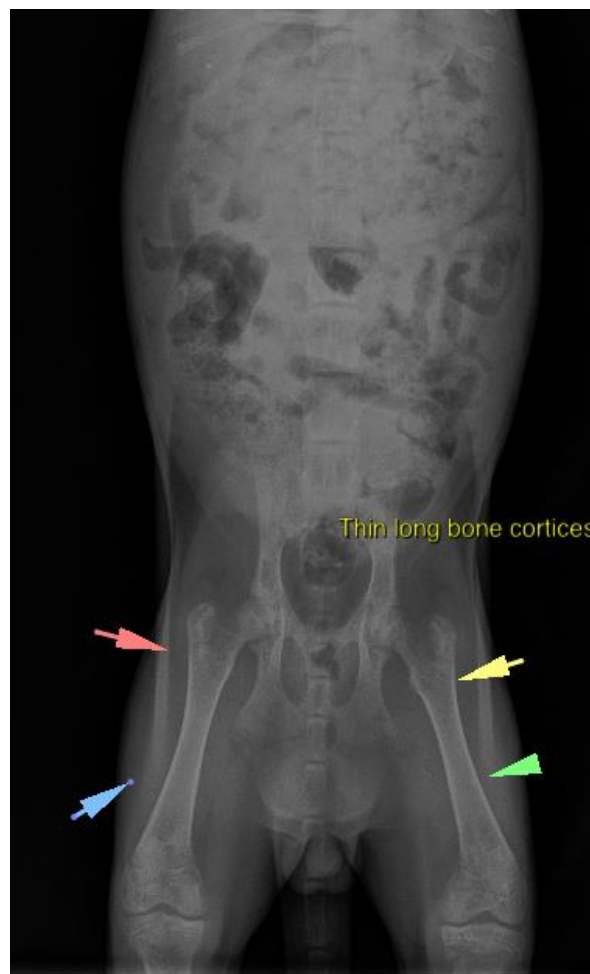
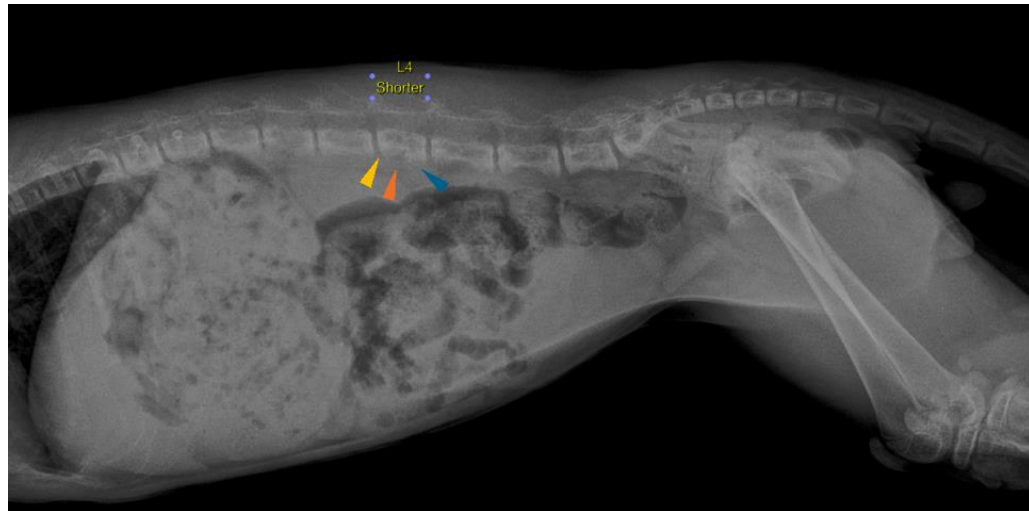
Melina Maritato

**INVOICE**

56198

**DATE**

1-17-23





**PATIENT**

Ginger Velasco

**SPECIES**

Feline

The information and recommendations provided are based on the images presented by the referring veterinarian. No evaluation can be communicated regarding pathology that was not visible in the image/video clips provided.

Thank you for this referral. If the clinical or image interpretation does not parallel your findings or if I can be of any further assistance please contact me.

**BREED**

DSH

**Tilde Rodrigues Froes**, DMV, MSc., Dr. Med.Vet., Dipl.CBraRVet  
info@sonopath.com

**SEX**

Male

**AGE**

4 Months

**INTERPRETED BY**

Tilde Rodrigues Froes,  
DMV, MSc., Dr. Med  
Vet., Dipl. CBraRVet

**HOSPITAL NAME**

Four Corners  
Veterinary Practice

**REFERRING VET**

Melina Maritato

**INVOICE**

56198

**DATE**

1-17-23