



PATIENT	PRESENTING CLINICAL SIGNS
DJ Richardella	Rechecking: DIARRHEA History: O STATES STOOL GOT BETTER ON MEDICATIONS BUT WAS STILL SOFT NOW LIQUID DIARRHEA WITH BLOOD. NO VOMITING. APPETITE NORMAL. ACTING NORMAL. NO ACCIDENTS IN HOUSE BUT WAKING O UP IN MIDDLE OF NIGHT TO GO OUTSIDE. O WOULD LIKE TO DO RADS TODAY. O STATES LIQUID DIARRHEA CAME BACK 1-2 DAYS AFTER STOPPING MEDICATION.
SPECIES	Abnormal PE/Chem/CBC/UA Results: Exam Notes: BAR; euhydrated; no pain on abdominal palpation Diagnostics & Testing: abd rads - consult pending fecal w/ giardia PCR - pending Treatment Plan: 0.4 mL vitamin B12 SQ 400 mL SQ fluids flagyl for 7 days panacure for 5 days continue proviable
Canine	
BREED	
Golden Retriever	RADIOGRAPHIC STUDY OF THE ABDOMEN AND COLLIMATED THORAX
	Orthogonal views of the abdomen and collimated thorax are available for review totaling 2 images.
SEX	RADIOGRAPHIC FINDINGS
Female	The stomach contains a moderate amount of heterogeneous soft tissue opaque food material admixed with gas, which redistributes normally with changes in the patient's position.
AGE	The small intestines are normally distributed, of normal diameter, contain a moderate amount of gas, and mildly heterogenous soft tissue material.
8 Months	No evidence of gastrointestinal foreign material.
INTERPRETED BY	All portions of the colon are empty and filled with intraluminal gas.
Tilde Rodrigues Froes, DMV, MSc., Dr. Med Vet., Dipl. CBraRVet	The liver, spleen, and renal silhouettes are normal.
	The urinary bladder is empty.
HOSPITAL NAME	The abdominal serosal detail is normal.
DPC Veterinary Hospital	The visible portion of the cardiac silhouette, pulmonary parenchyma, and pulmonary vessels are normal.
	The skeletal structures are unremarkable.
REFERRING VET	No other abnormalities are identified.
Dr. White	RADIOGRAPHIC DIAGNOSIS
INVOICE	<ul style="list-style-type: none"> • Normal abdominal radiographs. • Normal collimated thorax.
56167	INTERPRETATION OF THE FINDINGS & FURTHER RECOMMENDATIONS
DATE	No radiographic signs of abnormalities in the gastrointestinal tract are noted. Primary differentials of inflammatory gastroenteritis or colitis, dietary indiscretion, infectious parasitic (e.g., Giardia) could be correlated to clinical signs.
1-12-23	



PATIENT

DJ Richardella

SPECIES

Canine

BREED

Golden Retriever

SEX

Female

AGE

8 Months

INTERPRETED BY

Tilde Rodrigues Froes,
DMV, MSc., Dr. Med
Vet., Dipl. CBraRVet

HOSPITAL NAME

DPC Veterinary
Hospital

REFERRING VET

Dr. White

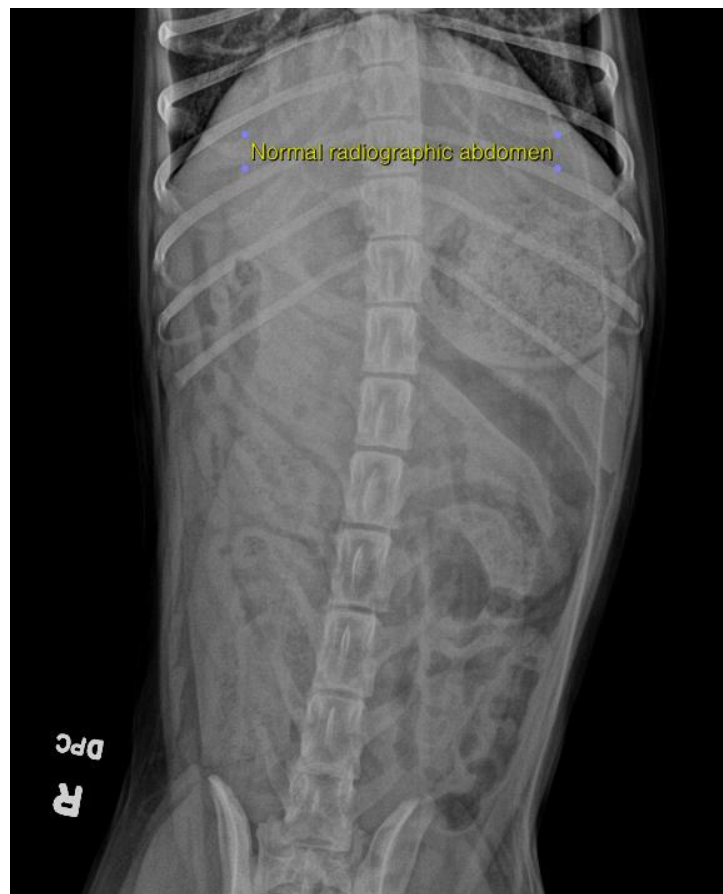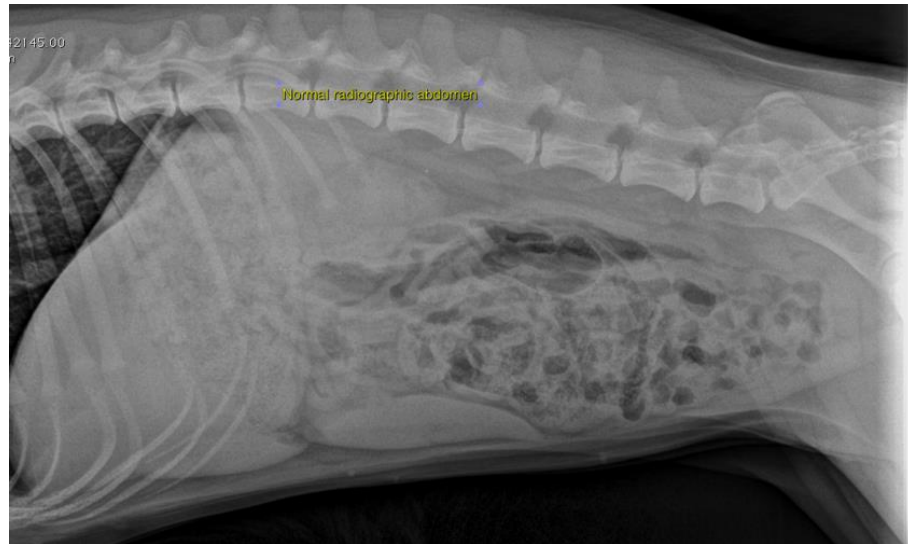
INVOICE

56167

DATE

1-12-23

An abdominal ultrasound may be useful to evaluate the gastrointestinal tract, including gastrointestinal wall layering, and thickness.





PATIENT

DJ Richardella

The information and recommendations provided are based on the images presented by the referring veterinarian. No evaluation can be communicated regarding pathology that was not visible in the image/video clips provided.

SPECIES

Canine

Thank you for this referral. If the clinical or image interpretation does not parallel your findings or if I can be of any further assistance please contact me.

BREED

Golden Retriever

Tilde Rodrigues Froes, DMV, MSc., Dr. Med.Vet., Dipl.CBraRVet
info@sonopath.com

SEX

Female

AGE

8 Months

INTERPRETED BY

Tilde Rodrigues Froes,
DMV, MSc., Dr. Med
Vet., Dipl. CBraRVet

HOSPITAL NAME

DPC Veterinary
Hospital

REFERRING VET

Dr. White

INVOICE

56167

DATE

1-12-23