



**PATIENT PRESENTING CLINICAL SIGNS**

Mia Estrin  
 Chronic Intermittent D+; Dignostic Bloodwork Pending. No other issues at this time. P is BAR, well hydrated and in good BCS on presentation  
 Abnormal PE/Chem/CBC/UA Results: Dignostic Bloodwork Pending

**SPECIES**

CAnine

**RADIOGRAPHIC STUDY OF THE ABDOMEN AND COLLIMATED THORAX**

Orthogonal views of the abdomen and collimated thorax are available for review totaling 3 images.

**BREED**

Goldendoodle

**RADIOGRAPHIC FINDINGS**

The stomach contains a small amount of homogeneous soft tissue opaque fluid material admixed with gas.

**SEX**

Spayed Female

The small intestines are normally distributed, of normal diameter, and contain a moderate amount of gas and homogeneous soft tissue fluid material.

**AGE**

2.5

All portions of the colon present with normal contour and contain a moderate amount of gas and soft tissue opaque fecal material.

The liver, spleen, and renal silhouettes are normal.

The urinary bladder is empty.

**INTERPRETED BY**

Tilde Rodrigues Froes, DMV, MSc., Dr. Med Vet., Dipl. CBraRVet

The abdominal serosal detail is normal.

The visible portion of the cardiac silhouette, pulmonary parenchyma, and pulmonary vessels are normal.

The skeletal structures are unremarkable.

**HOSPITAL NAME**

Summit Dog & Cat Hospital

No other abnormalities are identified.

**RADIOGRAPHIC DIAGNOSIS**

- Normal abdominal radiographs.
- Normal collimated thorax.

**REFERRING VET**

Vogler

**INTERPRETATION OF THE FINDINGS & FURTHER RECOMMENDATIONS**

No radiographic signs of abnormalities in the gastrointestinal tract are seen. Primary differentials of inflammatory gastroenteritis, dietary indiscretion, infectious parasitic (e.g., Giardia) could be correlated to clinical signs.

**INVOICE**

56102

An abdominal ultrasound may be useful to evaluate the gastrointestinal tract, including gastrointestinal wall layering and thickness. Consider direct wet-prep examination, fecal ELISA testing, and zinc sulfate centrifugation (for *Giardia*) to look for GI parasites.

**DATE**

1-10-23



**PATIENT**

Mla Estrin

**SPECIES**

CAnine

**BREED**

Goldendoodle

**SEX**

Spayed Female

**AGE**

2.5

**INTERPRETED BY**

Tilde Rodrigues Froes,  
DMV, MSc., Dr. Med  
Vet., Dipl. CBraRVet

**HOSPITAL NAME**

Summit Dog & Cat  
Hospital

**REFERRING VET**

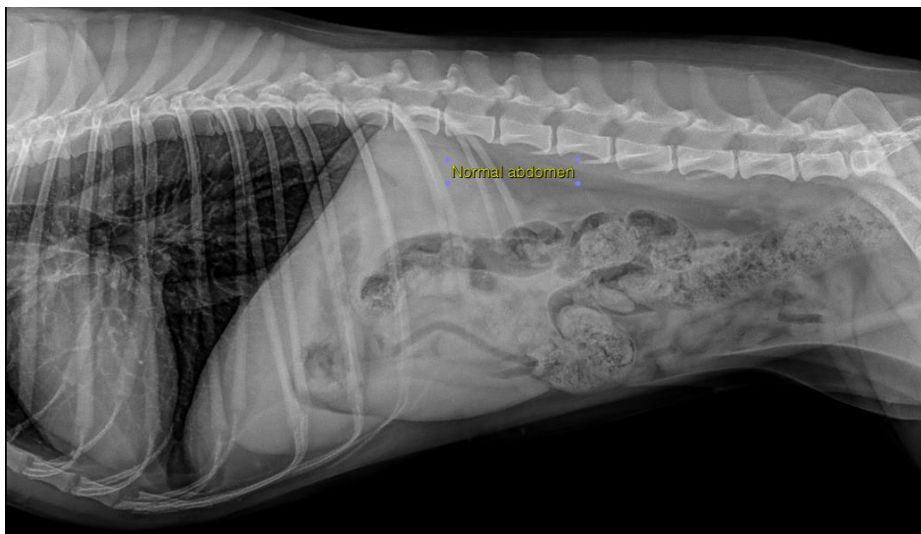
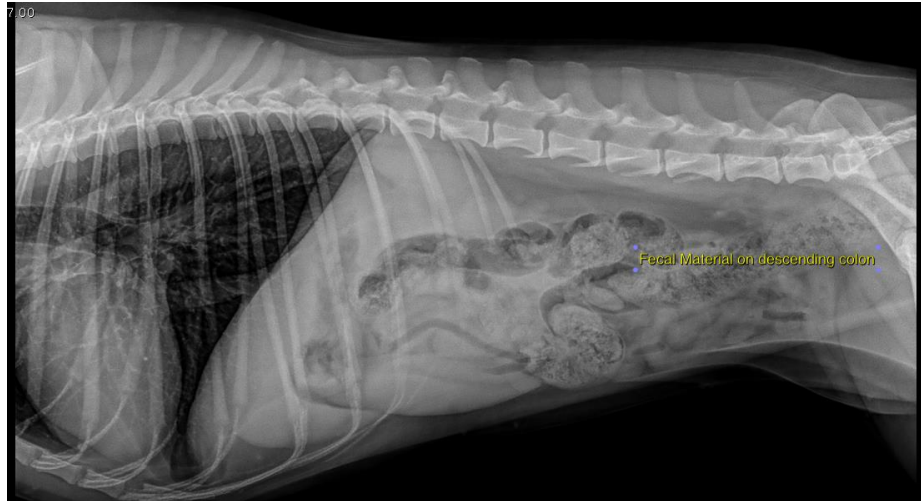
Vogler

**INVOICE**

56102

**DATE**

1-10-23



The information and recommendations provided are based on the images presented by the referring veterinarian. No evaluation can be communicated regarding pathology that was not visible in the image/video clips provided.

Thank you for this referral. If the clinical or image interpretation does not parallel your findings or if I can be of any further assistance please contact me.

**Tilde Rodrigues Froes, DMV, MSc., Dr. Med.Vet., Dipl.CBraRVet**  
info@sonopath.com