



PATIENT PRESENTING CLINICAL SIGNS

Lukas Dodaro Patient present 10 days after spontaneous pneumothorax (r/o blunt trauma v bulla rupture v neoplasia v other) Treated at LAASER for 24 hour monitoring after throacocentesis

SPECIES RADIOGRAPHIC STUDY OF THE THORAX

K9 Radiographs of the thorax in three imaging planes are provided for review.

RADIOGRAPHIC FINDINGS

BREED The cardiac silhouette, pulmonary vasculature, and parenchyma are normal.

German Shepherd Mix The pleural space and mediastinum are normal.

No evidence of soft tissue opaque pulmonary nodules or abnormal intrathoracic lymph nodes.

SEX The thoracic wall and ribs are normal.

Male Neutered The collimated cranial abdomen is normal.

The musculoskeletal structures are unremarkable.

AGE RADIOGRAPHIC DIAGNOSIS

7 Years

- Normal thorax

INTERPRETED BY INTERPRETATION OF THE FINDINGS & FURTHER RECOMMENDATIONS

No signs of pneumothorax at this time.

Tilde Rodrigues Froes, DMV, MSc., Dr. Med Vet., Dipl. CBraRVet

No evidence of pulmonary bullae or a pulmonary cavity mass that could be correlated to the previous pneumothorax.

HOSPITAL NAME

DTLAvets

REFERRING VET

Dr. Flores

INVOICE

56103

DATE

1-10-23



PATIENT

Lukas Dodaro

SPECIES

K9

BREED

German Shepherd
Mix

SEX

Male Neutered

AGE

7 Years

INTERPRETED BY

Tilde Rodrigues Froes,
DMV, MSc., Dr. Med
Vet., Dipl. CBraRVet

HOSPITAL NAME

DTLAvets

REFERRING VET

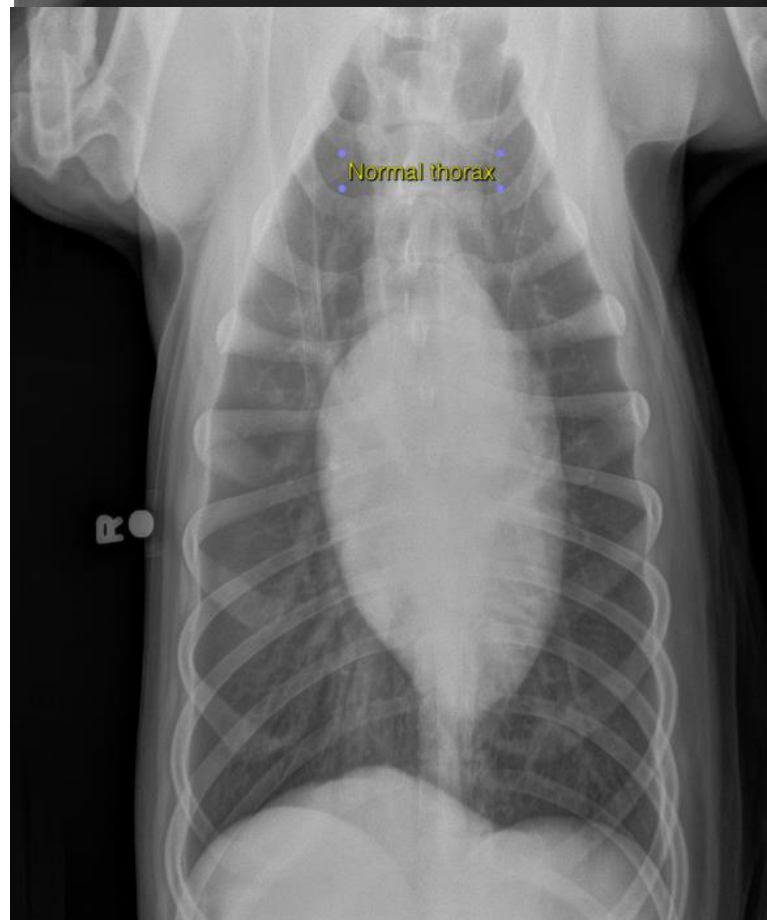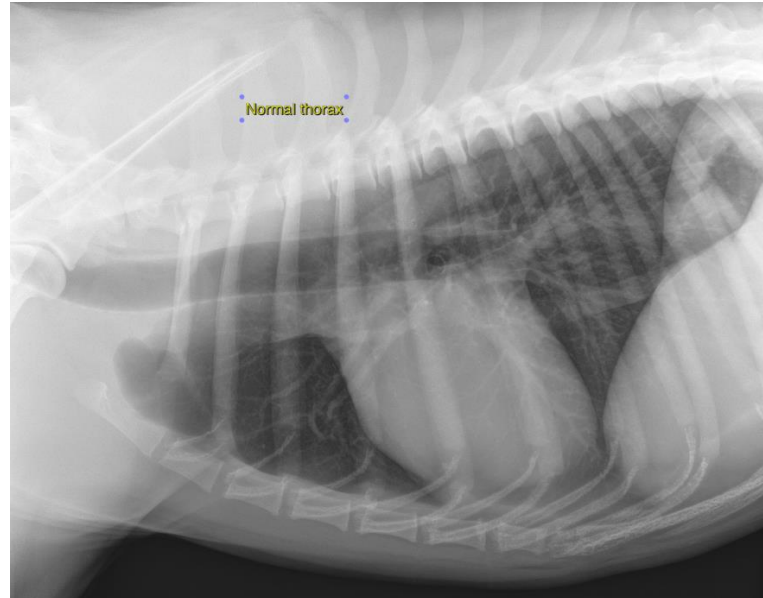
Dr. Flores

INVOICE

56103

DATE

1-10-23





PATIENT

Lukas Dodaro

SPECIES

K9

The information and recommendations provided are based on the images presented by the referring veterinarian. No evaluation can be communicated regarding pathology that was not visible in the image/video clips provided.

BREED

German Shepherd
Mix

Thank you for this referral. If the clinical or image interpretation does not parallel your findings or if I can be of any further assistance please contact me.

Tilde Rodrigues Froes, DMV, MSc., Dr. Med.Vet., Dipl.CBraRVet
info@sonopath.com

SEX

Male Neutered

AGE

7 Years

INTERPRETED BY

Tilde Rodrigues Froes,
DMV, MSc., Dr. Med
Vet., Dipl. CBraRVet

HOSPITAL NAME

DTLAvets

REFERRING VET

Dr. Flores

INVOICE

56103

DATE

1-10-23