



**PATIENT PRESENTING CLINICAL SIGNS**

Josie Stewart History: Has been coughing on and off for awhile now. Has been acting fine other wise. Abnormal PE/Chem/CBC/UA Results: PE: Lungs auscult WITH MILD HARSHNESS. looks great otherwise. No resent blood work.

**SPECIES RADIOGRAPHIC STUDY OF THE THORAX**

Feline Radiographs of the thorax in three imaging planes are provided for review.

**BREED RADIOGRAPHIC FINDINGS**

DSH The surrounding bony structures are within normal limits.  
The extrathoracic soft tissues present homogeneous without abnormalities.

**SEX**

Spayed Female The heart is of normal size and shape, there is no evidence of cardiac chamber or vascular enlargement. The pulmonary vasculature is within normal limits.

**AGE**

10 Years 2 Months The trachea is normal in diameter and presents the anticipated course. The luminal outline of the trachea is smooth.  
Generalized moderate peribronchial cuffing is present.

**INTERPRETED BY**

Sebastian Schaub,  
DVM Dr. med. vet.  
DipECVDI

The lung parenchyma presents the expected architecture and opacity; the intrapulmonary vascular branching is seen up to the third order lung vessels.  
The diaphragm is well delineated with even surface and the expected mild cranial bulging of the diaphragmatic cupola.

**HOSPITAL NAME RADIOGRAPHIC DIAGNOSIS**

Elizabeth AH

- Moderate bronchial lung pattern
- No evidence of airtrapping

**REFERRING VET INTERPRETATION OF THE FINDINGS & FURTHER RECOMMENDATIONS**

Len Anderson, DVM

The bronchial lung pattern is compatible with bronchitis and feline lower airway disease is a likely consideration ± superinfection. Primary infectious bronchitis – bacterial, viral, parasitic – is a consideration as well. Theoretically bronchogenic carcinoma might present with a primary bronchial pattern as well, but this is considered less likely here.

**INVOICE**

14072 Consider empirical management. If clinical signs are refractory to therapy, a BAL can be used as advanced diagnostic test.

**DATE**

10/29/21



**PATIENT**

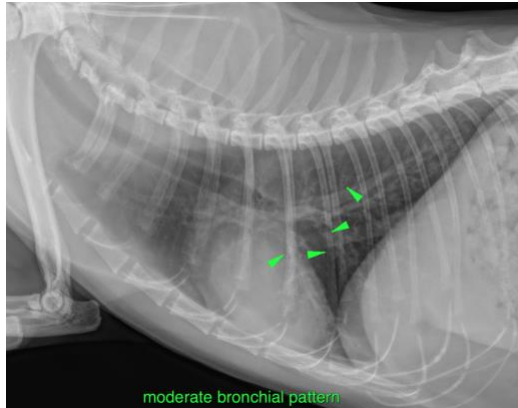
Josie Stewart

**SPECIES**

Feline

**BREED**

DSH



**SEX**

Spayed Female

**AGE**

10 Years 2 Months

**The information and recommendations provided are based on the images presented by the referring veterinarian. No evaluation can be communicated regarding pathology that was not visible in the image/video clips provided.**

Thank you for this referral. If the clinical or image interpretation does not parallel your findings or if I can be of any further assistance please contact me.

**Sebastian Schaub**, Sebastian Schaub, DVM, Dr. med. vet. DipECVDI  
sebast.schaub@gmail.com

**INTERPRETED BY**

Sebastian Schaub,  
DVM Dr. med. vet.  
DipECVDI

**HOSPITAL NAME**

Elizabeth AH

**REFERRING VET**

Len Anderson, DVM

**INVOICE**

14072

**DATE**

10/29/21