

**DATE PRESENTING CLINICAL SIGNS**

8/18/21 MCT-Ulcerated mass medial RHL

**INTERPRETED BY CYTOLOGY SUBMISSION**

U/S Guided FNA: liver and spleen

L.D. McGill, DVM,  
Ph.D, DACVP

**OBSERVATIONS**

Liver: Submitted are 5 excellent videos of moderate collections of cells from the liver in Sophie. Three of the videos demonstrate good collections of hepatocytes with very few inflammatory cells. Two of the videos demonstrate large numbers of inflammatory cells including neutrophils, lymphocytes and macrophages. Scattered hepatocytes are identified in these areas as well. Malignant characteristics are not identified. Mast cells are not identified.

Spleen: Submitted are 4 excellent videos of moderate collections of cells from the spleen in Sophie.

**SPECIES** All of the videos demonstrate the same type of cellularity with large numbers of neutrophils some of which appear to be quite mature. There are scattered nucleated RBCs and a few lymphocytes.

**Canine** Macrophages are identified as are aggregates of platelets. Malignant characteristics are not present nor do we identify mast cells.

**BREED**

Lab Retriever

**INTERPRETATION OF THE FINDINGS & FURTHER RECOMMENDATIONS**

Liver - Focal pyogranulomatous inflammation with hepatocellular granularity.

Spleen - Chronic suppurative inflammation with no evidence of neoplasia or mast cell disease.

**SEX**

FS

**COMMENTS**

The cellularity in both cases of the liver and spleen suggest some type of chronic inflammation. This could be draining from any location such as the intestine or pancreas. There is no suggestion of malignancy and in particular there is no suggestion of mast cell disease. There is a suggestion of chronic inflammation but I am unable to identify the source in Sophie.

**AGE**

9 years

**WEIGHT**

77.8 lbs

**HOSPITAL NAME**

Animal Care Centers of  
Flanders

**REFERRING VET**

Dr. Hallihan

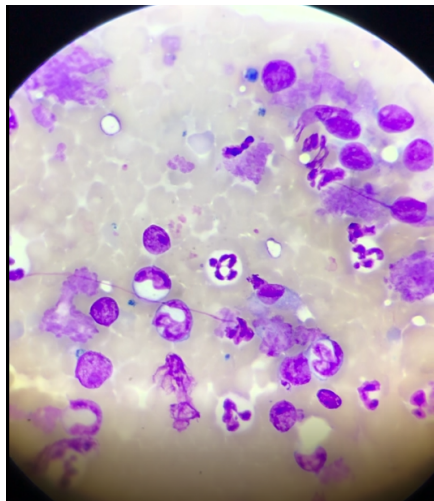
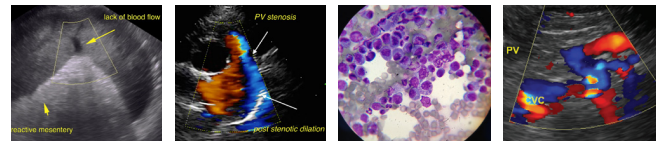


Image shows a field of inflammatory cells collected from the liver in Sophie.

**INVOICE NUMBER**

9077



**DATE**

8/18/21

**INTERPRETED BY**

L.D. McGill, DVM,  
Ph.D., DACVP

**PATIENT**

Sophie Marchigiano

**SPECIES**

Canine

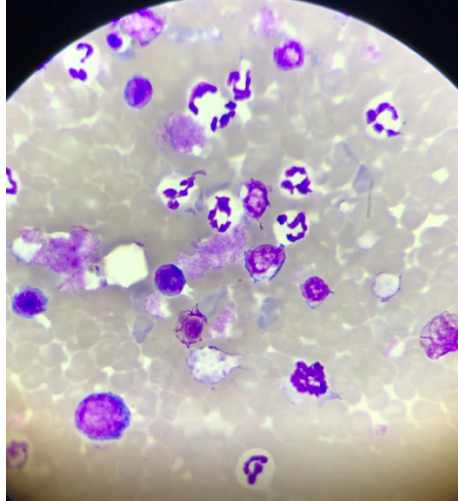


Image shows a few inflammatory cells collected from the spleen in Sophie.

**BREED**

Lab Retriever

**SEX**

FS

**AGE**

9 years

**WEIGHT**

77.8 lbs

**The information and recommendations provided are based on the images presented by the referring veterinarian. No evaluation can be communicated regarding pathology that was not visible in the image/video clips provided.**

Thank you for this referral. If the clinical or image interpretation does not parallel your findings or if I can be of any further assistance please contact me.

**L.D. McGill, DVM, Ph.D., DACVP**

8288 Top of the World Drive  
Cottonwood Heights, UT 84121  
ldmcgill.vetpath@gmail.com  
cell: 801-865-1220

**HOSPITAL NAME**

Animal Care Centers of  
Flanders

**REFERRING VET**

Dr. Hallihan

**INVOICE NUMBER**

9077