



PATIENT PRESENTING CLINICAL SIGNS

Patient: Pooh Bear Kennedy
History: Patient presented for intermittent limping on left forelimb. Patient noted to have cornified growth present on left large paw pad. Owner has not noted any respiratory issues but pet appears to have enlarged heart on x-rays. Pet has 3 year history of prednisone administration for eosinophilic granulomatous complex

SPECIES

Feline RADIOGRAPHIC STUDY OF THE THORAX

Radiographs of the thorax in two imaging planes are provided for review.

BREED

Tabby

RADIOGRAPHIC FINDINGS

The body condition score is 8/9.

SEX

Multifocal mild spondylosis formation is seen along the thoracic spine.

Neutered Male

The extrathoracic soft tissues present homogeneous without abnormalities.

AGE

10.8 Pounds

The cardiac silhouette is rotated, presenting broad contact with the sternum; in the VD view, the cardiac silhouette is occupying approximately 75% of the thoracic width. The pulmonary vasculature is within normal limits.

The cranial mediastinum is moderately widened by fat.

INTERPRETED BY

**Sebastian Schaub,
 DVM Dr. med. vet.
 DipECVDI**

The trachea is normal in diameter and presents the anticipated course. The luminal outline of the trachea is smooth.

The bronchial tree presents with thin walls and tapers uniformly towards the periphery as expected. The lung parenchyma presents a generalized ground glass opacity; the intrapulmonary vascular branching is seen up to the third order lung vessels.

HOSPITAL NAME

Boca Park AH

The diaphragm is well delineated with even surface and the expected mild cranial bulging of the diaphragmatic cupola.

REFERRING VET

Dr. Corrina Gorgon

RADIOGRAPHIC DIAGNOSIS

- Obesity
- Cardiomegaly
- Generalized unstructured interstitial lung pattern
- Spondylosis deformans

INVOICE

17262

INTERPRETATION OF THE FINDINGS & FURTHER RECOMMENDATIONS

The cardiomegaly is very likely a subjective impression due to pericardial & mediastinal fat depositions. A cardiac echo might be used to rule out cardiomyopathy entirely.

DATE

9/9/22



PATIENT

Pooh Bear Kennedy

The unstructured interstitial lung pattern is considered artefactual due to the nutritional status of the patient.

SPECIES

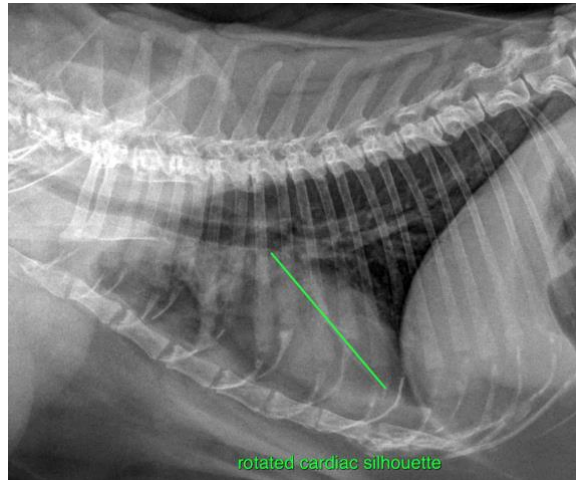
Feline

BREED

Tabby

SEX

Neutered Male



AGE

10.8 Pounds

The information and recommendations provided are based on the images presented by the referring veterinarian/sonographer. No evaluation can be communicated regarding pathology that was not visible in the image/video clips provided.

INTERPRETED BY

Sebastian Schaub,
DVM Dr. med. vet.
DipECVDI

Thank you for this referral. If the clinical or image interpretation does not parallel your findings or if I can be of any further assistance please contact me.

Sebastian Schaub, Sebastian Schaub, DVM, Dr. med. vet. DipECVDI
sebast.schaub@gmail.com

HOSPITAL NAME

Boca Park AH

REFERRING VET

Dr. Corrina Gorgon

INVOICE

17262

DATE

9/9/22