SonoPath Teleradiology

EDUCATIONAL TELECONSULTATION SERVICES™

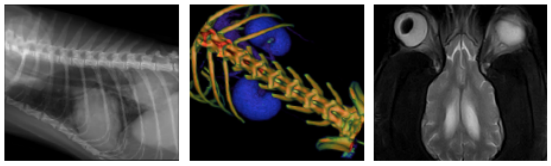

SonoPath.com
1-800-838-4268 info@sonopath.com

PATIENT

Pitbull Washam

SPECIES

Feline

BREED

DSH

SEX

Neutered Male

AGE

12 Years

INTERPRETED BY

Sebastian Schaub, DVM Dr. med. vet. DipECVDI

HOSPITAL NAME

Blairstown AH

REFERRING VET

Dr. Clegg

INVOICE

13004

DATE

9/9/21

PRESENTING CLINICAL SIGNS

History: Irregular pink oral lesion on left hard palate. Bloodwork within normal limits, on dexamethasone.
Abnormal PE/Chem/CBC/UA Results:

COMPUTED TOMOGRAPHIC STUDY OF THE SKULL

A high resolution pre- and post-contrast CT study of the is provided for review.

COMPUTED TOMOGRAPHIC FINDINGS

Multiple teeth are absent. Post contrast administration a plaque like mass is seen centered on the alveolar process of the left maxillary bone, extending from the level of triadan 208 distally up to the caudal margin of the alveolar process. Mediodistally the mass is extending up to the base of the soft palate. The plaque like mass is extending dorsally into the ventral aspect of the left orbit. The plaque like mass is measuring approximately 2.1 x 1.0 x 1.9 cm in size. The alveolar process of the left maxillary bone presents moth eaten osteolytic lesions.

The nasal cavity presents the expected aerated spaces between thin and even conchae and turbinates with smooth mucosal lining.

Both temporomandibular joints present congruent joint spaces with even subchondral bone surfaces and are considered within normal limits.

Both tympanic bullae are aerated, the mucosal lining is not seen, the bony wall is smooth and thin. The external ear canals are within normal limits.

The brain presents no deviation from normal anatomy and symmetry. The brain parenchyma is homogeneous and within normal limits for attenuation and distribution of contrast enhancement. The ventricular system is non-dilated and symmetric.

The submandibular and medial retropharyngeal lymph nodes are small and elongated with a normal short-to-long-axis-ratio is < 0.5, the attenuation and contrast enhancement pattern is uniform.

Post contrast administration, dorsal to C2-C3, a fusiform shaped heterogeneous contrast enhancing intramuscular lesion is visible, measuring 1.8 cm in length and 2 mm in diameter.

COMPUTED TOMOGRAPHIC DIAGNOSIS

- Plaque like soft tissue mass centered on the alveolar process of the left maxillary bone and extending up to the base of the soft palate
- Monostotic semiaggressive osteolytic lesions of the left maxillary bone
- Contrast enhancing intramuscular lesion epaxial musculature dorsal C2/C3
- Multiple absent teeth

INTERPRETATION OF THE FINDINGS & FURTHER RECOMMENDATIONS

The findings are consistent with a soft tissue neoplasia associated with the alveolar process of the left maxillary bone and extending up to the base of the soft palate and extension into the left orbit. Differentials include squamous cell carcinoma, melanoma, fibrosarcoma, other. If not done so yet, FNA

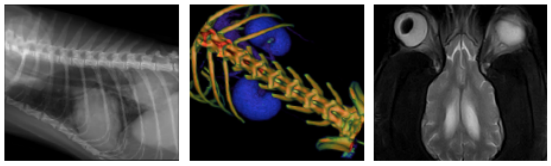

SonoPath.com
1-800-838-4268 info@sonopath.com

PATIENT

Pitbull Washam

SPECIES

Feline

BREED

DSH

SEX

Neutered Male

AGE

12 Years

INTERPRETED BY

Sebastian Schaub, DVM Dr. med. vet. DipECVDI

HOSPITAL NAME

Blairstown AH

REFERRING VET

Dr. Clegg

INVOICE

13004

DATE

9/9/21

sampling and/or biopsy is recommended for further definition. There are no curative surgical treatment options, but the chances of radiation therapy can be discussed with oncologist.
The contrast enhancing intramuscular lesion is concerning for muscular metastasis.

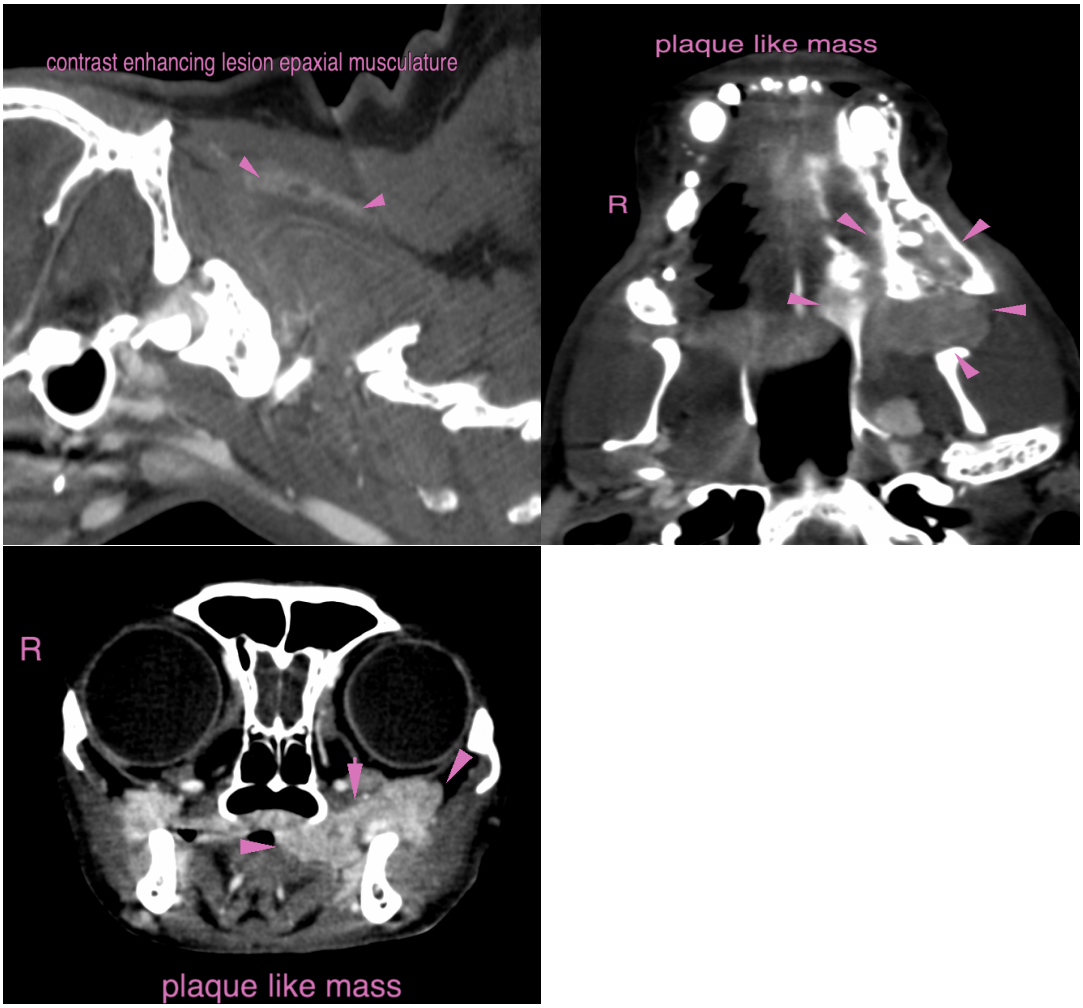

The information and recommendations provided are based on the images presented by the referring veterinarian. No evaluation can be communicated regarding pathology that was not visible in the image/video clips provided.

Thank you for this referral. If the clinical or image interpretation does not parallel your findings or if I can be of any further assistance please contact me.

Sebastian Schaub, Sebastian Schaub, DVM, Dr. med. vet. DipECVDI
sebast.schaub@gmail.com

SonoPath Teleradiology

EDUCATIONAL TELECONSULTATION SERVICES™

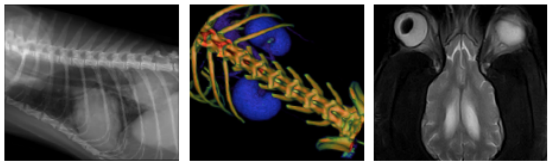

SonoPath.com™
1-800-838-4268 info@sonopath.com

PATIENT

Pitbull Washam

SPECIES

Feline

BREED

DSH

SEX

Neutered Male

AGE

12 Years

INTERPRETED BY

Sebastian Schaub, DVM Dr. med. vet. DipECVDI

HOSPITAL NAME

Blairstown AH

REFERRING VET

Dr. Clegg

INVOICE

13004

DATE

9/9/21