



**PATIENT PRESENTING CLINICAL SIGNS**

Kyle Cunningham History: P presented for evaluation of apparent weight loss (at least 2-week duration), mild lethargy, unkempt haircoat, sensitivity on walk, and diarrhea (though O's believe this is due to diet change). P is FeLV positive.

**SPECIES**

Feline

Abnormal PE/Chem/CBC/UA Results: BW submitted to lab Mild/subjective soft tissue swelling of left carpi P is sensitive on palpation of the carpi and feet bilaterally P is weight-bearing and ambulatory, though forelimb gait appears stiffened and both forelimbs appear affected. BCS is 4/9

**BREED**

Maine Coon Mix

**RADIOGRAPHIC STUDY OF THE ANTEBRACHIUM BILATERALLY**

Radiographs of the antebrachium in orthogonal imaging planes are provided for review.

**RADIOGRAPHIC FINDINGS**

**SEX**

Neutered Male

At the palmar and medial aspect left metacarpal bones a moderate uniform soft tissue swelling is visible.

The surrounding soft tissues of the right front paw are within normal limits.

**AGE**

2.5 Years

The osseous structures of both front limbs are within normal limits but generalized amputation of the distal phalanx of all digits.

**RADIOGRAPHIC DIAGNOSIS**

**INTERPRETED BY**

Sebastian Schaub,  
DVM Dr. med. vet.  
DipECVDI

- Soft tissue swelling left metacarpal region
- Current state post declawing procedure

**INTERPRETATION OF THE FINDINGS & FURTHER RECOMMENDATIONS**

There is a generalized moderate soft tissue swelling of the left front paw and inflammatory, traumatic or less likely neoplastic causes need to be considered. Rule out history of trauma. FNA sampling can be considered as an advanced diagnostic test.

**HOSPITAL NAME**

Boca Park AH

**REFERRING VET**

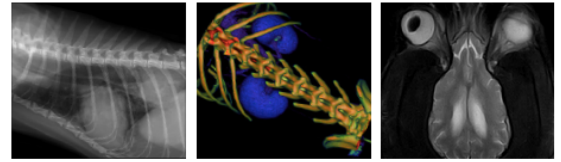
Tifanie Silver

**INVOICE**

13012

**DATE**

9/9/21



**PATIENT**

Kyle Cunningham

**SPECIES**

Feline

**BREED**

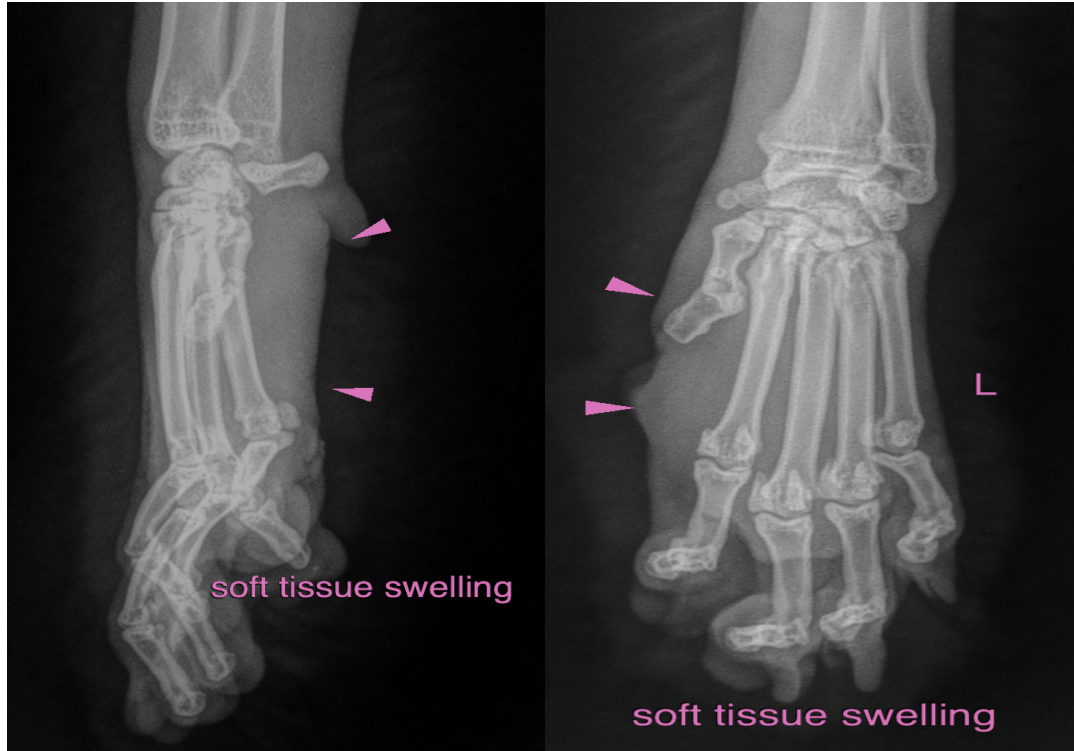
Maine Coon Mix

**SEX**

Neutered Male

**AGE**

2.5 Years



**INTERPRETED BY**

Sebastian Schaub,  
DVM Dr. med. vet.  
DipECVDI

The information and recommendations provided are based on the images presented by the referring veterinarian. No evaluation can be communicated regarding pathology that was not visible in the image/video clips provided.

Thank you for this referral. If the clinical or image interpretation does not parallel your findings or if I can be of any further assistance please contact me.

**HOSPITAL NAME**

Boca Park AH

**Sebastian Schaub**, Sebastian Schaub, DVM, Dr. med. vet. DipECVDI  
sebast.schaub@gmail.com

**REFERRING VET**

Tifanie Silver

**INVOICE**

13012

**DATE**

9/9/21