



PATIENT PRESENTING CLINICAL SIGNS

BUSTER TOLERICO -CC CHRONIC STOMATITIS CC SUBLINGUAL MASS WT LOSS,FEVER ELEVATED WBC MASS WAS BIOPSIED TODAY R/O NEOPLLASIA VS PNEUMONIA VS OTHER

SPECIES RADIOGRAPHIC STUDY OF THE THORAX

Feline A full set of radiographs of the thorax is provided for review. Radiographs are provided in JPEG file format.

BREED RADIOGRAPHIC FINDINGS

DSH The surrounding bony structures are within normal limits.

The extrathoracic soft tissues present homogeneous without abnormalities.

SEX

Neutered Male

The heart is of normal size and shape, there is no evidence of cardiac chamber or vascular enlargement. The pulmonary vasculature is within normal limits.

AGE

7 Years

The trachea is normal in diameter and presents the anticipated course. The luminal outline of the trachea is smooth.

The bronchial tree presents with thin walls and tapers uniformly towards the periphery as expected.

INTERPRETED BY

Sebastian Schaub, DVM
Dr. med. vet. DipECVDI

The lung parenchyma presents the expected architecture and opacity; the intrapulmonary vascular branching is seen up to the third order lung vessels. In the consecutive set of radiographs progressive compression atelectasis of the right lung lobes is visible.

HOSPITAL NAME

Tenafly Vet Center

An esophageal tube is seen ending approximately level with the tracheal bifurcation. There is progressive dilation of the esophagus throughout the consecutive radiographic studies – due to general anesthesia.

The diaphragm is well delineated with even surface and the expected mild cranial bulging of the diaphragmatic cupola.

REFERRING VET

Barnea

RADIOGRAPHIC DIAGNOSIS

- Current state post placement of an esophageal tube
- Mild megaesophagus due to general anesthesia
- Dystelectasis of the right lung lobes, due to general anesthesia

INVOICE

47346

INTERPRETATION OF THE FINDINGS & FURTHER RECOMMENDATIONS

The radiographic study of the thorax presents no pathology of the lungs but progressive compression atelectasis of the right lung lobes secondary to general anesthesia.

DATE

9-9-21



PATIENT

BUSTER TOLERICO

SPECIES

Feline

BREED

DSH

SEX

Neutered Male

AGE

7 Years

INTERPRETED BY

Sebastian Schaub, DVM
Dr. med. vet. DipECVDI

HOSPITAL NAME

Tenafly Vet Center

REFERRING VET

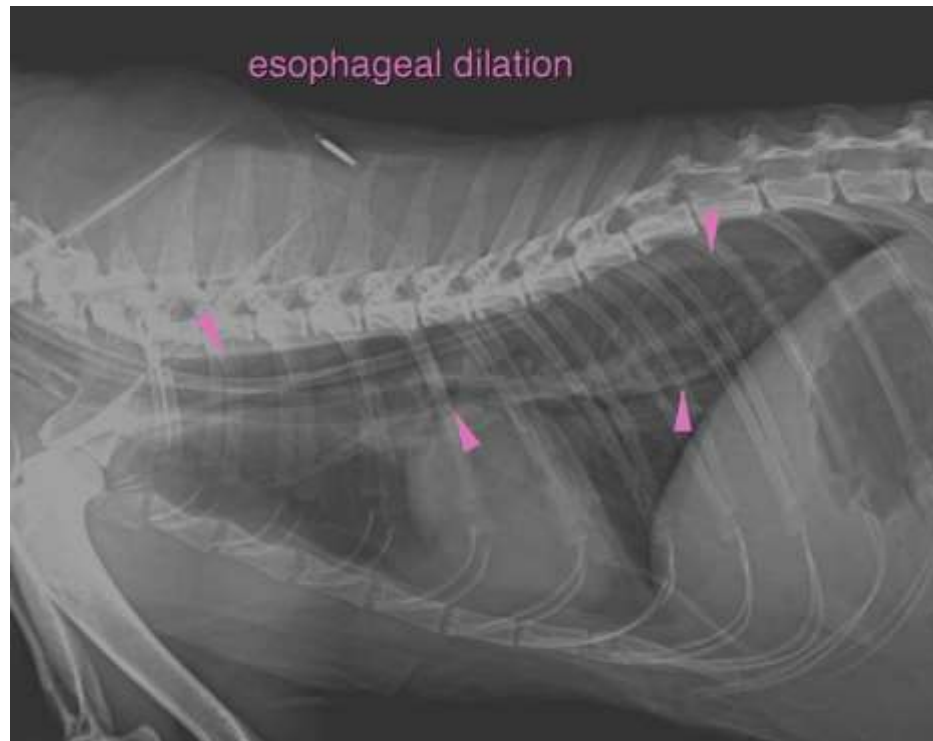
Barnea

INVOICE

47346

DATE

9-9-21



The information and recommendations provided are based on the images presented by the referring veterinarian. No evaluation can be communicated regarding pathology that was not visible in the image/video clips provided.

Thank you for this referral. If the clinical or image interpretation does not parallel your findings or if I can be of any further assistance please contact me.

Sebastian Schaub, Sebastian Schaub, DVM, Dr. med. vet. DipECVDI
sebast.schaub@gmail.com