



PRESENTING CLINICAL SIGNS

PATIENT

Bella Mauzy

History: On 9/1/21, Bella came in for chewing at her hind end, uncomfotability in general, blood in her litter box, and not eating. She was sent home on steroids, antibiotics, and pain meds. She improved some on this, but is still uncomfortable and not wanting to eat much. Owner reports that her stools look normal, but doesn't actually know a whole lot about all of Bella's bathroom habits.

SPECIES

Feline

Abnormal PE/Chem/CBC/UA Results: 9/1 exam: SEEMS PAINFUL TO PALPATION OF CAUDAL ABDOMEN; SPINE AND TAIL ARE VERY PAINFUL TO PALPATION, HYPERESTHTIC TO PALPATION 9/9 exam: Pt was sedated for exam - Abdomen Soft, nonpainful, no masses, no organomegaly. Rectal examination not performed. Slight crepitus over the mid-lumbar spine.

BREED

DMH

RADIOGRAPHIC STUDY OF THE ABDOMEN

A complete set of radiographs of the abdomen is provided for review.

SEX

Female

RADIOGRAPHIC FINDINGS

The surrounding bony structures are within normal limits.

No abnormalities of the extraabdominal soft tissues are noted. The abdominal wall is smooth and thin. The serosal detail is maintained throughout the peritoneal and retroperitoneal space.

AGE

1 Year 2 Months

The liver is appropriate in position, size and presents uniform opacity.

The splenic head is in the anticipated position and within normal limits for size and opacity.

Both kidneys are seen and present with normal size, shape, delineation and opacity. The urinary bladder is in its anticipated position. No radiopaque calculi are noted throughout the upper and lower urinary tract.

INTERPRETED BY

Sebastian Schaub,
DVM Dr. med. vet.
DipECVDI

The stomach is in its anticipated position and presents normal content.

The small intestinal loops are of even diameter and non-dilated, a small amount of gas is seen within the small intestinal loops and considered within normal limits.

HOSPITAL NAME

Elizabeth AH

The colon is seen in the expected position and presents with appropriate content.

RADIOGRAPHIC DIAGNOSIS

REFERRING VET

Dr. Sareena Enloe

- Normal abdomen

INTERPRETATION OF THE FINDINGS & FURTHER RECOMMENDATIONS

INVOICE

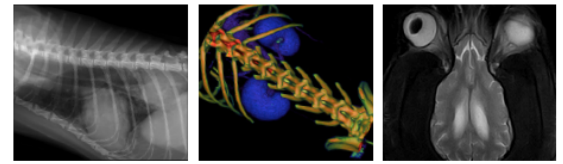
13013

The radiographic study presents no abnormal findings. If not done so yet, complementing workup by a complete urinalysis might be beneficial.

The information and recommendations provided are based on the images presented by the referring veterinarian. No evaluation can be communicated regarding pathology that was not visible in the image/video clips provided.

DATE

9/9/21



PATIENT

Thank you for this referral. If the clinical or image interpretation does not parallel your findings or if I can be of any further assistance please contact me.

Bella Mauzy

Sebastian Schaub, Sebastian Schaub, DVM, Dr. med. vet. DipECVDI
sebast.schaub@gmail.com

SPECIES

Feline

BREED

DMH

SEX

Female

AGE

1 Year 2 Months

INTERPRETED BY

Sebastian Schaub,
DVM Dr. med. vet.
DipECVDI

HOSPITAL NAME

Elizabeth AH

REFERRING VET

Dr. Sareena Enloe

INVOICE

13013

DATE

9/9/21