



**PATIENT**

Jake Lacy

**PRESENTING CLINICAL SIGNS**

1 week ago P fell off the porch that is 3 feet high. Since then P has been limping on the front right leg.

**SPECIES**

Canine

**RADIOGRAPHIC STUDY OF THE RIGHT SHOULDER AND ELBOW JOINT**

Radiographs of the right front limb in orthogonal imaging planes are provided for review.

**BREED**

Golden Retriever

**RADIOGRAPHIC FINDINGS**

The growth plates are age related open.

The right shoulder joint presents smooth osseous margins and the surrounding soft tissue structures are within normal limits.

**SEX**

Male

The osseous margins of the right elbow joint are smooth. The contour of the medial coronoid process of the right elbow joint is well-defined and has a homogeneous density with a well-delineated tip.

**AGE**

9 Months

**RADIOGRAPHIC DIAGNOSIS**

- Normal right shoulder joint
- Normal right elbow joint

**INTERPRETED BY**

Sebastian Schaub, DVM  
Dr. med. vet. DipECVDI

**INTERPRETATION OF THE FINDINGS & FURTHER RECOMMENDATIONS**

The radiographic study of the shoulder and elbow joint presents without abnormalities, explaining the right front limb lameness. Consider a clinical trial with rest and NSAID and reevaluating the patient in 2-3 weeks.

**HOSPITAL NAME**

All Creatures Animal  
Hospital of South Hill,  
Inc.

**REFERRING VET**

Dr. Hart

**INVOICE**

54039

**DATE**

9-8-22



**PATIENT**

Jake Lacy

**SPECIES**

Canine

**BREED**

Golden Retriever

**SEX**

Male

**AGE**

9 Months

**INTERPRETED BY**

Sebastian Schaub, DVM  
Dr. med. vet. DipECVDI

**HOSPITAL NAME**

All Creatures Animal  
Hospital of South Hill,  
Inc.

**REFERRING VET**

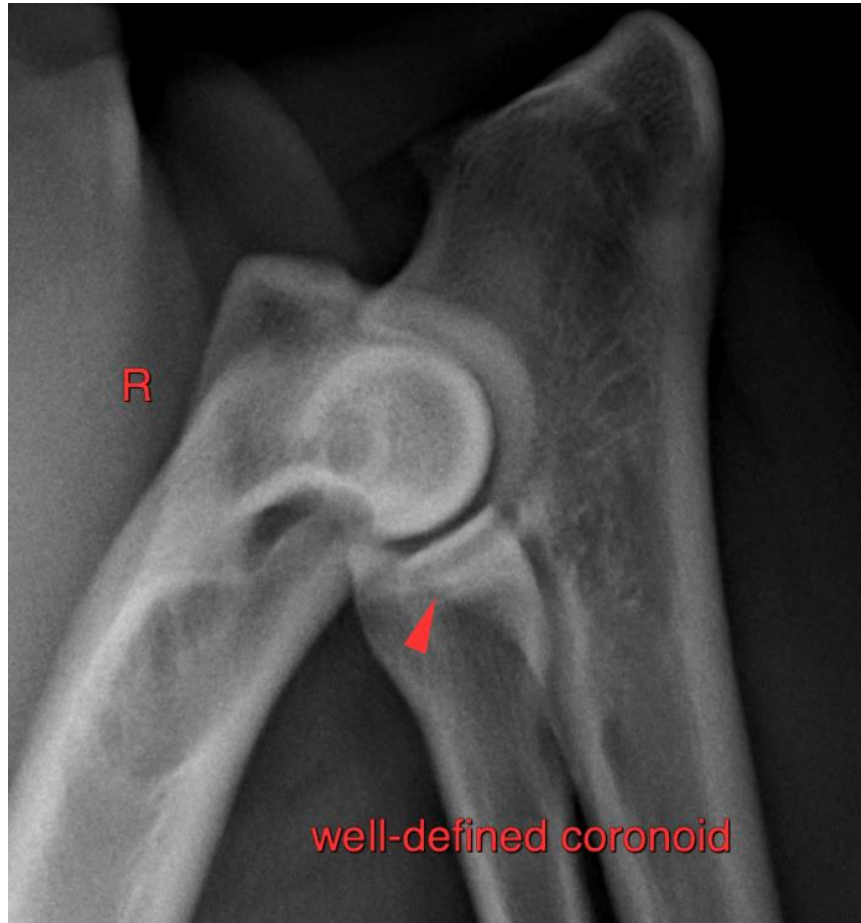
Dr. Hart

**INVOICE**

54039

**DATE**

9-8-22



The information and recommendations provided are based on the images presented by the referring veterinarian/sonographer. No evaluation can be communicated regarding pathology that was not visible in the image/video clips provided.

Thank you for this referral. If the clinical or image interpretation does not parallel your findings or if I can be of any further assistance please contact me.

**Sebastian Schaub**, Sebastian Schaub, DVM, Dr. med. vet. DipECVDI  
sebast.schaub@gmail.com