


PATIENT PRESENTING CLINICAL SIGNS

Zeva Sorenson

History: Patient presented to the clinic today due to accidentally trying to jump out of a truck and getting her leg stuck in a pocket of the truck, dragging it across the truck bed after pulling it out of the hole and skidding it across the ground. Patient was NWB on right front foot. NON-WEIGHTBEARING RIGHT FORELIMB LAMENESS; DEEP PAIN STILL PRESENT, SLIGHT SWELLING OVER THE METACARPUS WOUND AREA. No loss of proprioception. FULL THICKNESS LACERATION/DEGLOVING OF A SECTION OF THE RIGHT METACARPUS WITH SWELLING AND SLIGHT OOZING.

SPECIES

Canine

BREED

Abnormal PE/Chem/CBC/UA Results:

 German Shorthair
 Pointer

RADIOGRAPHIC STUDY OF THE RIGHT FRONT PAW

Radiographs of the right front paw in two orthogonal imaging planes are provided for review.

SEX

Spayed Female

RADIOGRAPHIC FINDINGS

A moderate soft tissue swelling is present along the axial aspect of the second phalanx and dorsal aspect of the right front paw with a defect level with the mid third of the diaphysis of the metacarpal bones.

AGE

8 Years 8 Months

In the mediolateral projection mild smooth solid periosteal new bone formation is noted along the dorsal aspect of one metacarpal bone

RADIOGRAPHIC DIAGNOSIS

- History of traumatic laceration right front paw
- Secondary soft tissue swelling
- Monostotic benign osteoproliferative lesion one metacarpal bone

INTERPRETED BY

 Sebastian Schaub,
 DVM Dr. med. vet.
 DipECVDI

INTERPRETATION OF THE FINDINGS & FURTHER RECOMMENDATIONS

The soft tissue swelling with evidence of a defect is a sequela to the given traumatic history. There is no evidence of fracture, neither of the metacarpal bones nor the phalanges. The mild periosteal new bone formation can be secondary to subperiosteal hematoma/traumatic insult or local inflammatory reaction.

HOSPITAL NAME

Elizabeth AH

REFERRING VET

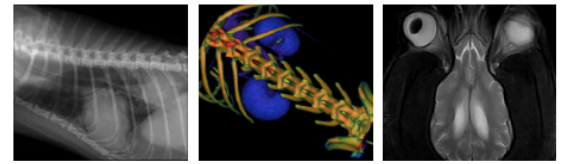
Sareena Enloe, DVM

INVOICE

12998

DATE

9/8/21



PATIENT

Zeva Sorenson

SPECIES

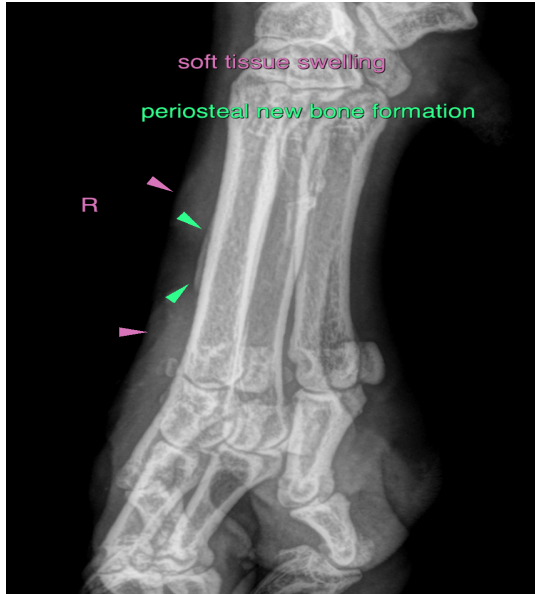
Canine

BREED

German Shorthair
Pointer

SEX

Spayed Female



AGE

8 Years 8 Months

The information and recommendations provided are based on the images presented by the referring veterinarian. No evaluation can be communicated regarding pathology that was not visible in the image/video clips provided.

Thank you for this referral. If the clinical or image interpretation does not parallel your findings or if I can be of any further assistance please contact me.

INTERPRETED BY

Sebastian Schaub,
DVM Dr. med. vet.
DipECVDI

Sebastian Schaub, Sebastian Schaub, DVM, Dr. med. vet. DipECVDI
sebast.schaub@gmail.com

HOSPITAL NAME

Elizabeth AH

REFERRING VET

Sareena Enloe, DVM

INVOICE

12998

DATE

9/8/21