


**PATIENT PRESENTING CLINICAL SIGNS**

Winston Jolly History: P presents for hyper salivation and declining mobility - Yesterday got very wobbly mainly back L is shakey - Meds and rest helped but now mobility is declining over last couple of days - Sometimes slips

**SPECIES**

Canine

Abnormal PE/Chem/CBC/UA Results: Abscent CP's bilateral hind legs, decreased posturals rear legs, non reactive on flexion/extension of hips

**RADIOGRAPHIC STUDY OF THE THORACIC AND LUMBAR SPINE**
**BREED**

Boston Terrier

Radiographs of the thoroacic and lumbar spine in two imaging planes are provided for review.

**RADIOGRAPHIC FINDINGS**
**SEX**

Neutered Male

T8 and T9 present a mild wedge shaped conformation.

The intervertebral disc space L1/L2 is mildly narrowed.

The vertebral endplates L2/L3 present mild spondylosis formation.

**AGE**

13 Years

No additional abnormalities of the thoracic and lumbar spine are appreciated.

**RADIOGRAPHIC DIAGNOSIS**
**INTERPRETED BY**

Sebastian Schaub,  
 DVM Dr. med. vet.  
 DipECVDI

- Possible discopathy L1/L2
- Hemivertebra T8 & T9
- Spondylosis deformans

**INTERPRETATION OF THE FINDINGS & FURTHER RECOMMENDATIONS**

The narrowed intervertebral disc space L1/L2 is concerning for discopathy ± compressive myelopathy. If the neurological status of the patient is declining, consider cross-sectional imaging to check for compressive myelopathy.

**HOSPITAL NAME**

Boca Park AH

**REFERRING VET**

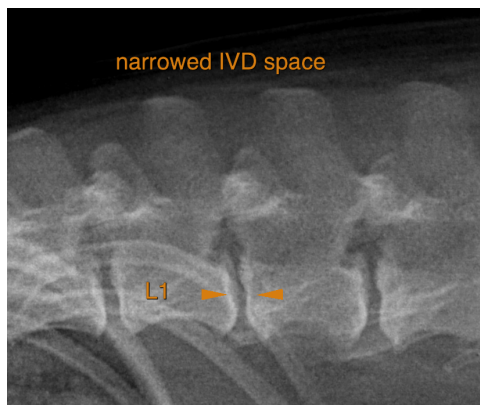
Dr. Ensign

**INVOICE**

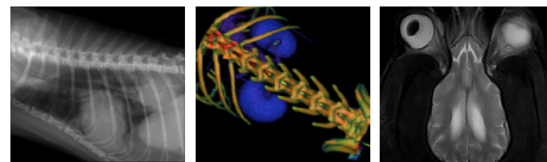
13002

**DATE**

9/8/21



The information and recommendations provided are based on the images presented by the referring veterinarian. No evaluation can be communicated regarding pathology that was not



**PATIENT** visible in the image/video clips provided.

Winston Jolly Thank you for this referral. If the clinical or image interpretation does not parallel your findings or if I can be of any further assistance please contact me.

**SPECIES** Sebastian Schaub, Sebastian Schaub, DVM, Dr. med. vet. DipECVDI  
sebast.schaub@gmail.com

Canine

**BREED**

Boston Terrier

**SEX**

Neutered Male

**AGE**

13 Years

**INTERPRETED BY**

Sebastian Schaub,  
DVM Dr. med. vet.  
DipECVDI

**HOSPITAL NAME**

Boca Park AH

**REFERRING VET**

Dr. Ensign

**INVOICE**

13002

**DATE**

9/8/21